

Module I. Fundamentals of brain structure

- Introduction to brain mapping

Module II. Neural activity visualization

- Optical imaging of neural structure and physiology
- Voltage and calcium imaging of brain activity
- Optical imaging based on intrinsic signals

Module III. Brain function and blood flow

- Dynamic measurements of local cerebral blood flow

Module IV. Electrophysiological techniques

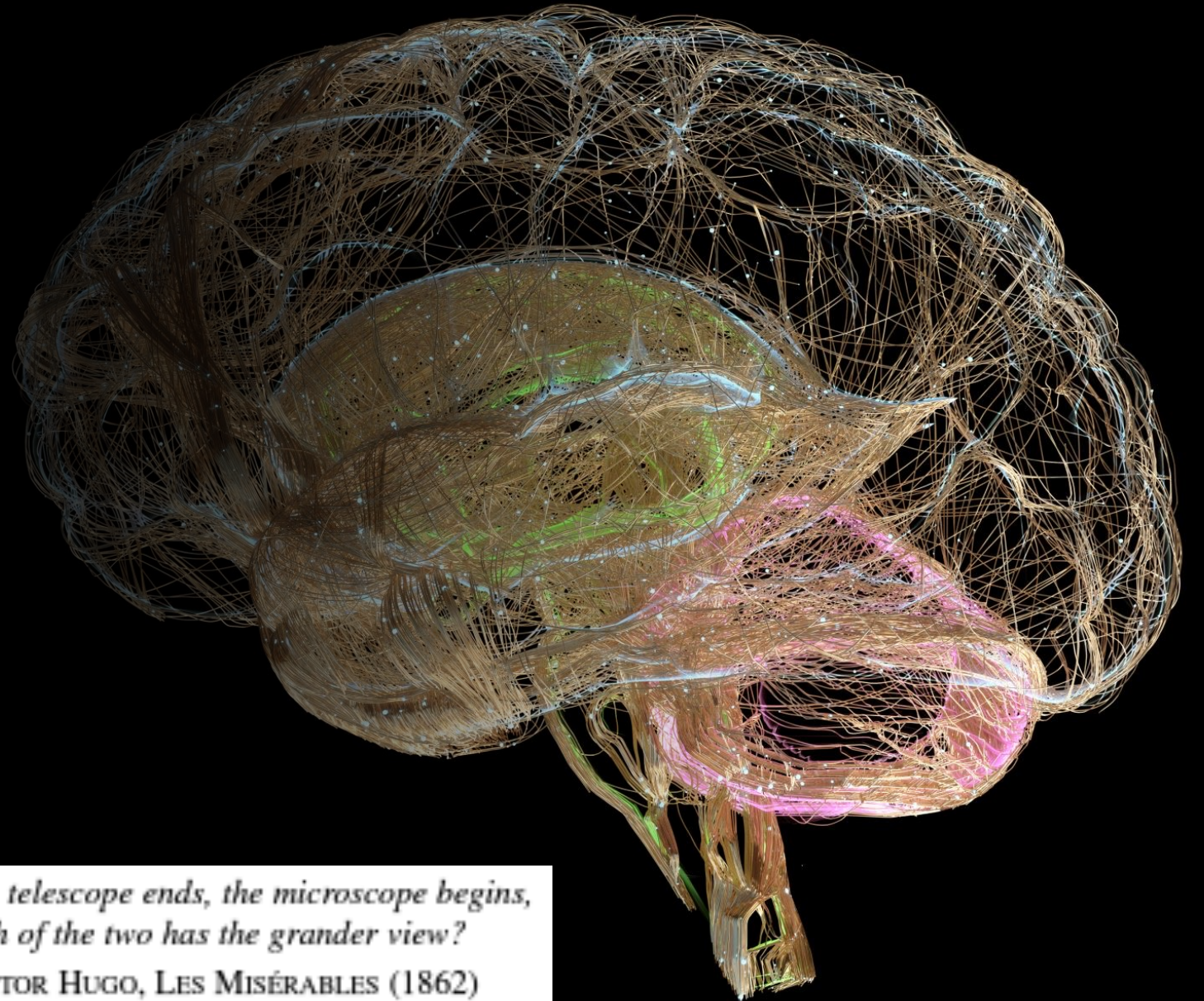
- Electrophysiological imaging of brain function
- Epilepsy – neural engineering applications and innovations

Module V. Modulation of neural activity

- Deep brain stimulation
- Transcranial magnetic stimulation
- Animal models of human neurological disorders





Introduction to brain mapping




*Where the telescope ends, the microscope begins,
which of the two has the grander view?*
—VICTOR HUGO, LES MISÉRABLES (1862)



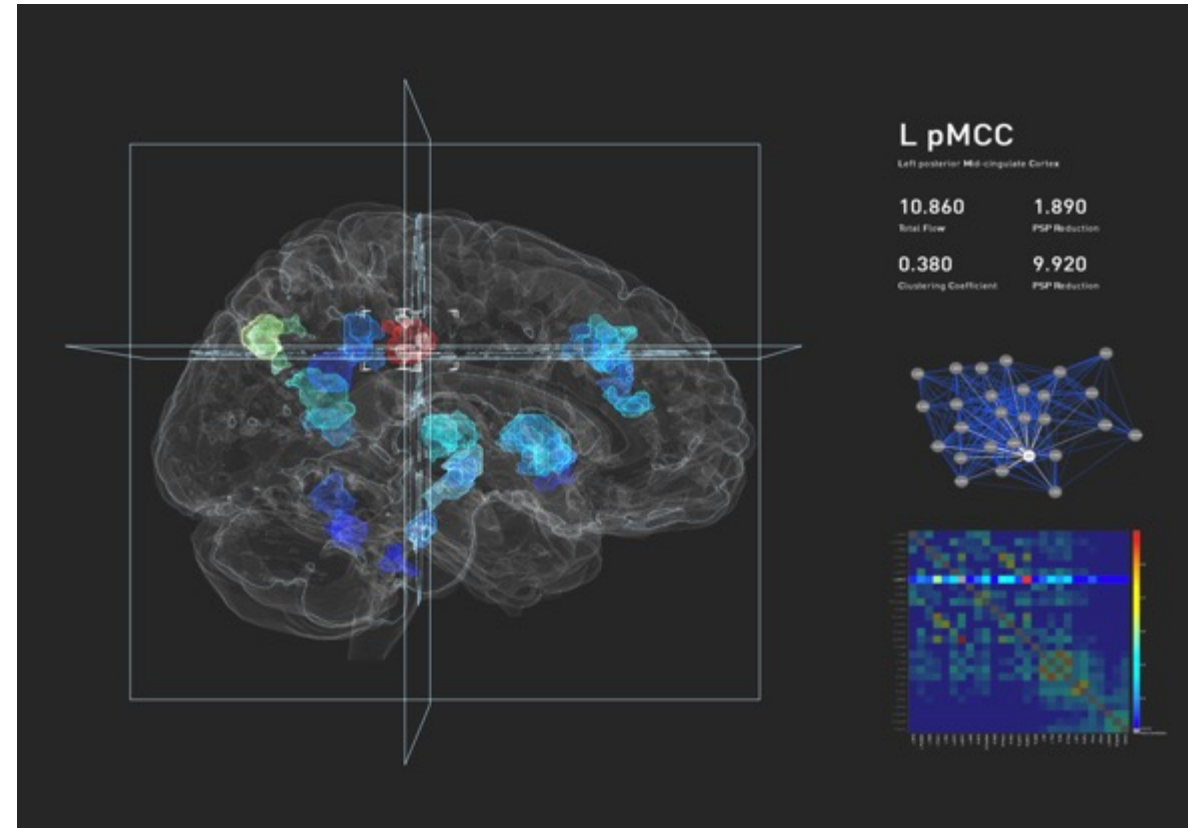
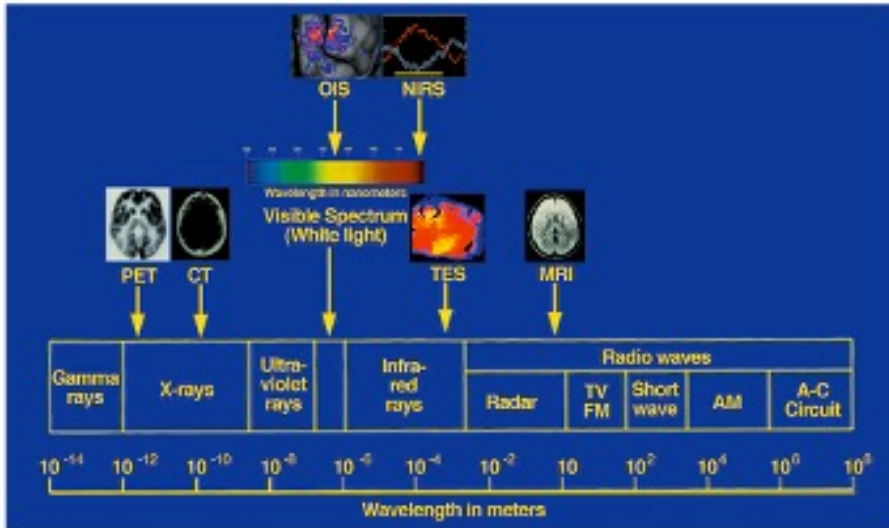
Hipparchus



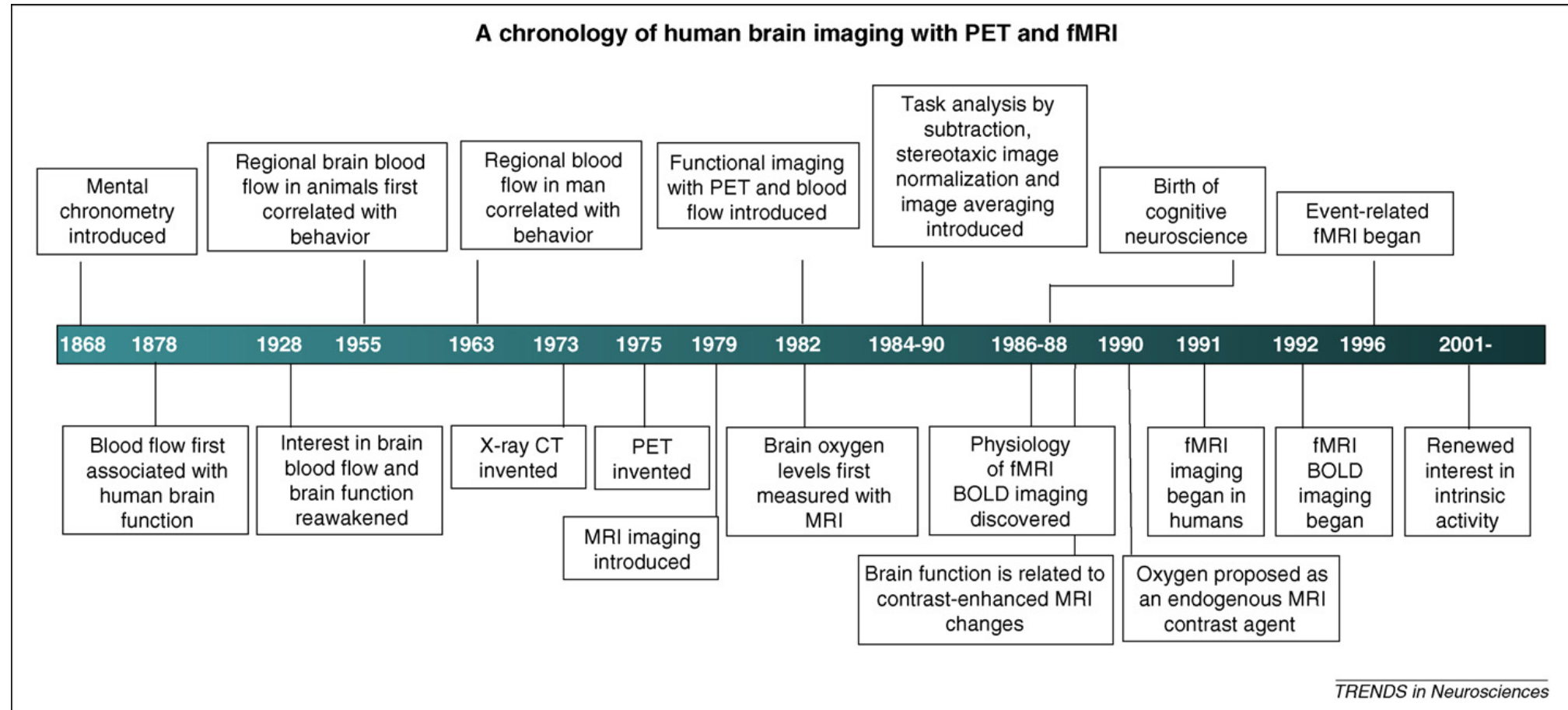
Ptolemy



Technological advancements



The dawn of human functional brain mapping: a 30-year journey



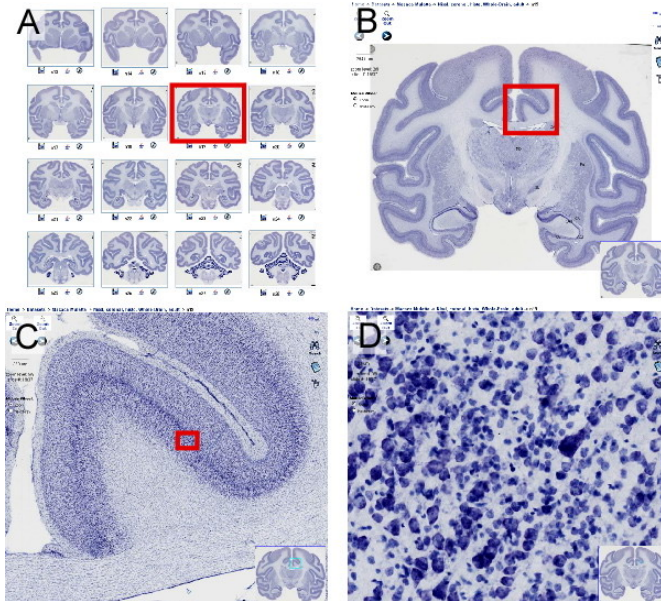
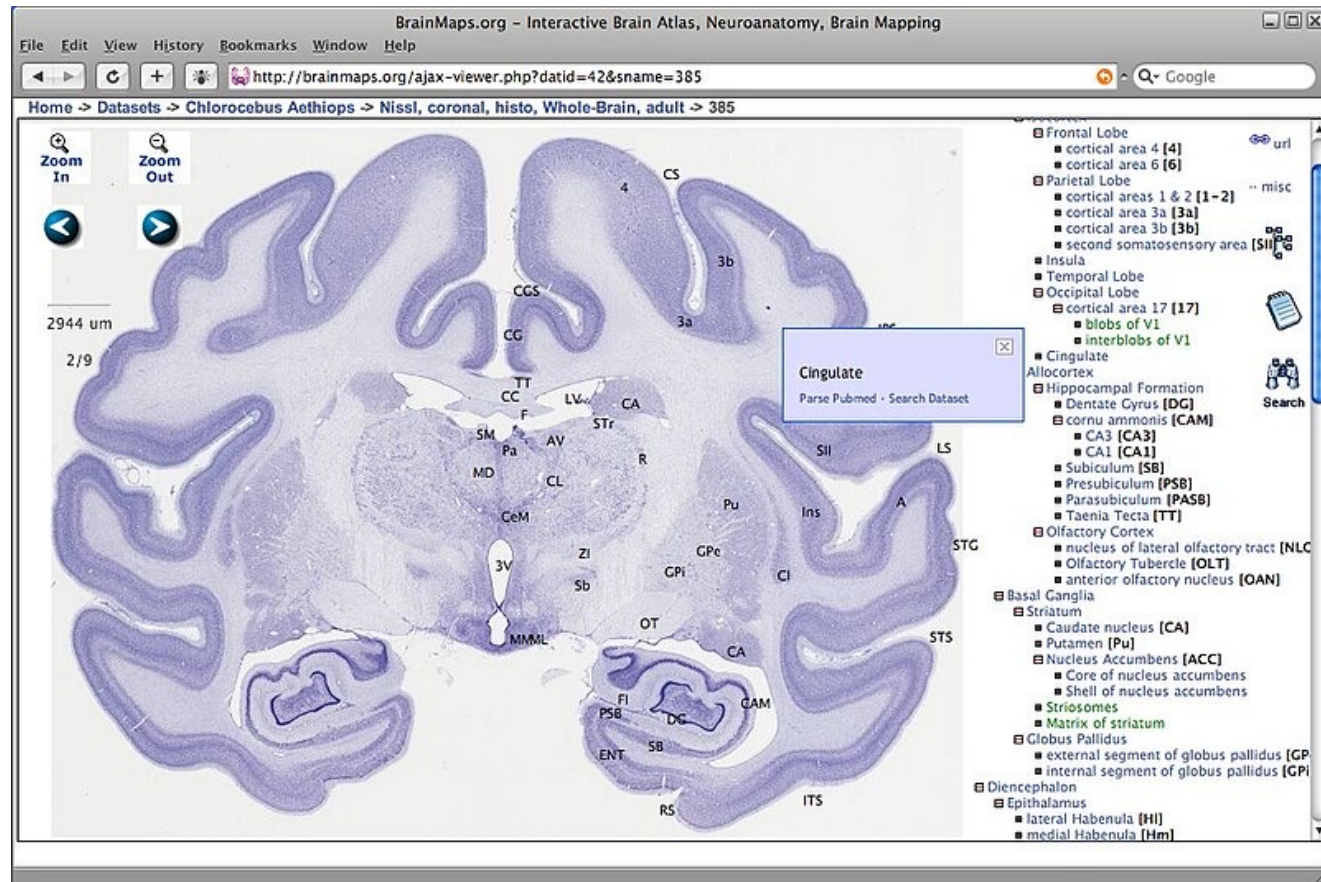
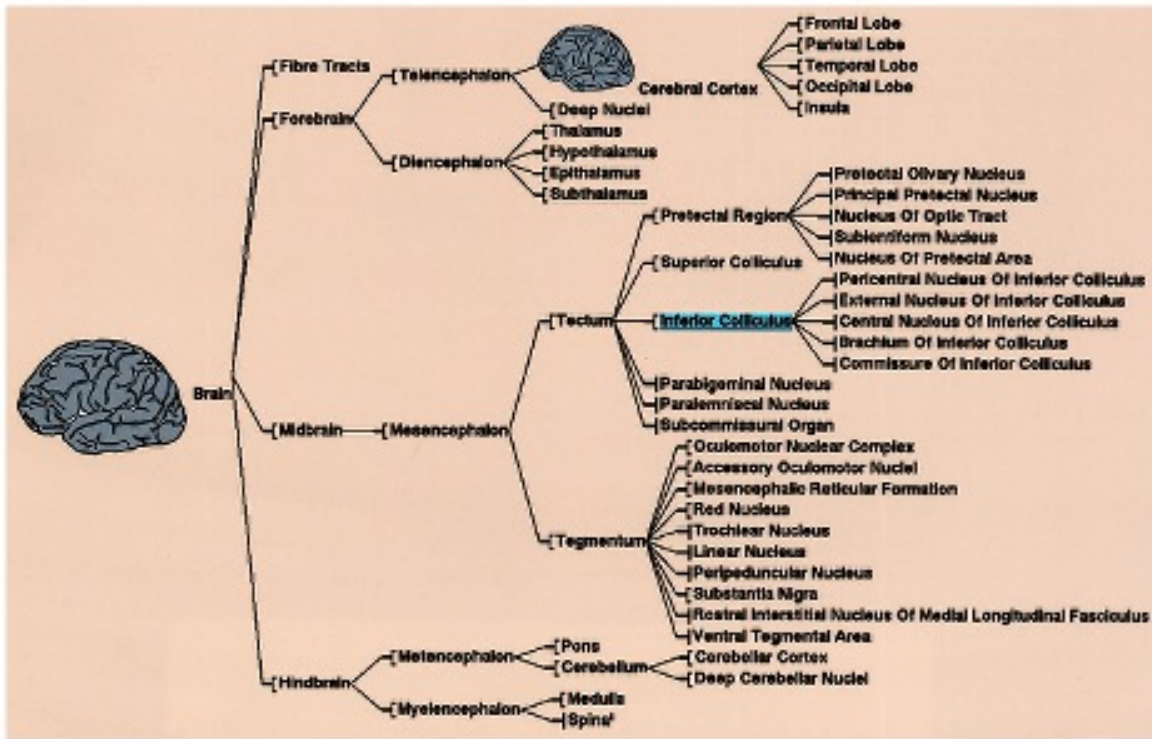
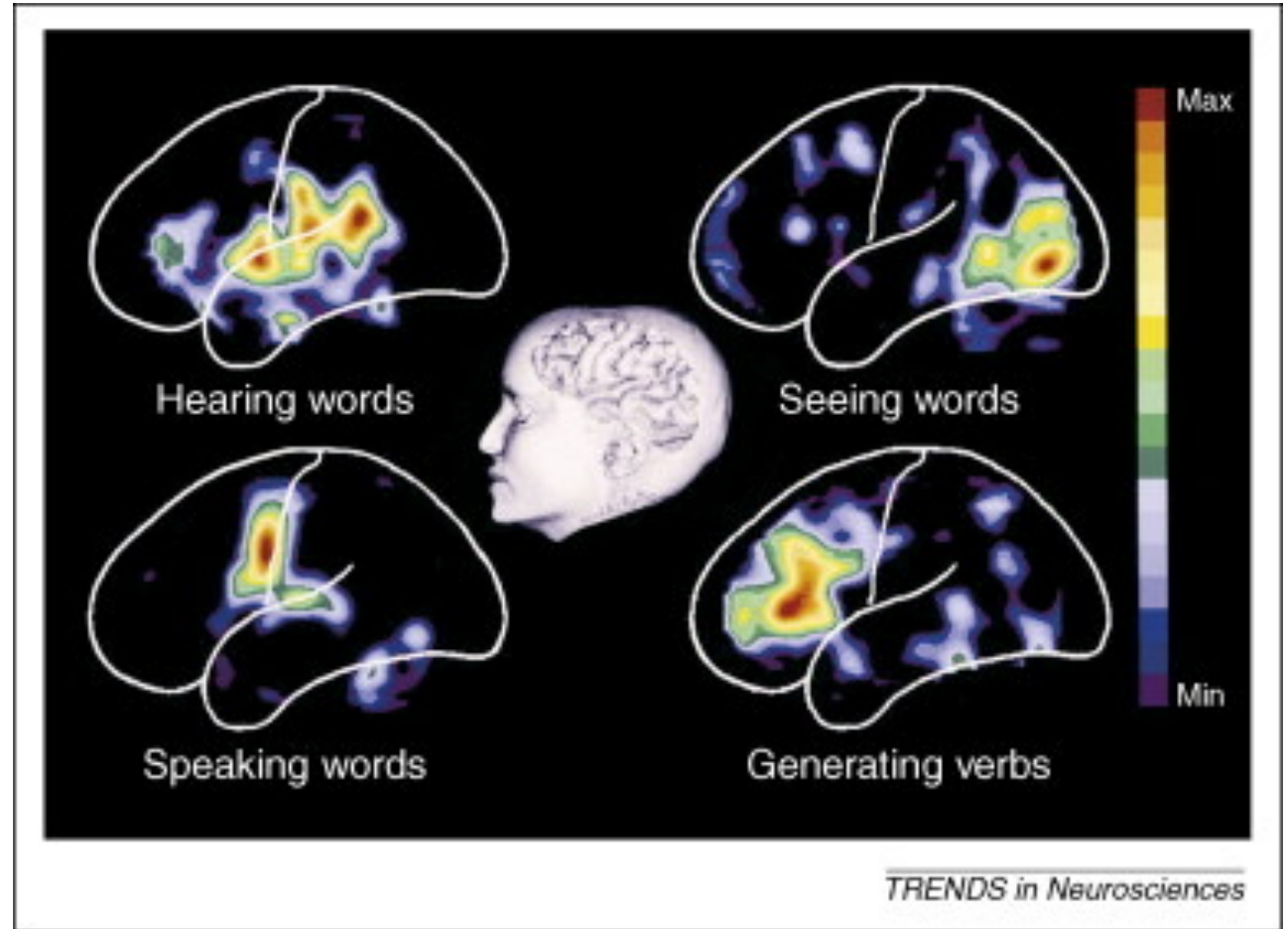
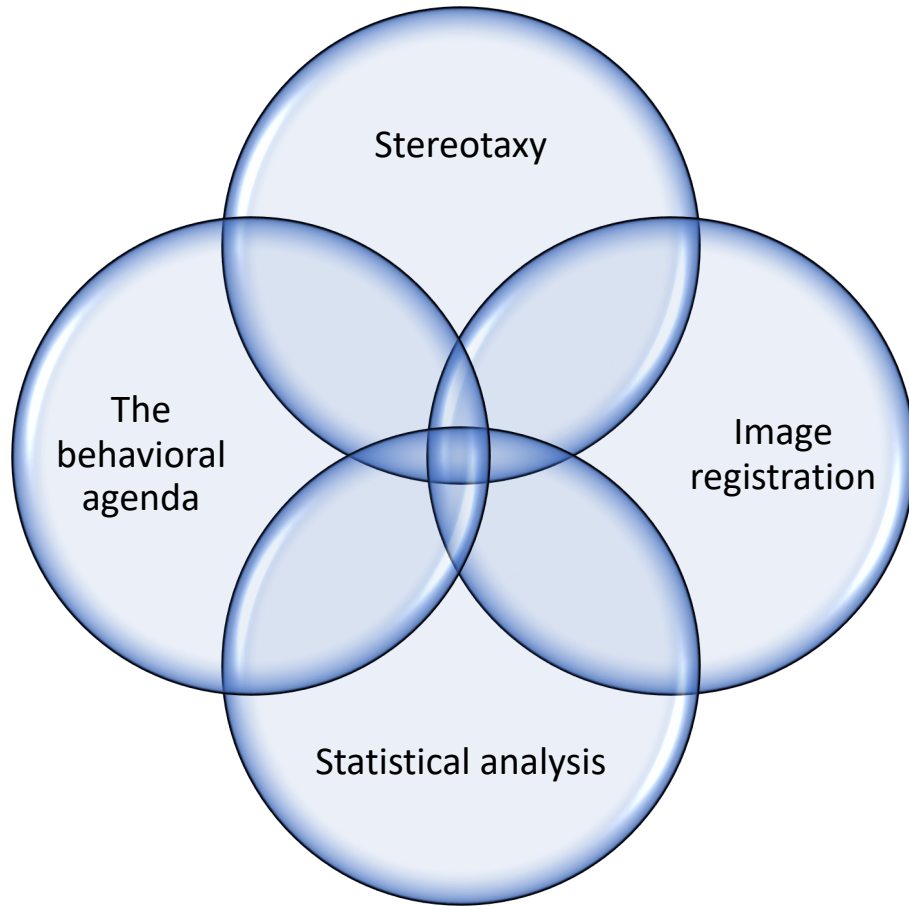


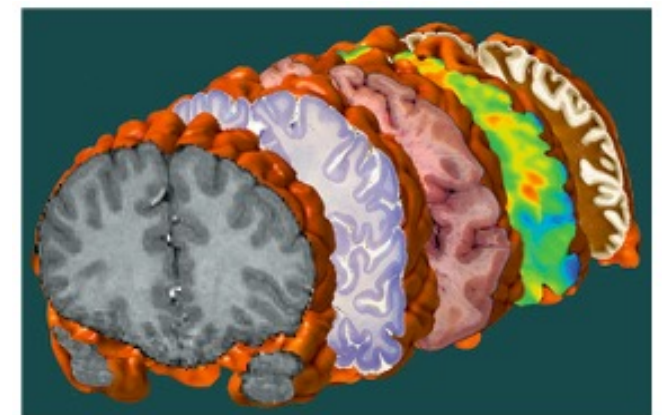
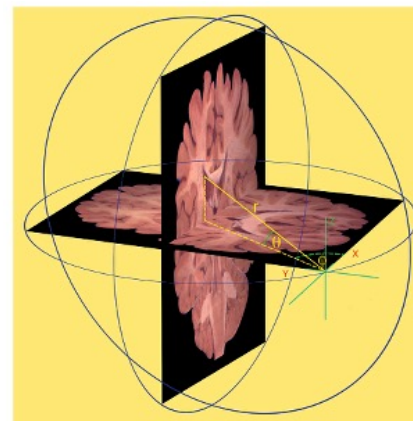
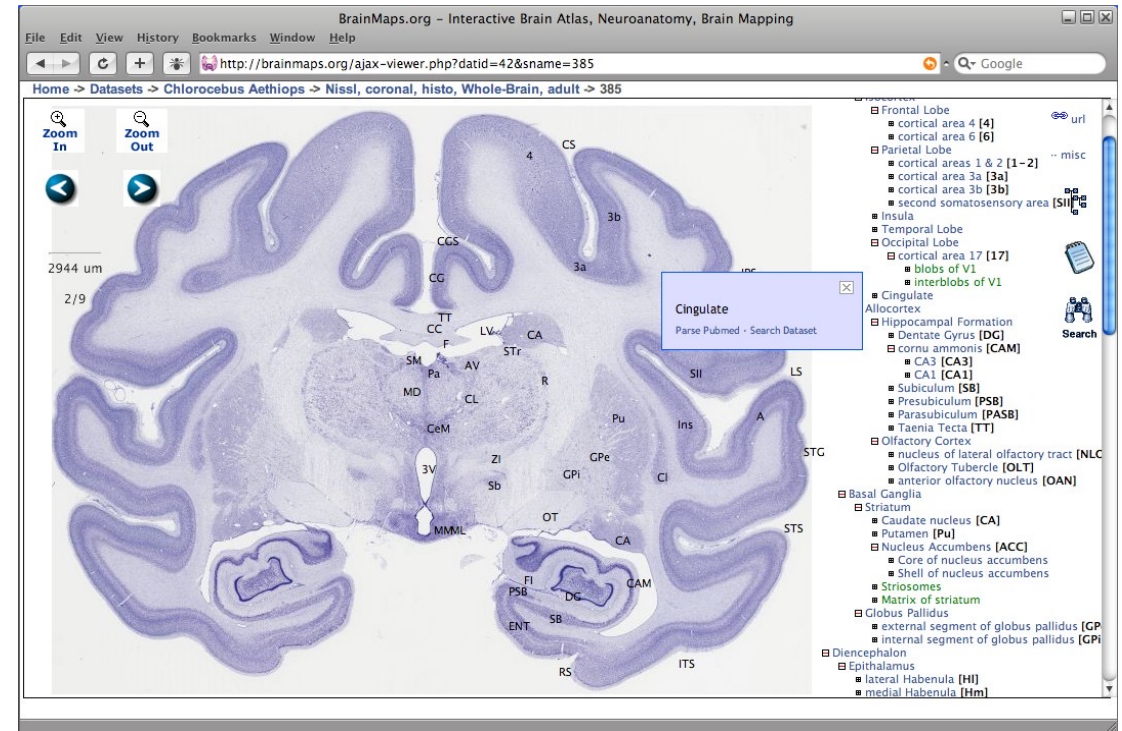
Image processing



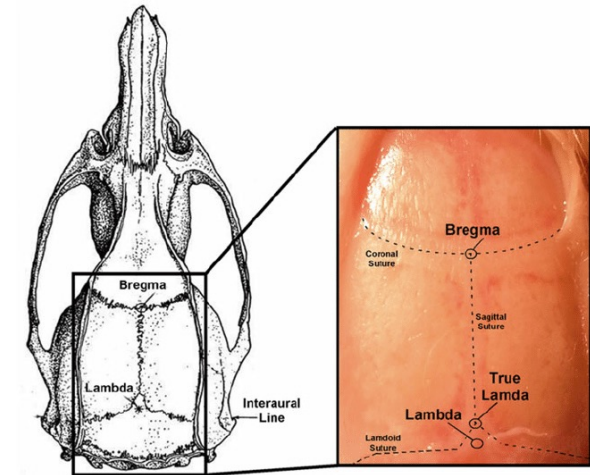
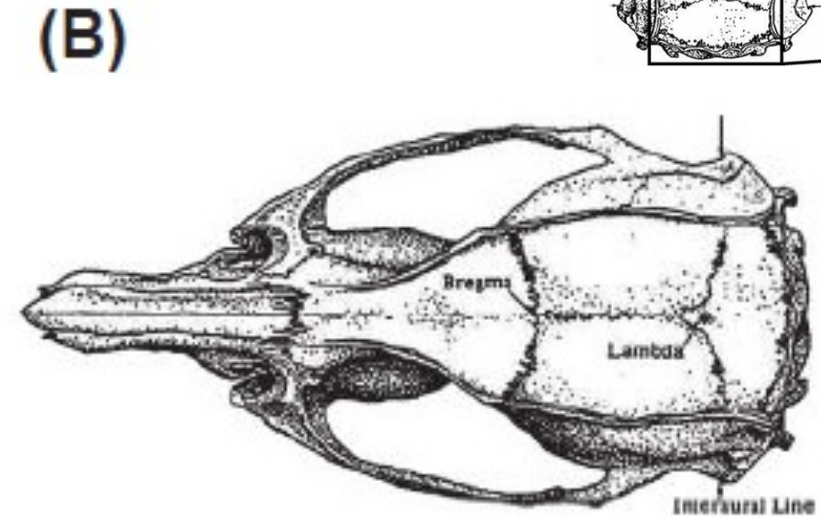
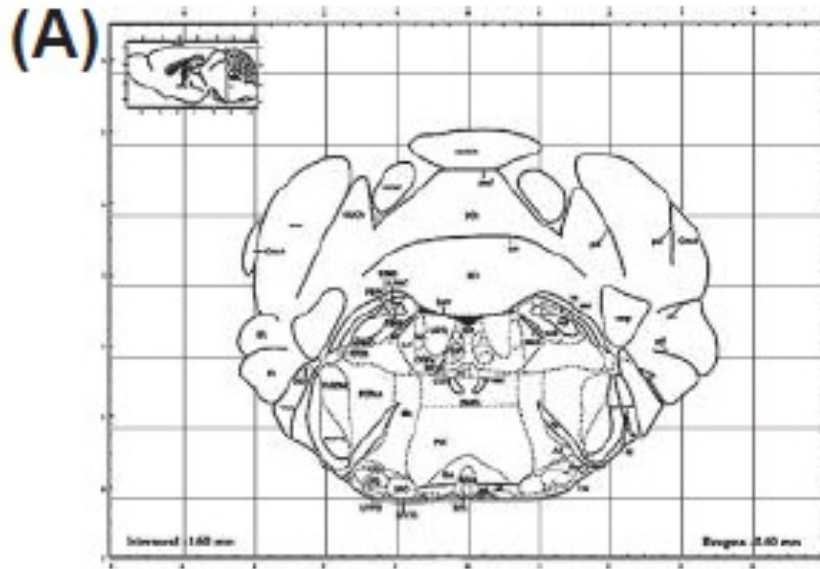
Stereotaxy

Anatomy maps display structure boundaries and are detailed with images or digital outlines.

Functional maps represent the brain's dynamic activities and how different regions are activated during cognitive tasks or in various states of consciousness



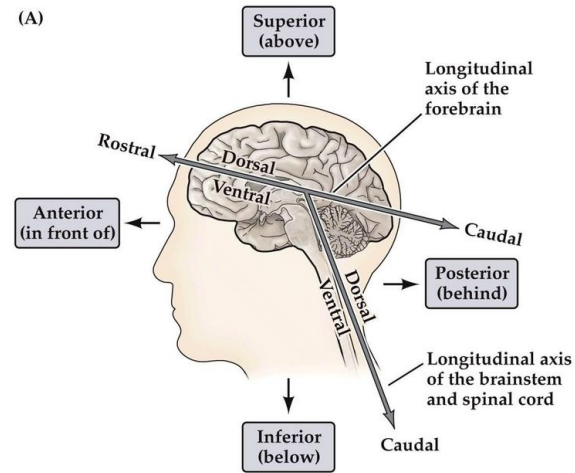
Anatomical landmarks



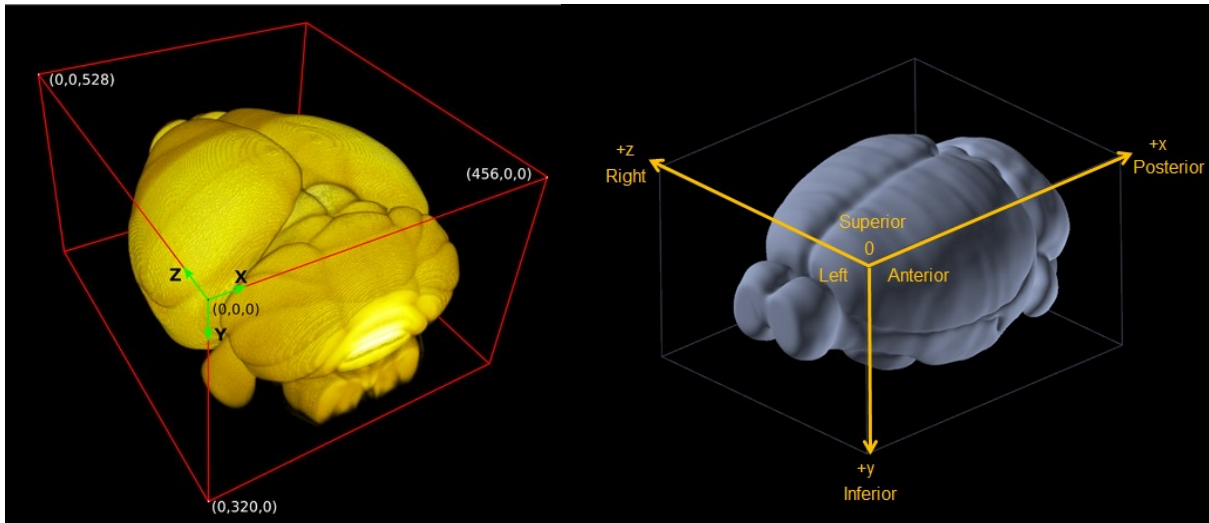
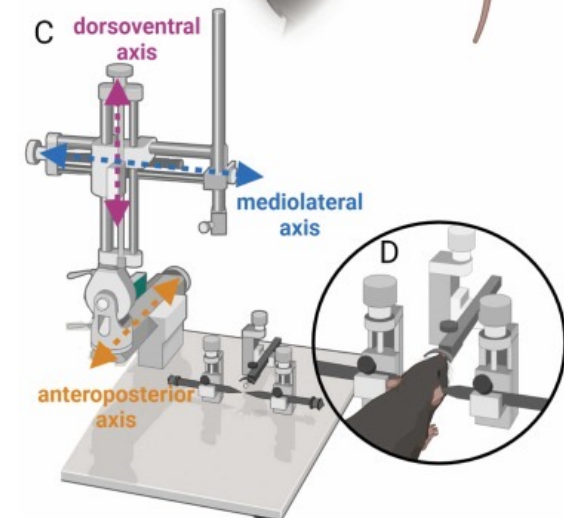
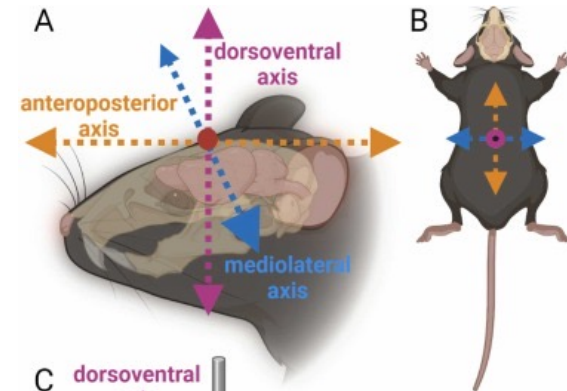

Bregma is defined as the intersection between the sagittal and coronal sutures of the skull; **lambda** is defined as the intersection between the lines of best fit through the sagittal and lambdoid sutures

A rodent stereotaxic instrument

This equipment is used to precisely hold an animal's head in place and target specific brain structures according to three-dimensional coordinates.



NEUROSCIENCE 5e, Figure A1 (Part 1)
© 2012 Sinauer Associates, Inc.



Brain function and behavior

- Lobes of the brain
 - Brain stem
 - Cerebellum
 - Functional areas: motor, sensory, language and comprehension, association
 - Behavioral functions: emotion, memory, eye movement, smell
 - Interconnectedness
-

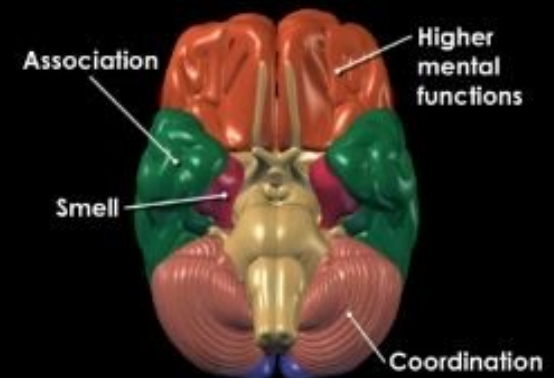
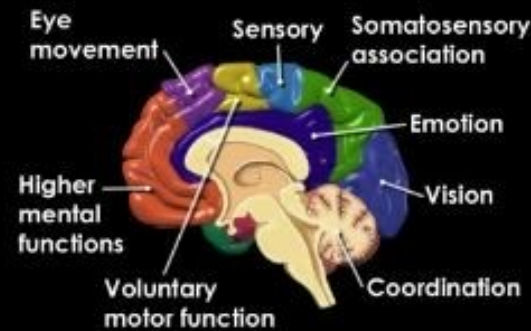
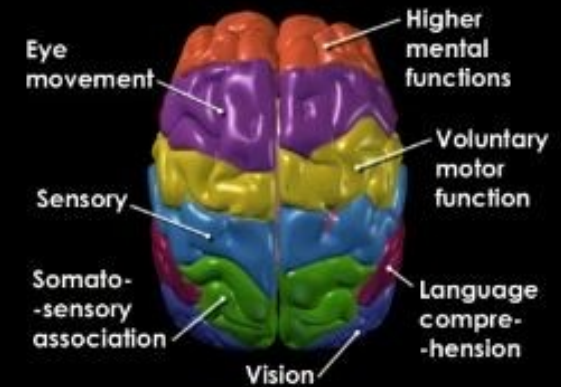
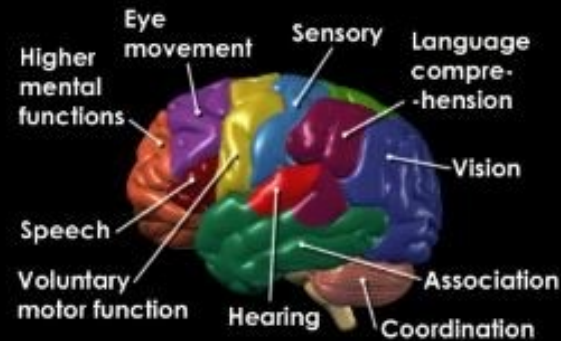
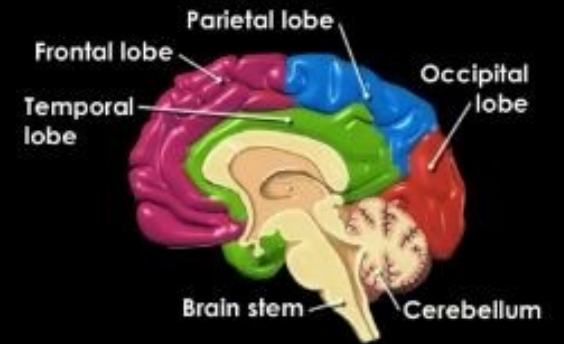
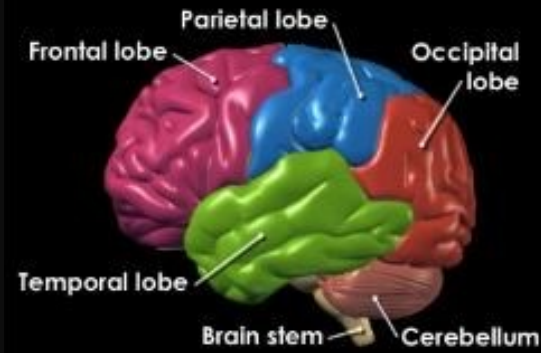
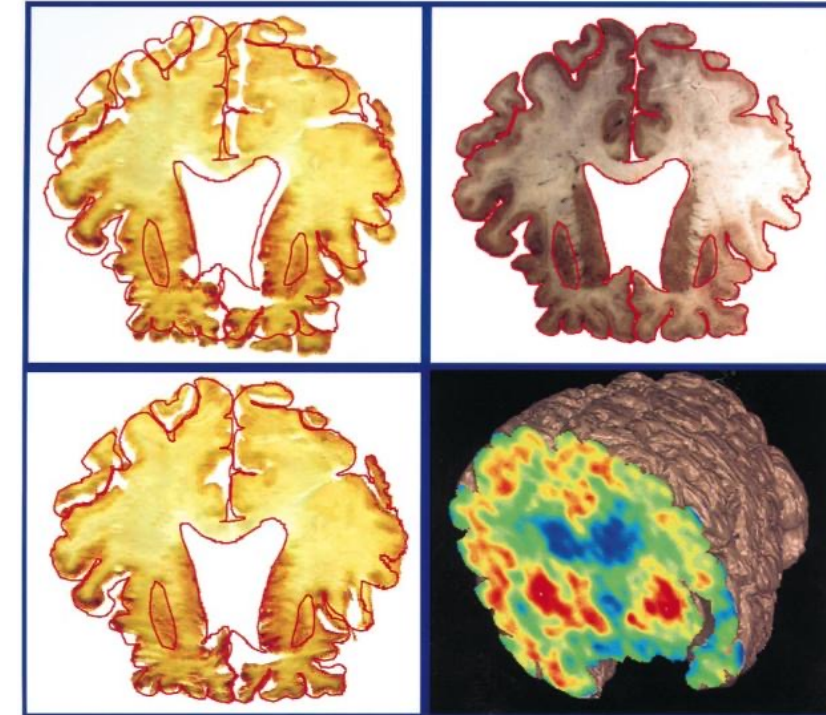
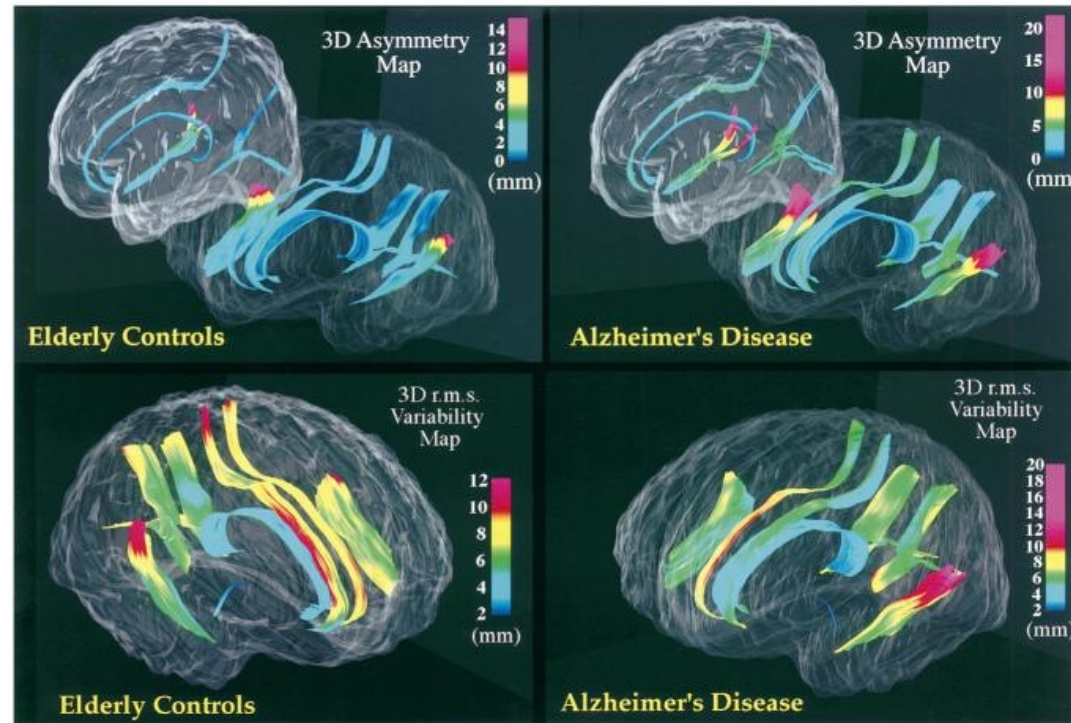
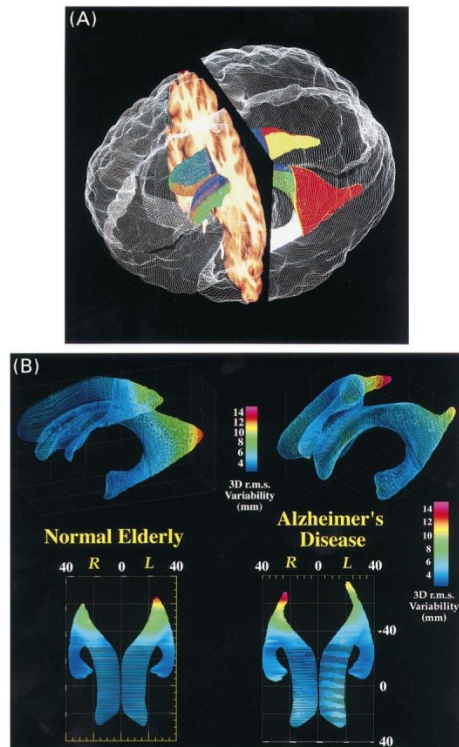


Image registration

Toga & Thompson, Image Vis Comput 2001



Population-based maps of ventricular anatomy in normal aging and Alzheimer's disease

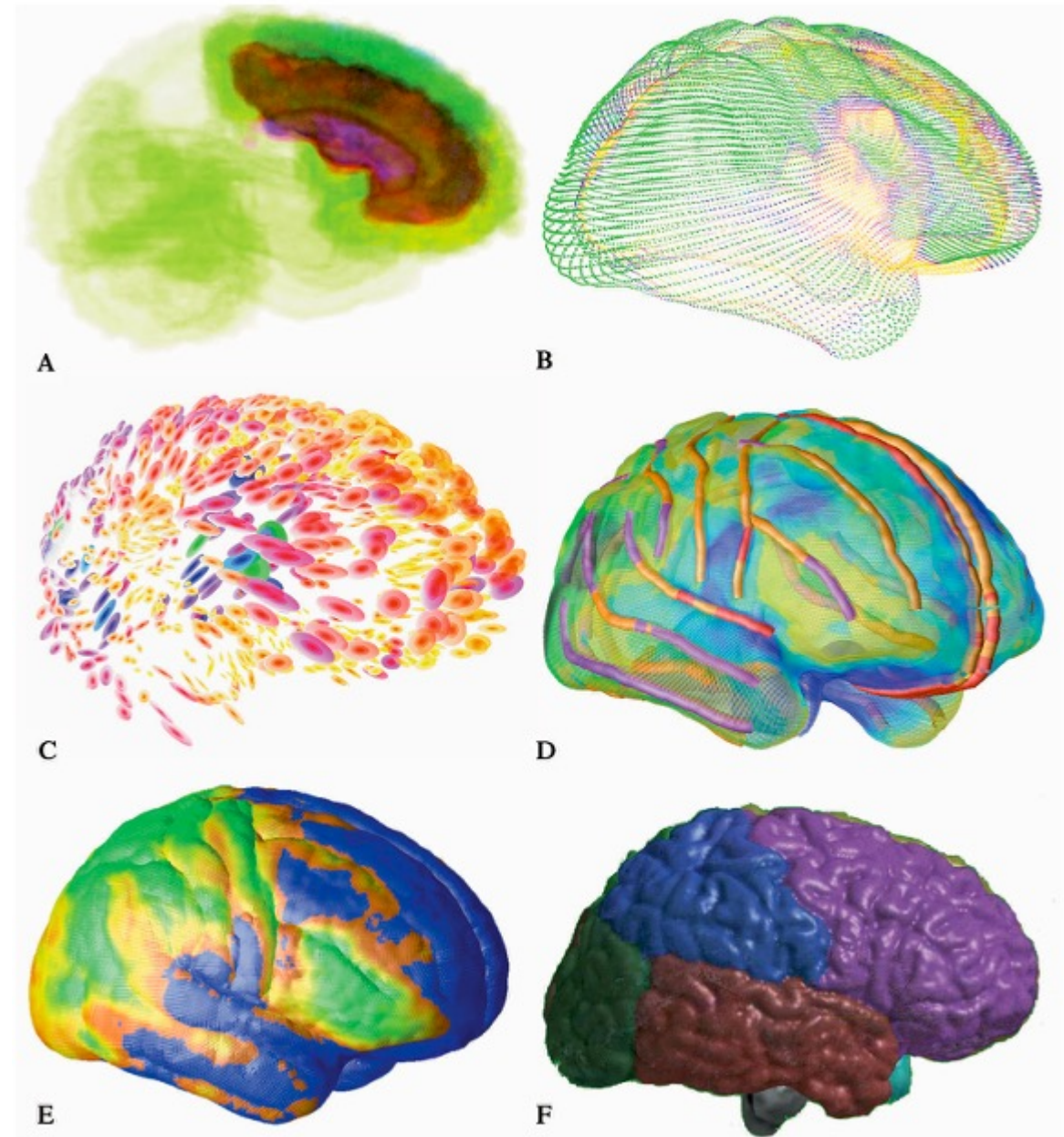
Population-based maps of 3D structural variation and asymmetry

Warping algorithms integrate multi-modality brain data

- **Averaging** - used to consolidate multiple brain images into a single, composite image that represents the average anatomy of a population
- **Subtraction** - used to highlight changes between two sets of images
- **Correlation** - the statistical analysis of the relationship between different sets of imaging data
- **Warping** - a process in brain imaging that involves the non-linear registration of brain images to a standard space or to each other

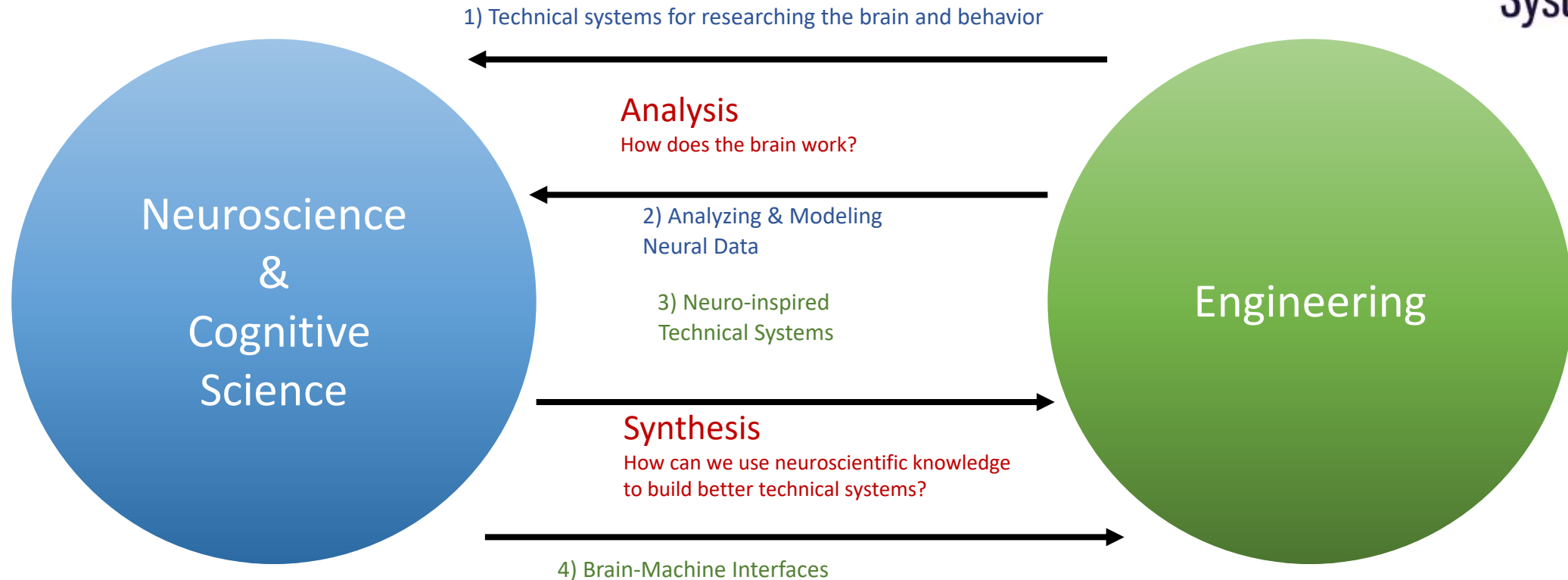
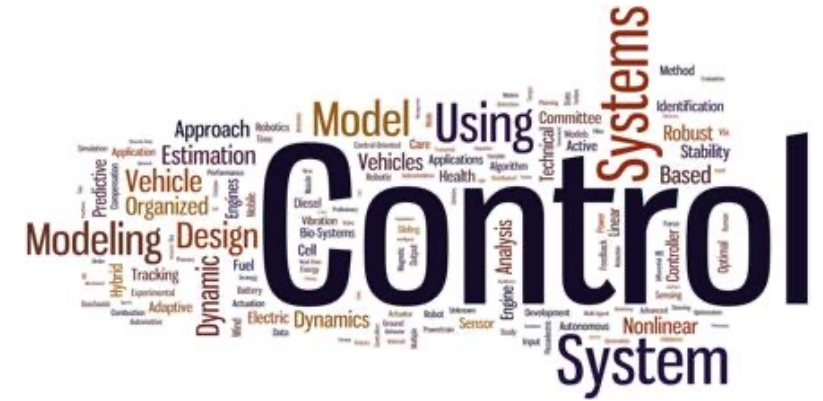Statistical maps

- Statistical Maps:** Utilize collections of datasets transformed to a shared coordinate space to characterize subpopulations, with the probability map reflecting tissue type confidence across regions.
- Average Cortical Models:** Generated from MRI data, represent common brain surface anatomy among subjects, with color-coded areas indicating the variability of the cortical structure.
- Tensor Maps:** Depict anatomical variation in the cortex, where colors and ellipsoidal glyphs represent the variability and principal directions of anatomical difference across a population.
- Sulcal Variability Maps:** Average cortical surfaces mapped with major sulci, showing anatomical variability through a color index based on displacement vectors from individual to average models.
- Developmental Variations:** Highlight the anatomic variation in cortical anatomy during child development, showing changes in tissue types and brain volumes.
- Cerebral Lobe Subparcellation:** Demonstrates the segmentation of cerebral hemispheres into lobes, aiding in the analysis of regional developmental effects on brain structure.



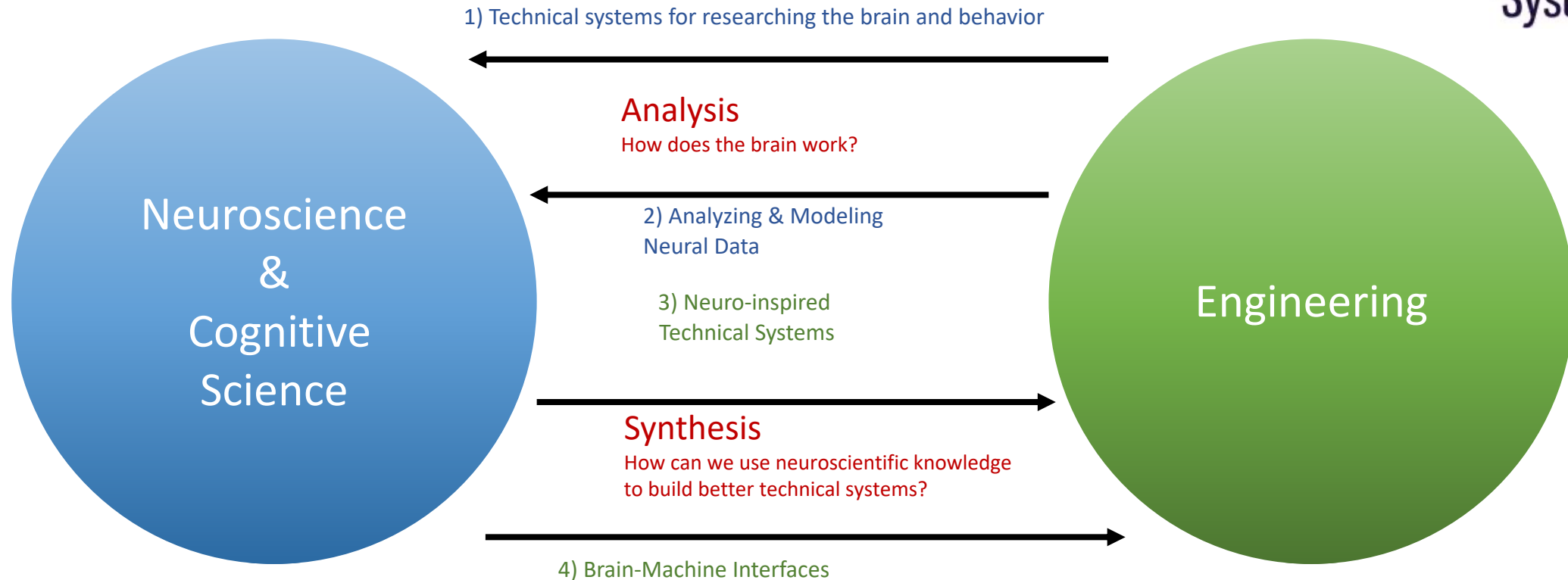
Systems neuroengineering

the use of engineering tools and technologies to image, decode, and modulate the brain in order to comprehend its functions and to repair its dysfunction.

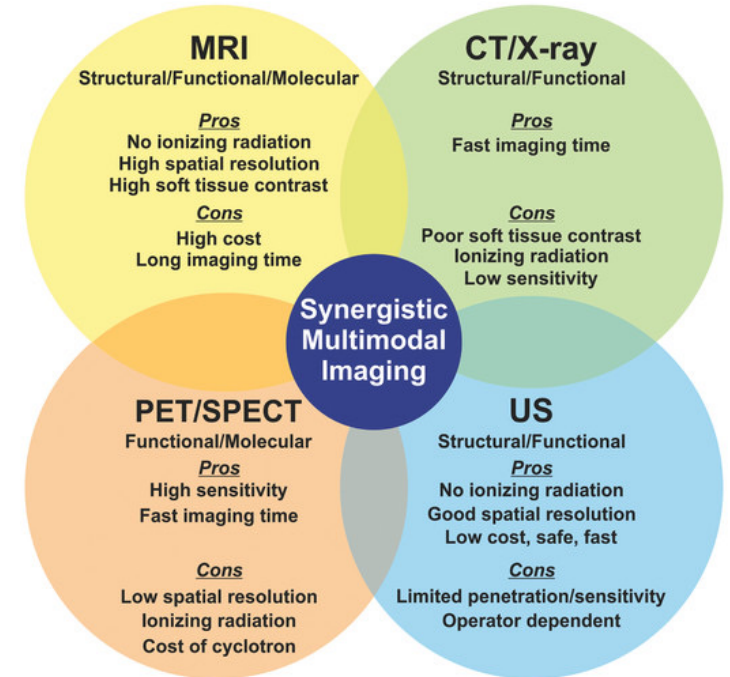
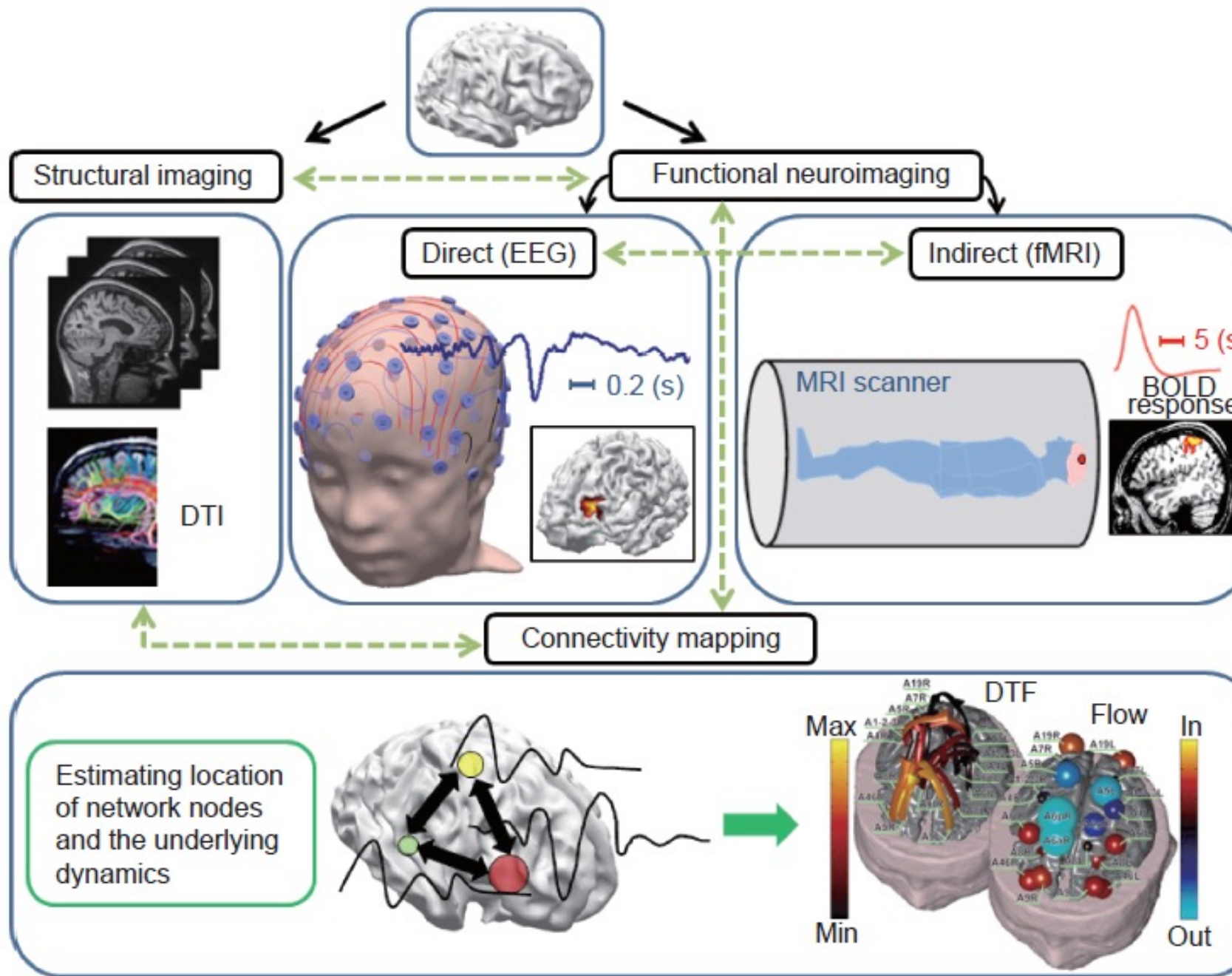


Systems neuroengineering

the use of engineering tools and technologies to image, decode, and modulate the brain in order to comprehend its functions and to repair its dysfunction.



Neuroimaging modalities

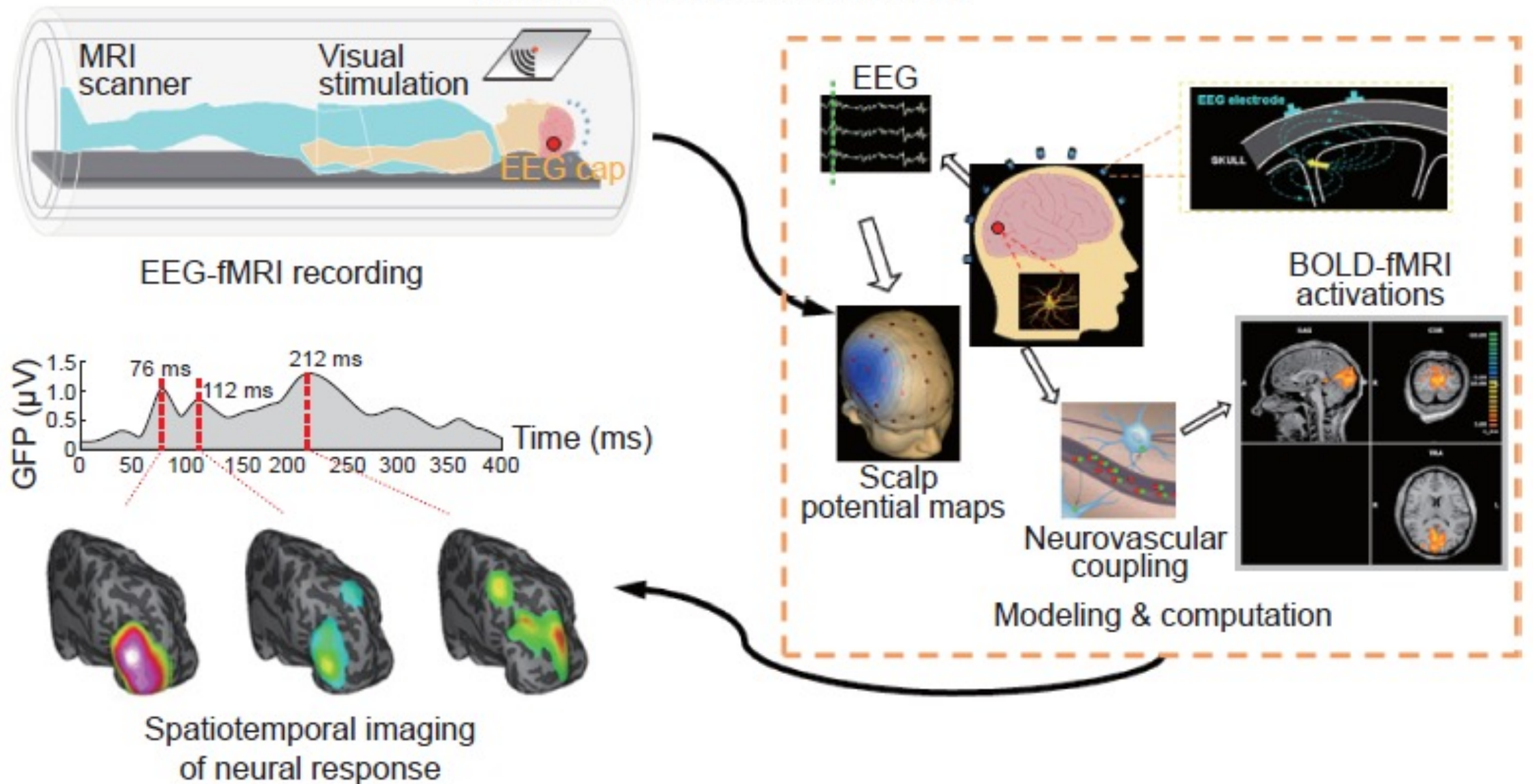


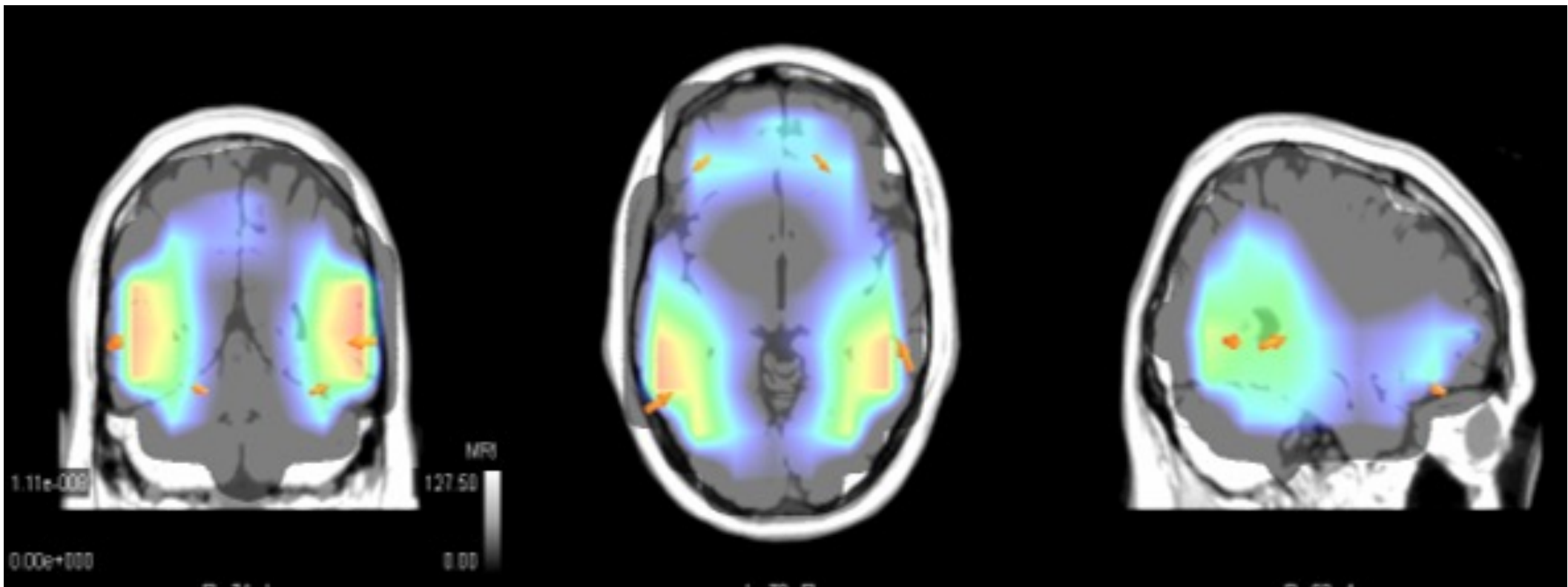
Edelman et al., 2015 J. Engineering, Review
 Rieffel et al., 2015, Small, Review

Neuroimaging

- 1. Magnetic Resonance Imaging (MRI):** MRI is a non-invasive technique that uses magnetic fields and radio waves to produce detailed images of the brain and other tissues. It can be used to study brain structure and function, and to diagnose various neurological and psychiatric conditions.
- 2. Computed Tomography (CT):** CT is a non-invasive imaging technique that uses X-rays and computer processing to produce detailed images of the brain and other tissues. It is commonly used to diagnose conditions such as head injuries, brain tumors, and other neurological conditions.
- 3. Positron Emission Tomography (PET):** PET is a non-invasive imaging technique that uses a small amount of radioactive material and a special camera to produce images of the brain and other tissues. It can be used to study brain function, such as measuring glucose metabolism and neurotransmitter activity.
- 4. Electroencephalography (EEG):** EEG is a non-invasive technique that measures the electrical activity of the brain using electrodes placed on the scalp. It is commonly used to diagnose conditions such as epilepsy, sleep disorders, and other neurological conditions.
- 5. Magnetoencephalography (MEG):** MEG is a non-invasive imaging technique that uses magnetic fields to measure the electrical activity of the brain. It is often used in combination with other imaging techniques to provide detailed information about brain activity and function.

Multimodal functional neuroimaging





Temporal and spatial resolution and what it means for users

- **Spatial resolution** - capacity a technique has to tell you exactly which area of the brain is active
- **Temporal resolution** describes its ability to tell you exactly when the activation happened.

Neural interface technologies

- Decoding the neural activity
- Record neural activity with high temporal resolution
- Multi-scale recording
- Invasive or non-invasive

Brain-computer interface system

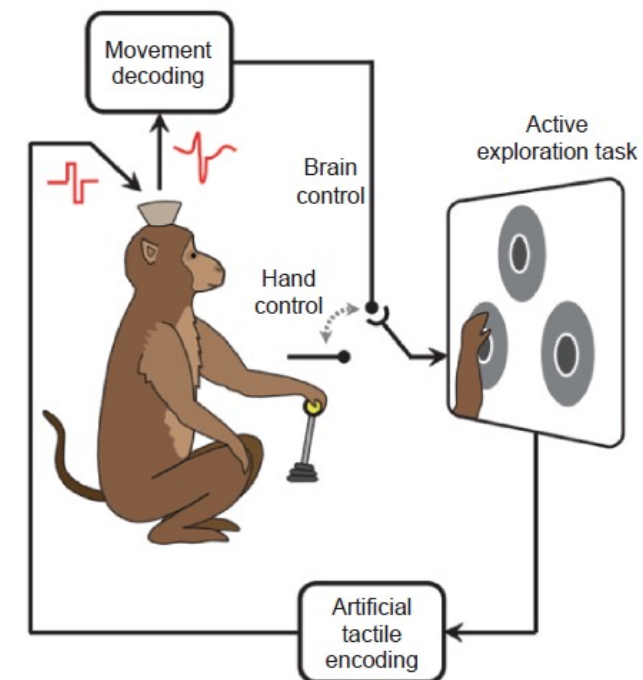
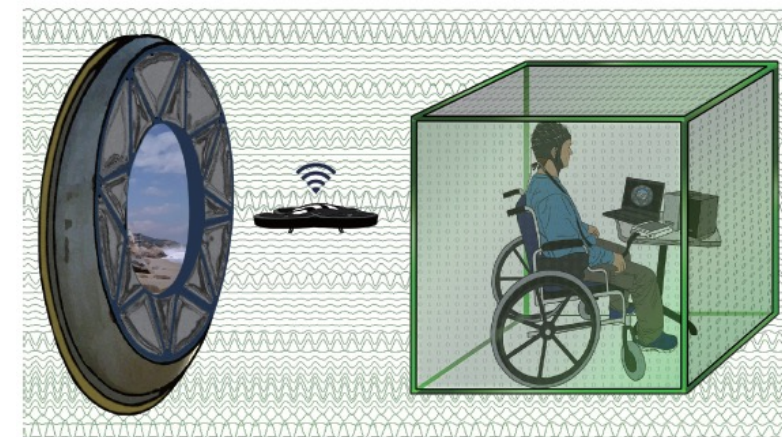
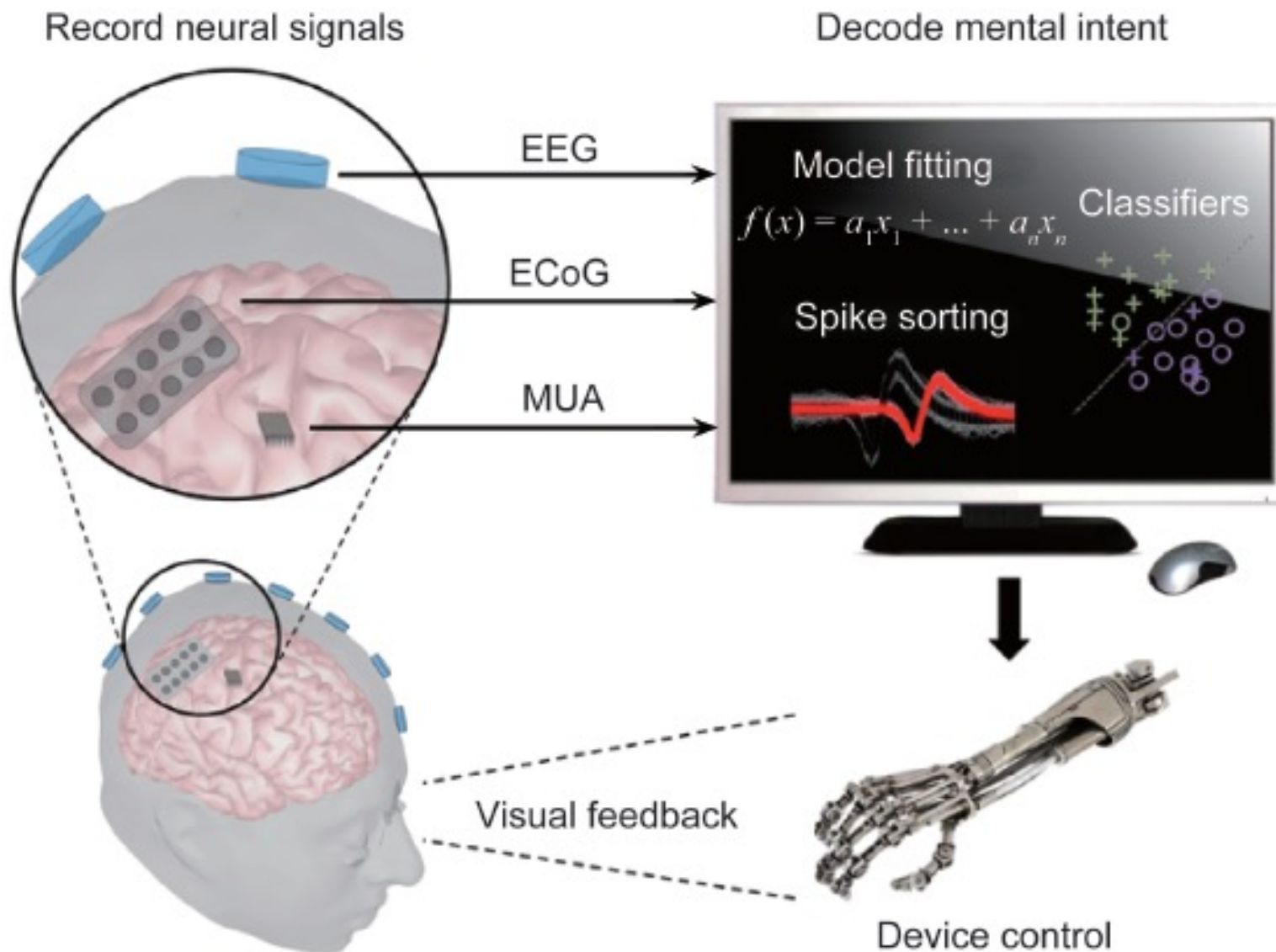


Table 1 Brain Mapping Methods Used in the Study of Human Health and Disease, along with the Types of Measurements They Provide and Some of the Clinical Situations in Which They May Be of Use

Method	Measurements provided	Disorders	Advantages	Limitations
X-ray computed tomography (CT)	1. Brain structure 2. Blood-brain barrier integrity	1. Acute/chronic hemorrhages 2. Acute trauma 3. General screening of anatomy 4. Focal or generalized atrophy 5. Hydrocephalus	1. Excellent bone imaging 2. 100% detection of hemorrhages 3. Short study time 4. Can scan patients with ancillary equipment 5. Can scan patients with metal/electronic devices	1. Ionizing radiation 2. Poor contrast resolution
Magnetic resonance imaging (MR)	1. Brain structure 2. Brain and cervical vasculature 3. Relative cerebral perfusion 4. Chemical concentrations 5. Fiber tracts 6. Blood-brain barrier integrity	1. Acute ischemia 2. Neoplasms 3. Demyelinating disease 4. Epileptic foci 5. Degenerative disorders 6. Infections 7. Preoperative mapping	1. High spatial resolution 2. No ionizing radiation 3. High resolution 4. High gray-white contrast 5. No bone-generated artifact in posterior fossa 6. Can also perform chemical, functional, and angiographic imaging	1. Long study duration 2. Patients may be claustrophobic 3. Electronic devices contraindicated 4. Acute hemorrhages problematic 5. Relative measurements only
Positron emission tomography (PET)	1. Perfusion 2. Metabolism 3. Substrate extraction 4. Protein synthesis 5. Neurotransmitter integrity 6. Receptor binding 7. Blood-brain barrier integrity	1. Ischemic states 2. Degenerative disorders 3. Epilepsy 4. Movement disorders 5. Affective disorders 6. Neoplasms 7. Addictive states 8. Preoperative mapping	1. Can perform hemodynamic, chemical, and functional imaging 2. Quantifiable results 3. Absolute physiologic variables can be determined 4. Uniform spatial resolution	1. Ionizing radiation 2. High initial costs 3. Long development time for new tracers 4. Limited access 5. Low temporal resolution
Single-photon-emission computed tomography (SPECT)	1. Perfusion 2. Neurotransmitter integrity 3. Receptor binding 4. Blood-brain barrier integrity	1. Ischemic states 2. Degenerative disorders 3. Epilepsy 4. Movement disorders	1. Can perform hemodynamic, chemical, and functional imaging 2. Widely available	1. Ionizing radiation 2. Relative measurements only 3. Nonuniform spatial resolution 4. Low temporal resolution
Xenon-enhanced computed tomography (XECT)	1. Perfusion	1. Ischemic states	1. Uses existing equipment	1. Ionizing radiation 2. High xenon concentrations have pharmacologic effects
Spiral computed tomography (CT angiography, CTA)	1. Vascular anatomy 2. Boney anatomy	1. Vascular occlusive disease 2. Vascular and boney anatomy only	1. Provides high-resolution vascular images	1. Ionizing radiation 2. Vascular and boney anatomy only
Electroencephalography surface (EEG)	1. Electrophysiology	1. Epilepsy 2. Encephalopathies 3. Degenerative disorders 4. Preoperative mapping	1. No ionizing radiation 2. High temporal resolution 3. Widely available 4. Can identify epileptic foci	1. Low spatial resolution 2. Weighted toward measurements
Magnetoencephalography (MEG)	1. Electrophysiology	1. Epilepsy	1. No ionizing radiation 2. High temporal resolution 3. Can identify epileptic foci	1. Low spatial resolution
Transcranial, magnetic stimulation (TMS)	1. Focal brain activation	1. Preoperative mapping	1. No ionizing radiation 2. Potential for therapy 3. Can be linked to other imaging methods (PET fMRI)	1. Low spatial resolution 2. Has produced seizures in certain patient groups
Optical intrinsic signal imaging (OIS)	1. Integrated measure of blood volume, metabolism, and cell swelling	1. Intraoperative mapping	1. No ionizing radiation 2. High temporal resolution 3. High spatial resolution	1. Complex signal source 2. Invasive only (intraoperative)