

Digestive System

The organs that are involved in the breaking down of food into molecules that can pass through the wall of the digestive tract and can be taken up by the cells.

Digestive Processes

There are five basic activities that are involved in the digestive process

1. **Ingestion**- The taking of food into the mouth.
2. **Mixing and movement of food**- Involves the muscular contractions (peristalsis) that mix the food and move it along the digestive tract.
3. **Digestion**- The break down of food by mechanical and chemical means.
4. **Absorption**- The passage of food from the digestive tract into the cardiovascular and lymphatic system.
5. **Defecation**- The elimination of indigestible waste.

Digestion: Two Stages

- Mechanical digestion
 - Physical breakdown of food into smaller particles by the cutting and grinding action of the teeth and the churning contractions of the stomach and small intestines
 - Serves to expose more food surface to the actions of the digestive enzymes

Digestion: Two Stages

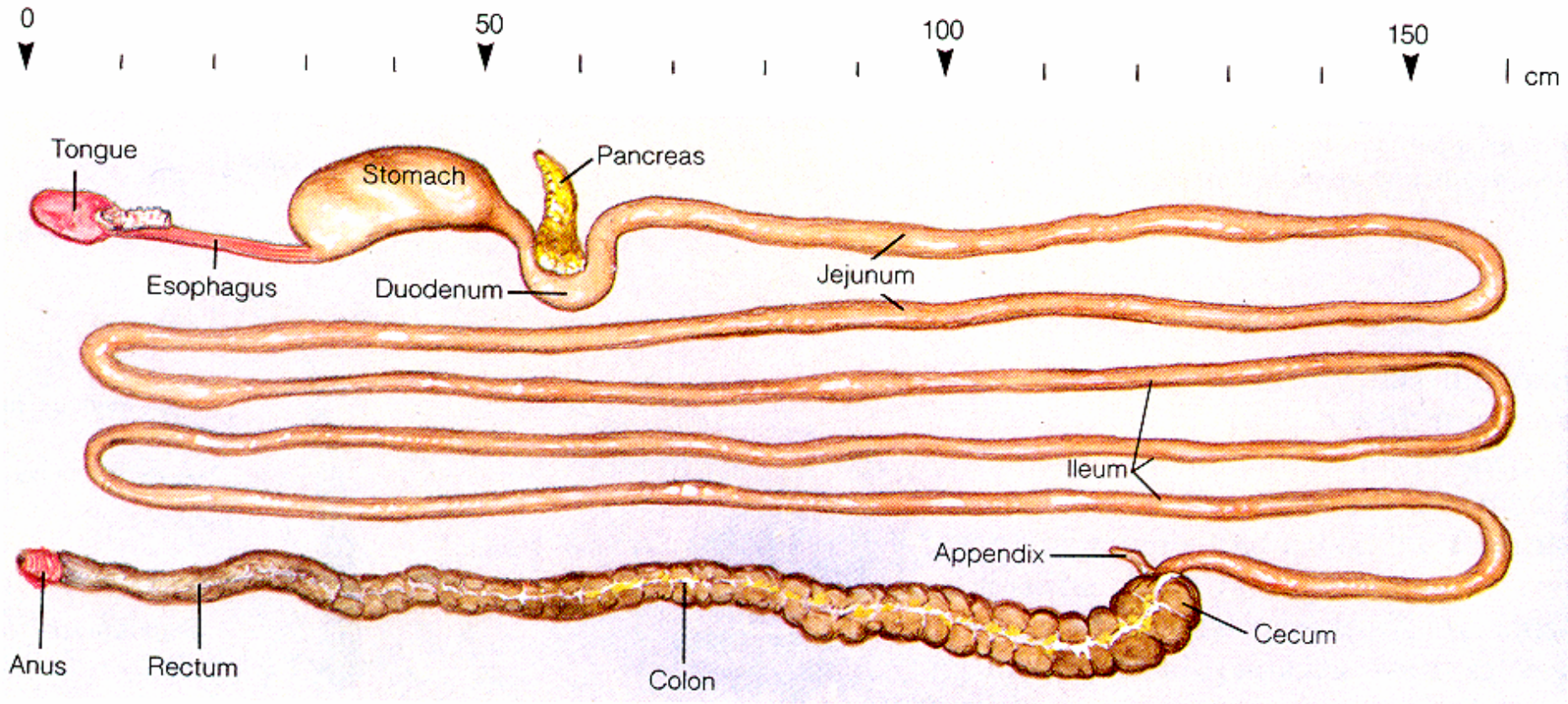
- Chemical digestion
 - A series of hydrolysis reactions that break macromolecules into their monomers
 - Polysaccharides into monosacharides
 - Proteins into amino acids
 - Nucleic acids into nucliotides
 - Fats inito glycerol and fatty acids
 - Hydrolysis carried out by digestive enzymes from the
 - Salivary glands, stomach
 - Pancreas
 - small intestine
 - Some foods are absorbed without enzymatic action
 - Vitamins, free amino acids, minerals, cholesterol, and water

Processes in Digestion

- **Motility**- the muscular contractions that break up food, mix, and propel food
- **Secretion**- the release of enzymes and hormones that carry out and regulate digestion
- **Membrane transport**- all the mechanisms that absorb nutrients and transfer them into the blood and lymph (active transport, facilitated diffusion, etc.)

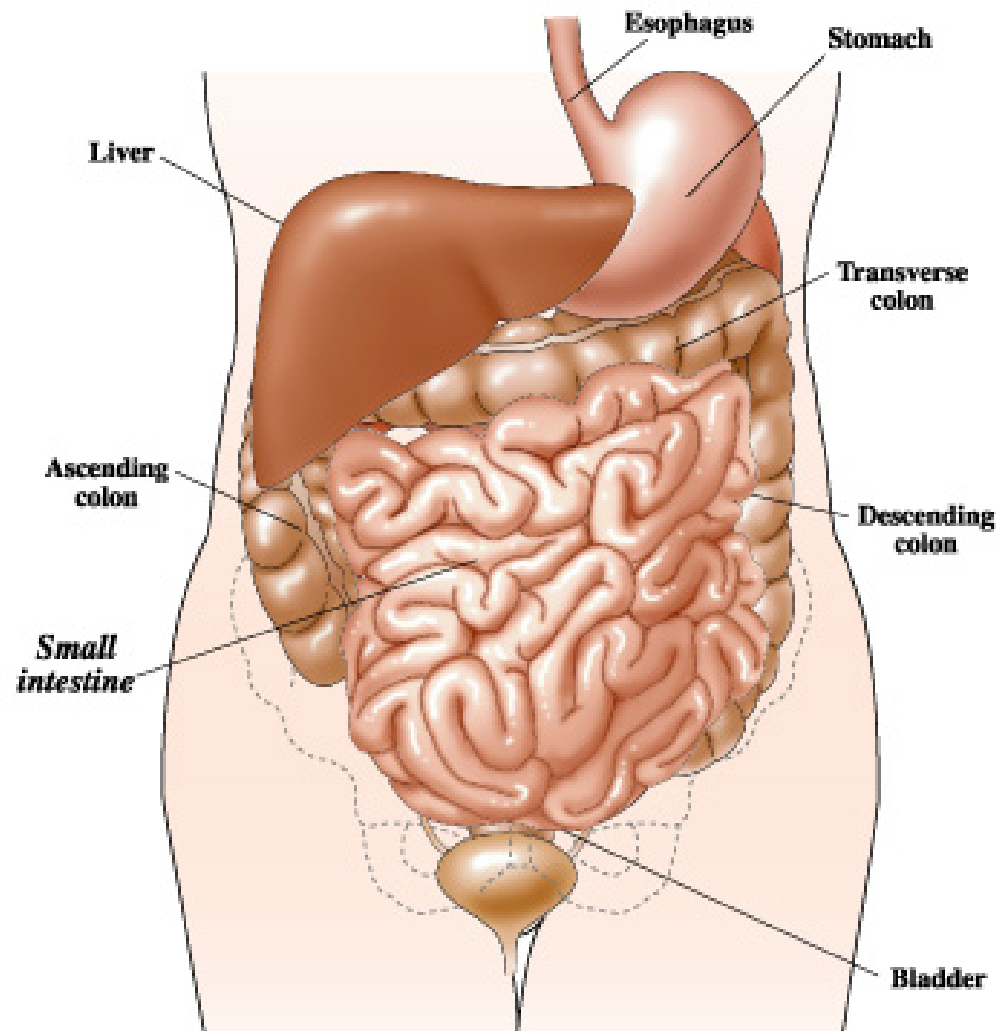
Organization

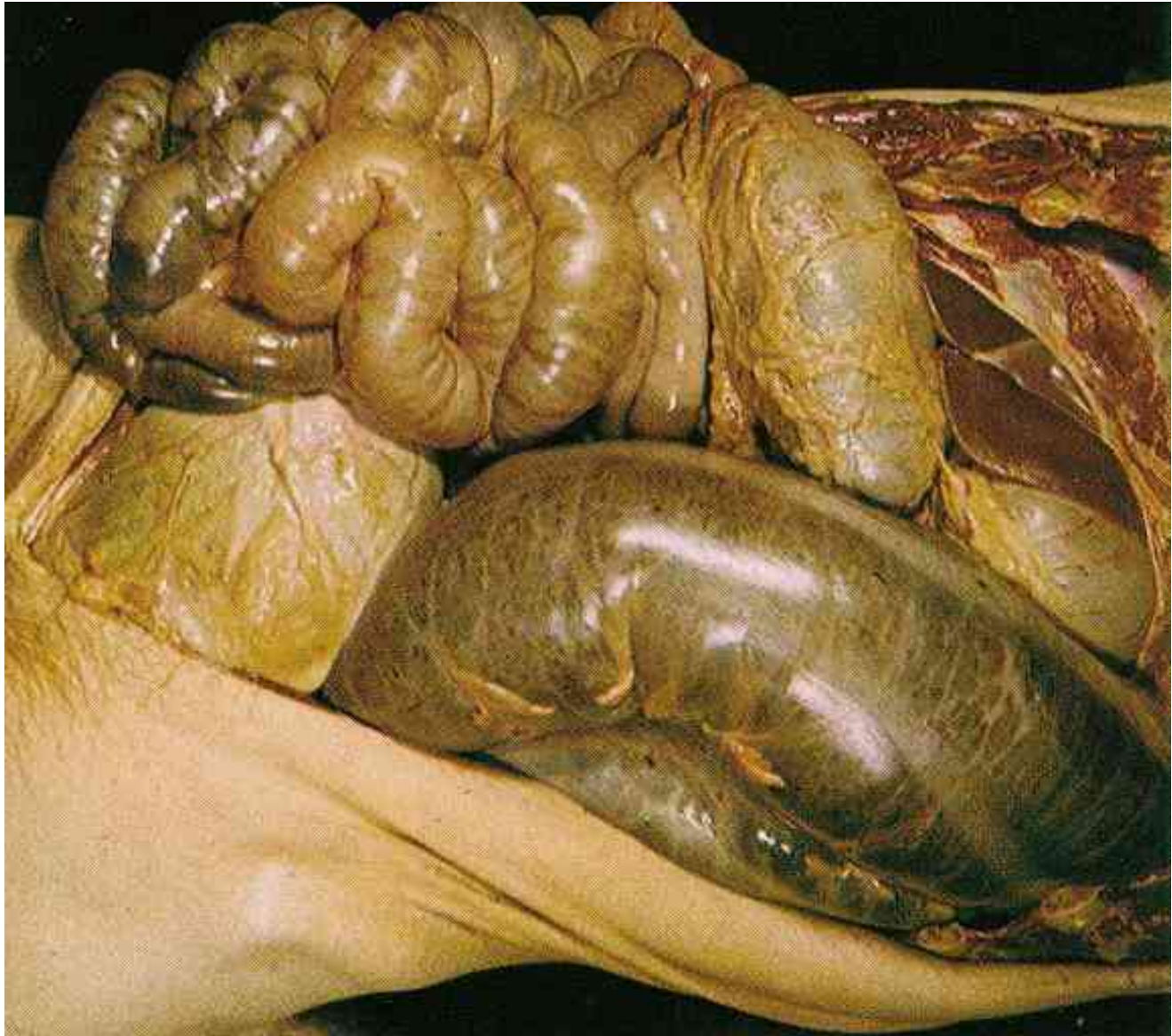
- GI tract or **Alimentary canal**- the continuous tube that begins at the mouth and ends at the anus.
 - Mouth, pharynx, esophagus, stomach, small intestine, and large intestine
- **Accessory organs**- Aid in the digestive process by mechanical manipulation and secreting various substances (enzymes, mucus)
 - teeth, tongue, salivary glands, liver, gallbladder, and pancreas.

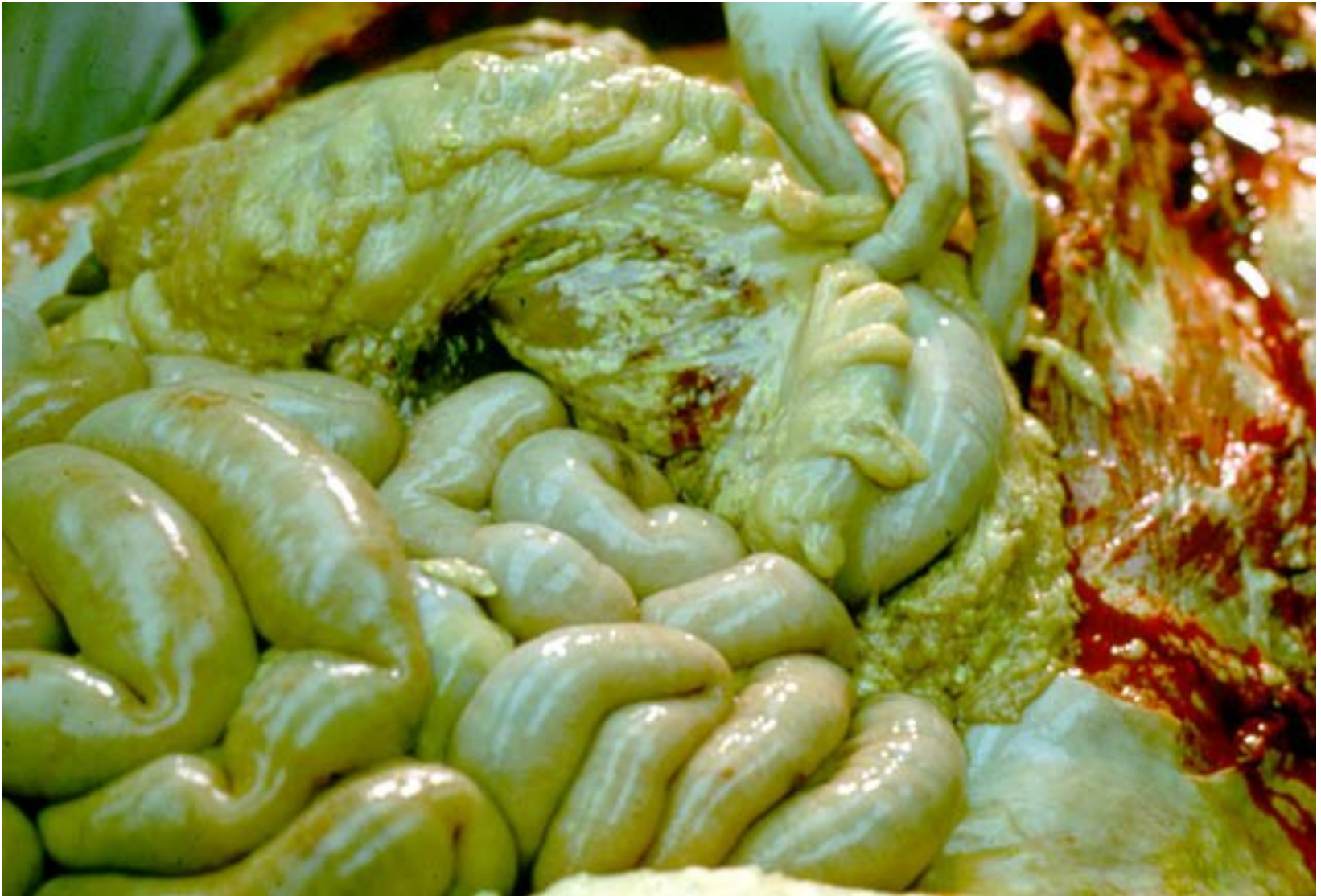

Aprox. 30 ft in the cadaver.

NORMAL ABDOMINAL ANATOMY







Perforated colon cancer

This was a cancer of the hepatic flexure which perforated, producing a bacterial peritonitis with abundant free bile as well.

Four Layers of the GI Tract

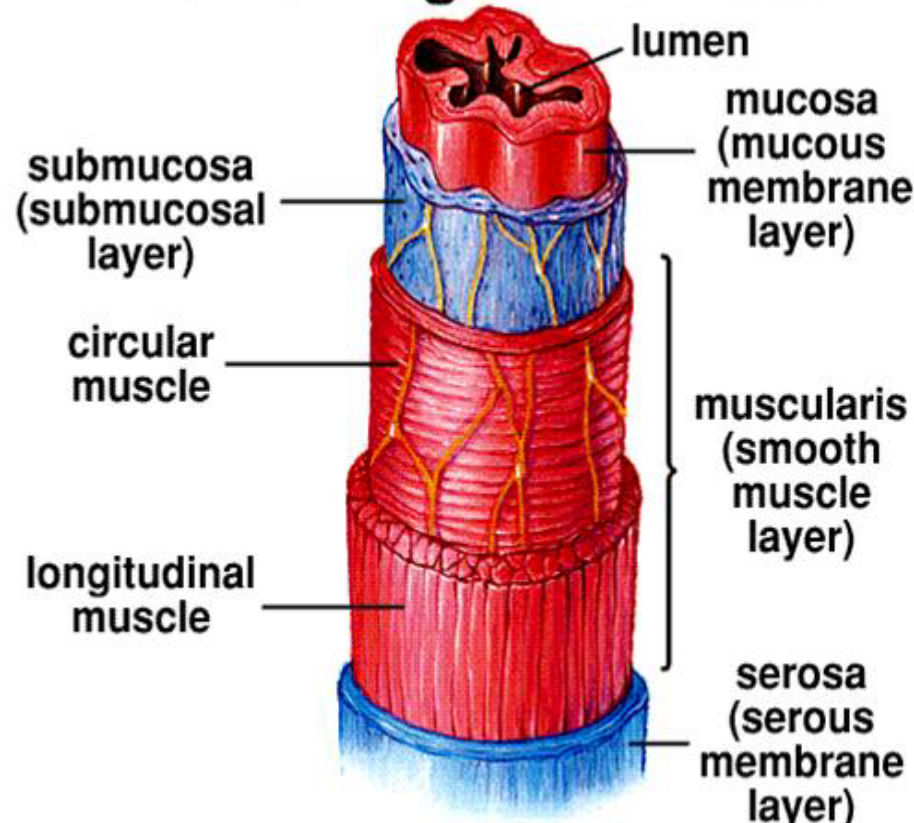
- Mucosa
 - Epithelium
 - Lamina propria
 - Muscularis mucosa
- Submucosa
- Muscularis
 - Internal oblique (only in the stomach)
 - Inner circular layer
 - Outer longitudinal layer
- Serosa
 - Areolar tissue
 - mesothelium

General Histology

Mucosa

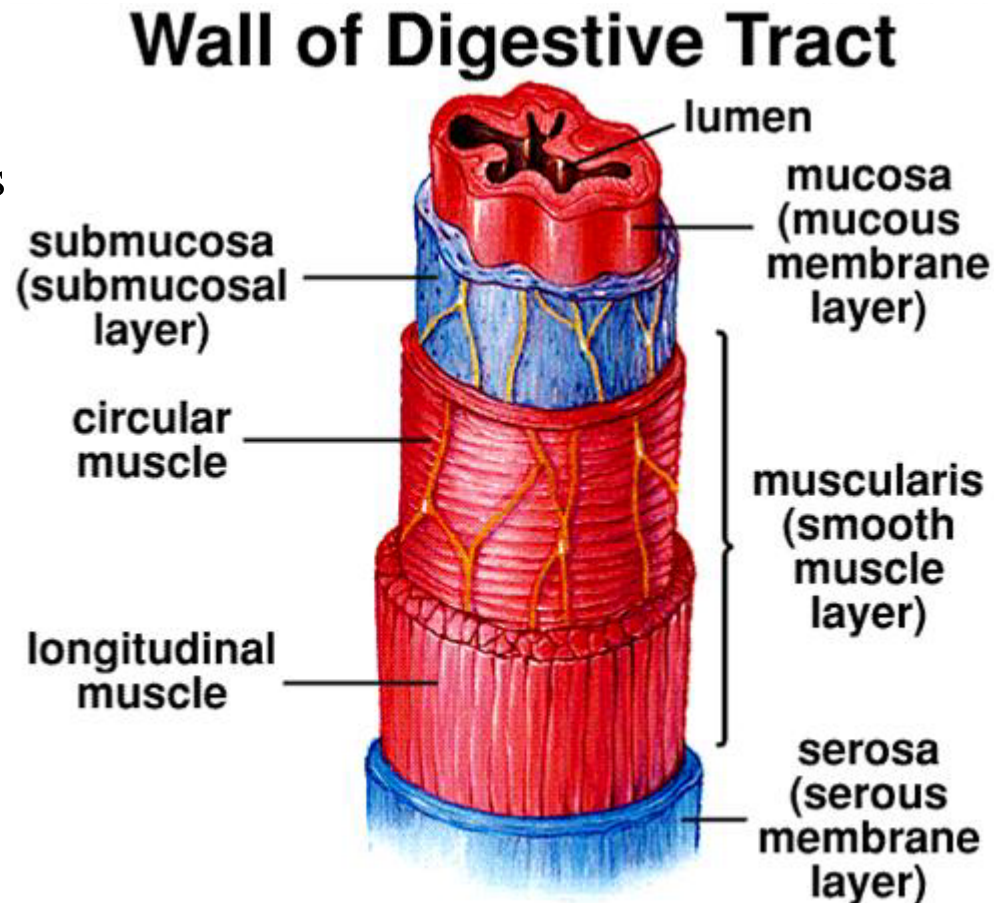
- The inner layer of the tract that is a mucous membrane that is composed of a
 - **layer of epithelium-** simple columnar in most of the GI tract
 - Nonkeratinized stratified squamous from the oral cavity through the esophagus and in the lower anal canal (areas subject to abrasion)
 - **Lamina propria-** areolar connective tissue containing blood and lymphatic vessels
 - **muscularis mucosae-** a thin layer of smooth muscle (is responsible for the mucosal folds, or **rugae**, that serves to increase the surface area for digestion.
- Is the most highly differentiated layer of the GI tract.
 - Tissue specialization and surface shape are correlated with functional differentiation along the tract.

Wall of Digestive Tract



General Histology

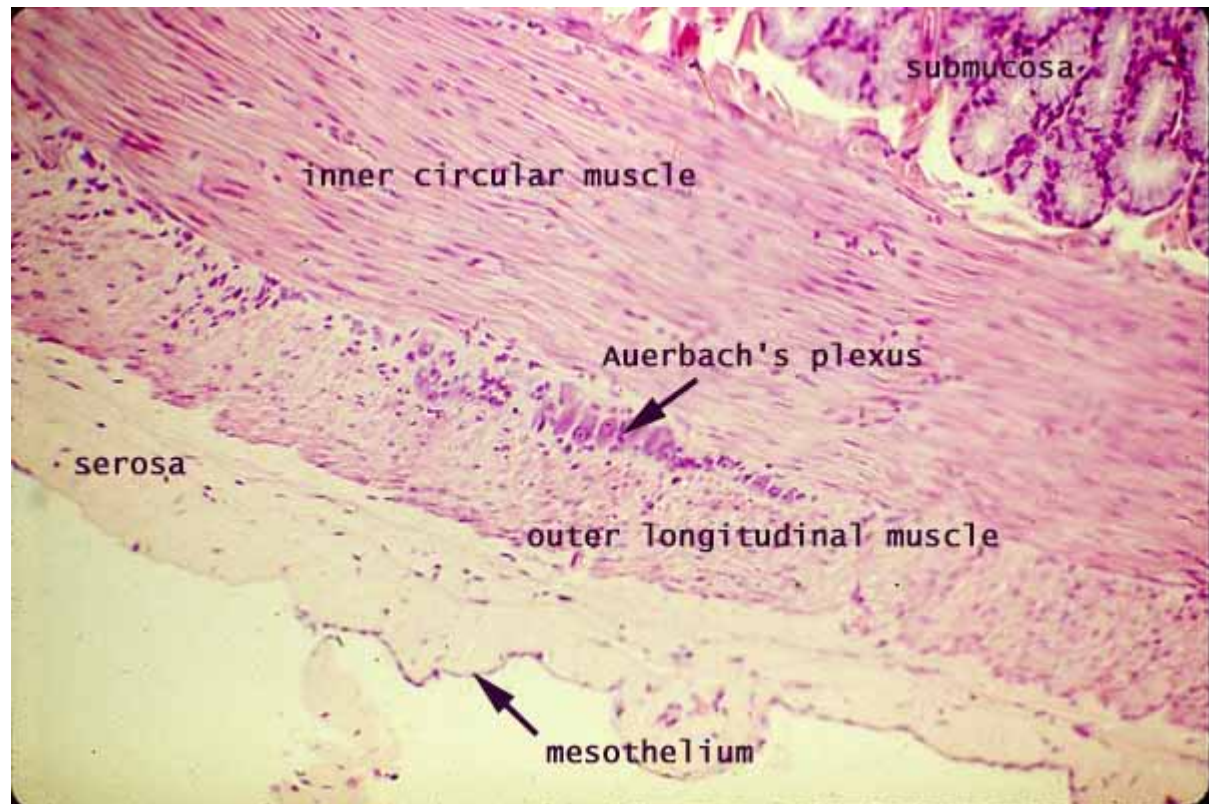
- **Submucosa**- consist of
 - areolar c.t. that binds the mucosa to the underlying muscle layer.
 - blood vessels, lymphatics, a nerves plexus, glands that secrete lubricating mucus into the lumen
- **Muscularis** - A thick layer of muscle that under lies the submucosa
 - begins at the mouth where it is composed of a mixture of smooth and striated muscle (for voluntary swallowing) and the external sphincter where it is skeletal.
 - At the distal pharynx it turns into all smooth muscle that courses throughout the rest of the tract.
 - The involuntary smooth muscle consist of an **inner circular** and an **outer longitudinal** layer.



General Histology

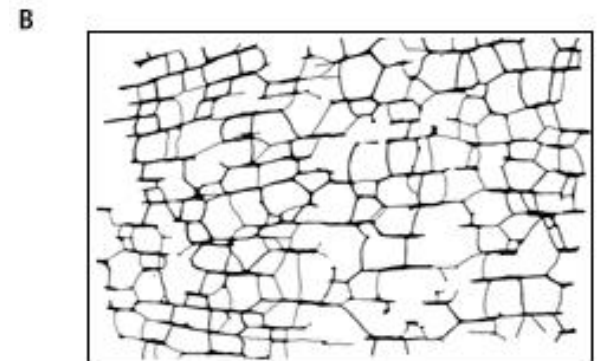
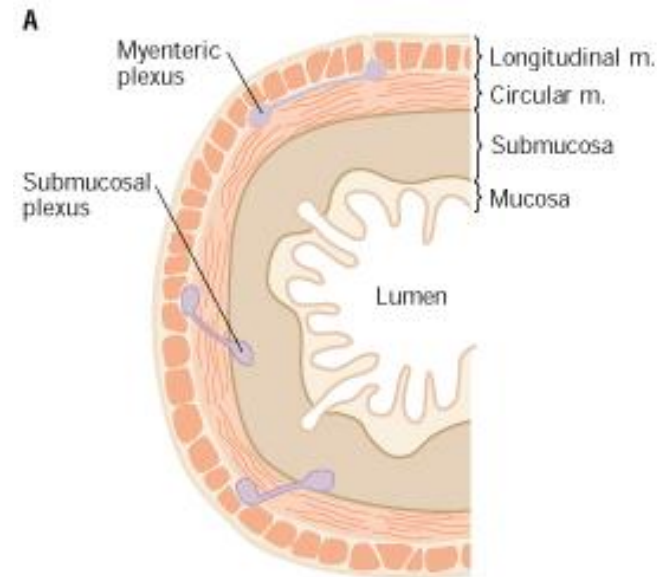
Serosa- The outermost layer of the GI tract.

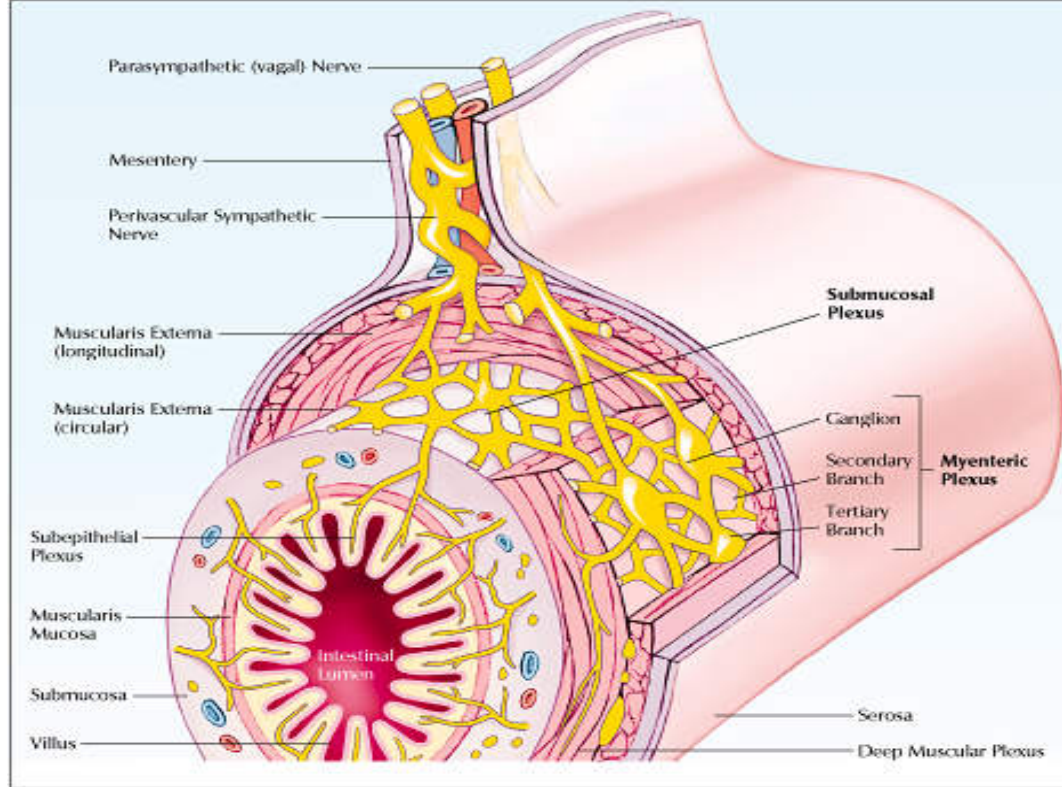
- Composed of a thin layer of areolar tissue topped by a serous membrane (mesothelium)
- Begins in the lower 3 to 4 cm of the esophagus and ends with the sigmoid colon
- When the outer fibrous c.t. layer is attached to surrounding tissue it is called **adventitia** –
 - See this at the oral cavity, pharynx, most of the esophagus, and the rectum
It secretes fluid that allows the tract structures to glide over each other without friction. It is also referred to as visceral peritoneum.



Enteric Nervous System

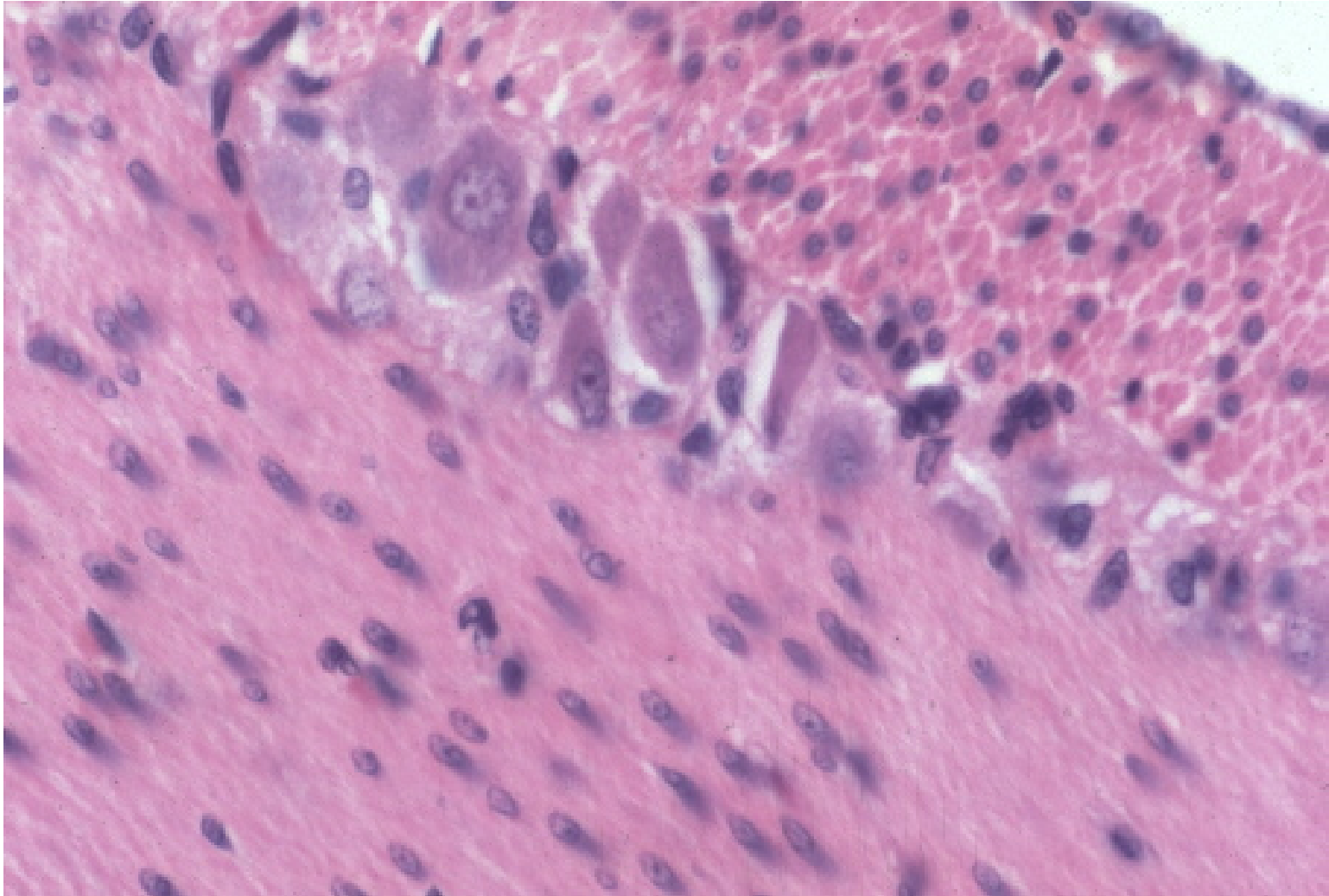
- Regulates digestive tract motility, secretion, and blood flow
- Composed of two ganglionated nerve networks
 - **Submucosal (Meissner) plexus**- in the submucosa
 - **Myenteric (Auerbach) plexus**- between the two layers of the muscularis externa





- **Myenteric (Auerbach) plexus**- larger plexus, situated between the circular and longitudinal layer of the muscularis externa
 - Contains neurons responsible for motility and for mediating the enzyme output of adjacent organs
- **Submucosal (Meissner) plexus**- smaller plexus
 - Contains sensory cells that “talk” to the motor neurons of the myenteric plexus
 - Motor fibers that stimulate secretion from epithelial crypt cells in the gut lumen
- Note **parasympathetic (vagal) fibers** entering the bowel in the mesentery, **perivascular sympathetic input** to the gut, and the subepithelial plexus of nerve fibers in the lamina propria of the mucosa

Auerbach's Plexus



General Histology

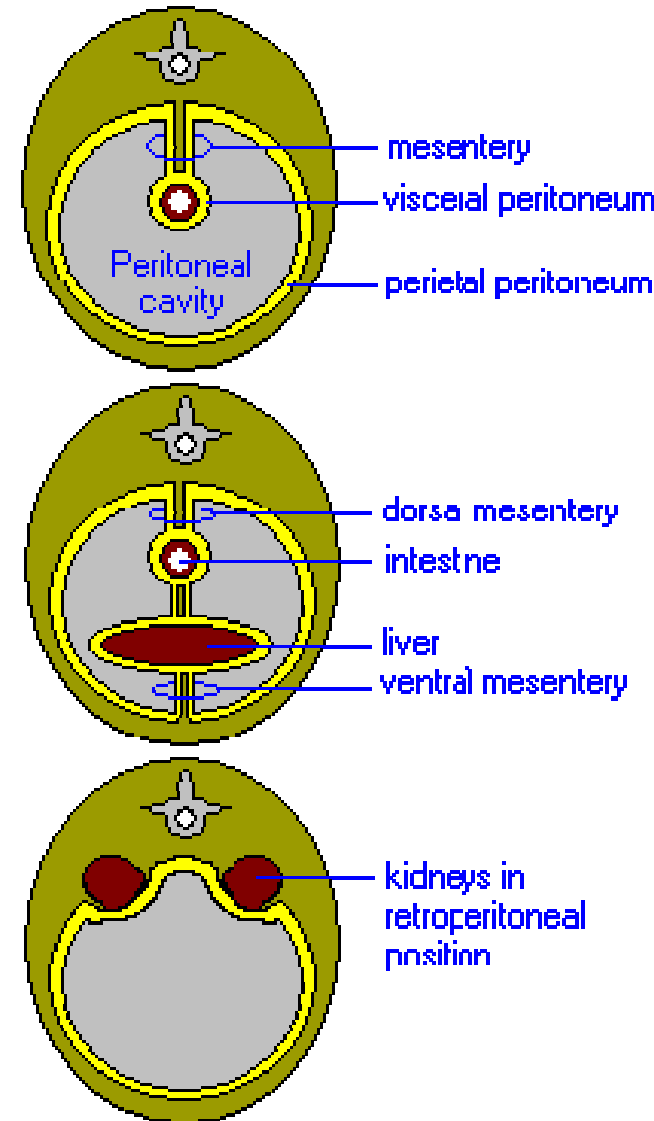
Peritoneum- is the largest serous membrane in the body. Composed of the

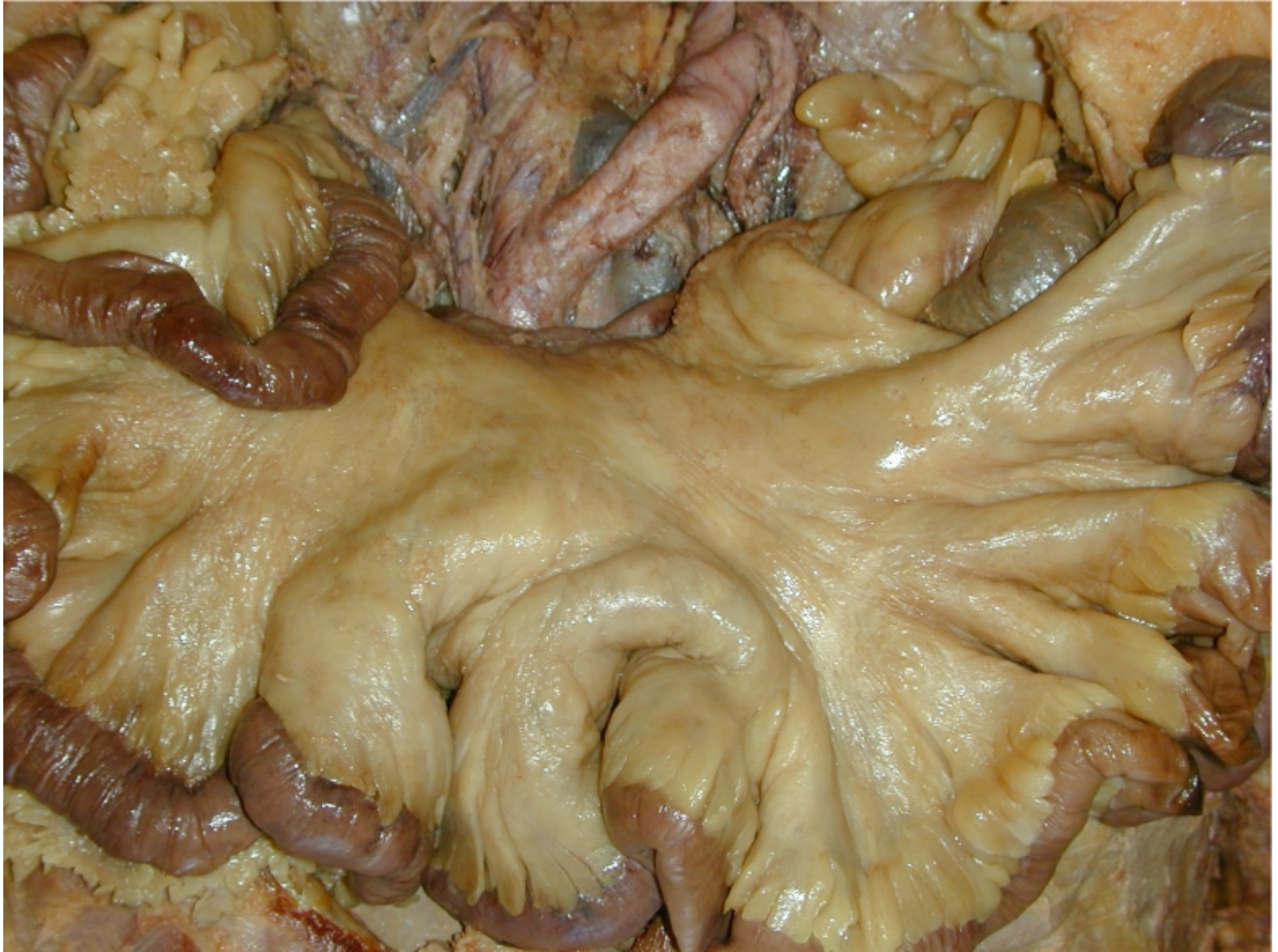- parietal and
- visceral components.
- It functions to bind the organs together and to provide a surface through which blood vessels, lymphatics, and nerves, supply the abdominal organs.
 - The stomach and intestines are enfolded and suspended from the body wall by extensions of the peritoneum

It consist of the

Mesentary- A fold of peritoneum formed by the fusion of the serosa on each side of the digestive tube that binds the small intestine to the posterior abdominal wall.

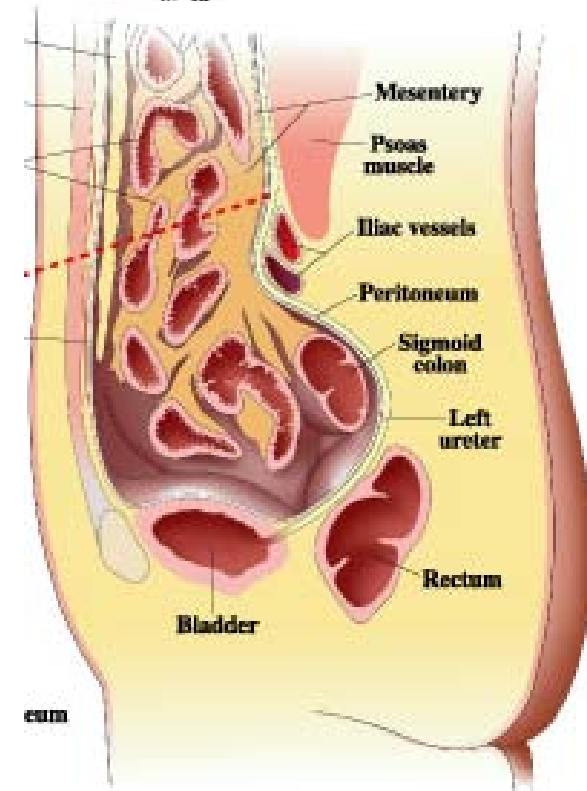
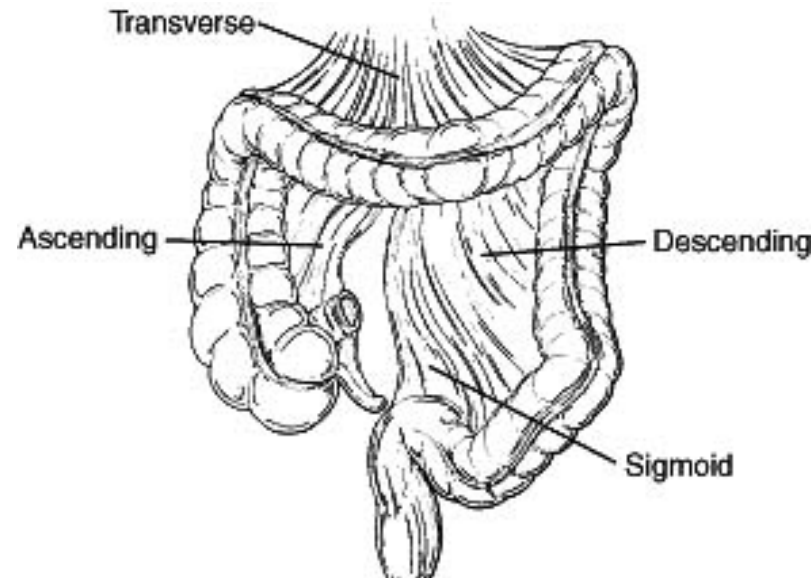
Cross sections through the abdomen

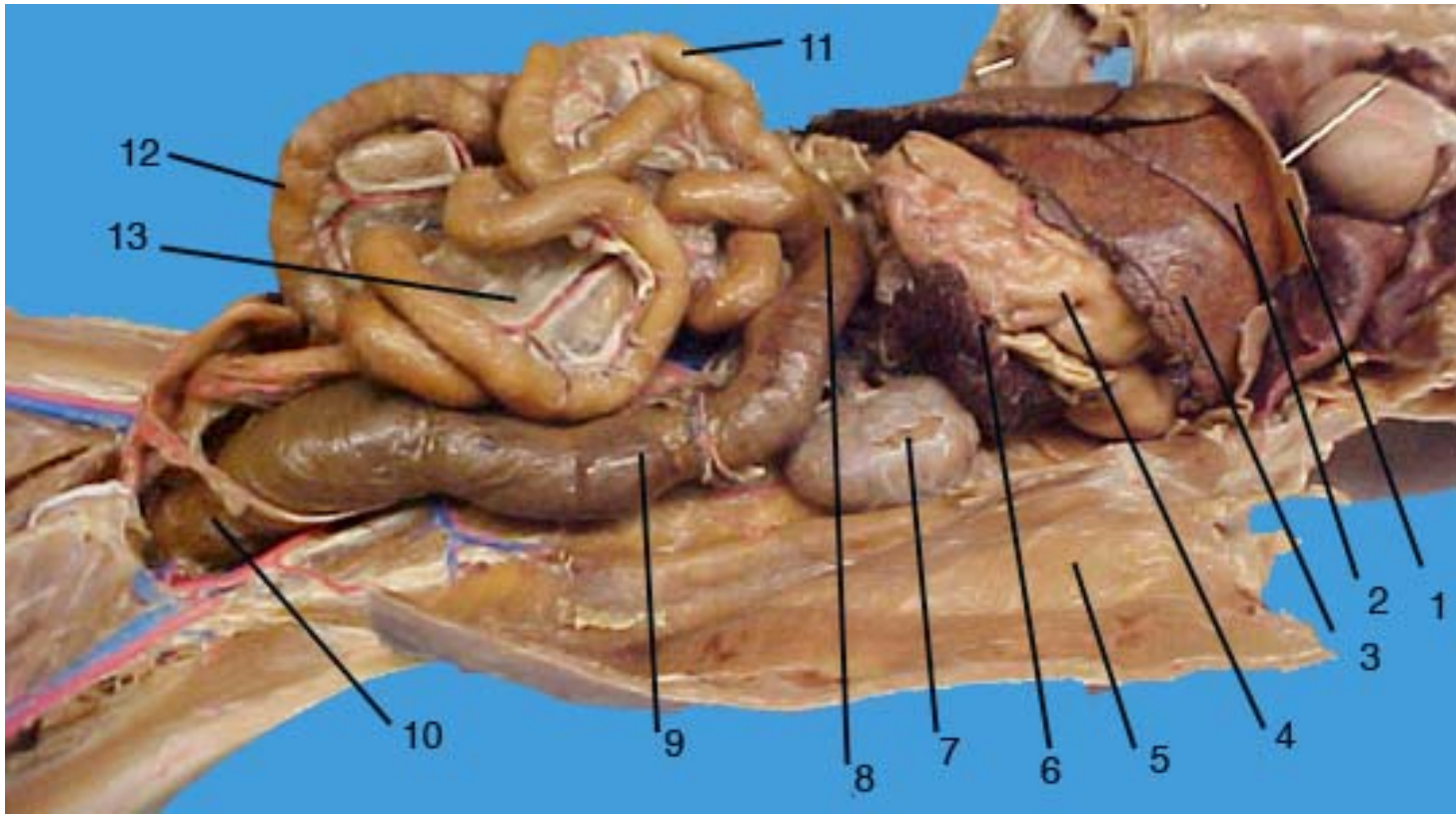




Mesocolon – a fold of peritoneum that binds the large intestine to the posterior abdominal wall.

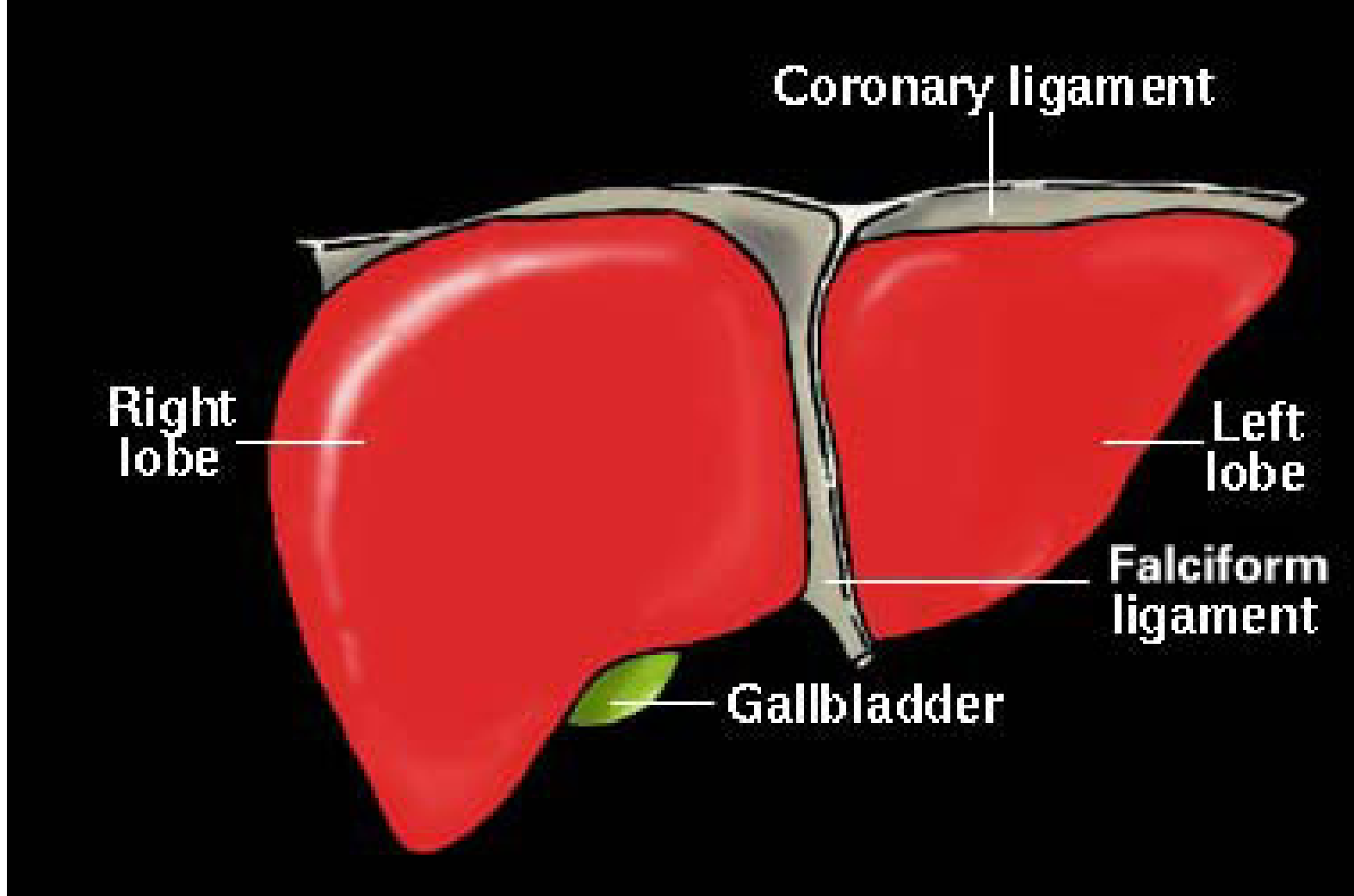
- It is divided into ascending, transverse, descending, and sigmoid or pelvic portions, according to the segment of the colon to which it gives attachment.





- 1. Diaphragm
- 2. Left medial lobe of liver
- 3. Left lateral lobe of liver
- 4. Stomach
- 5. Parietal peritoneum
- 6. Spleen
- 13. Mesentery

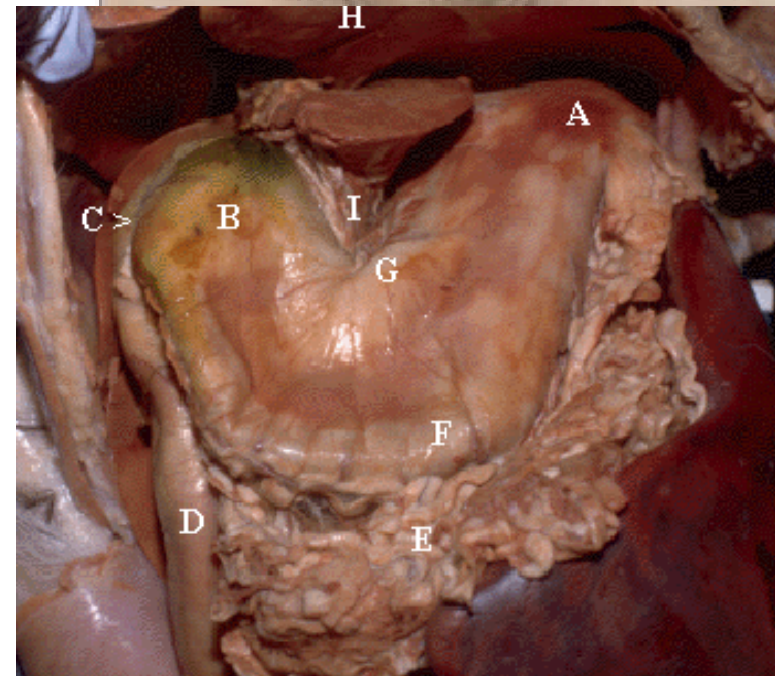
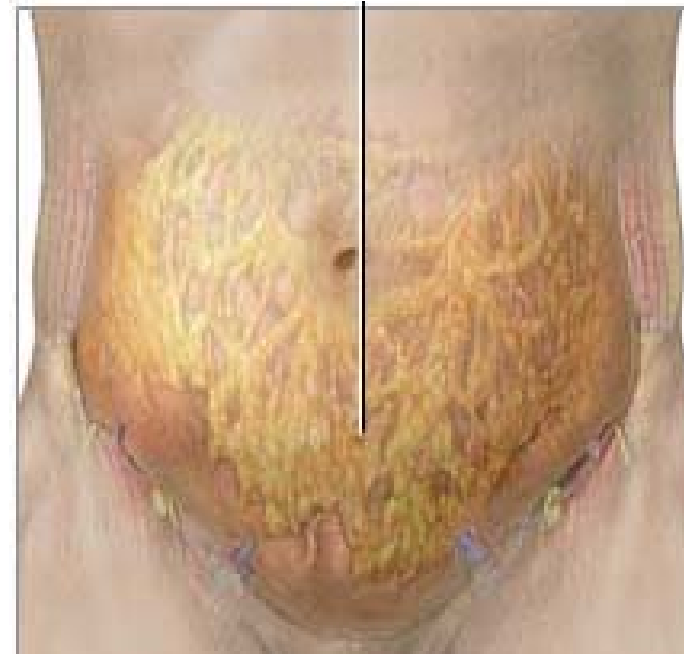- 7. Kidney with renal capsule
- 8. Transverse colon
- 9. Descending colon
- 10. Rectum
- 11. Jejunum
- 12. Ileum

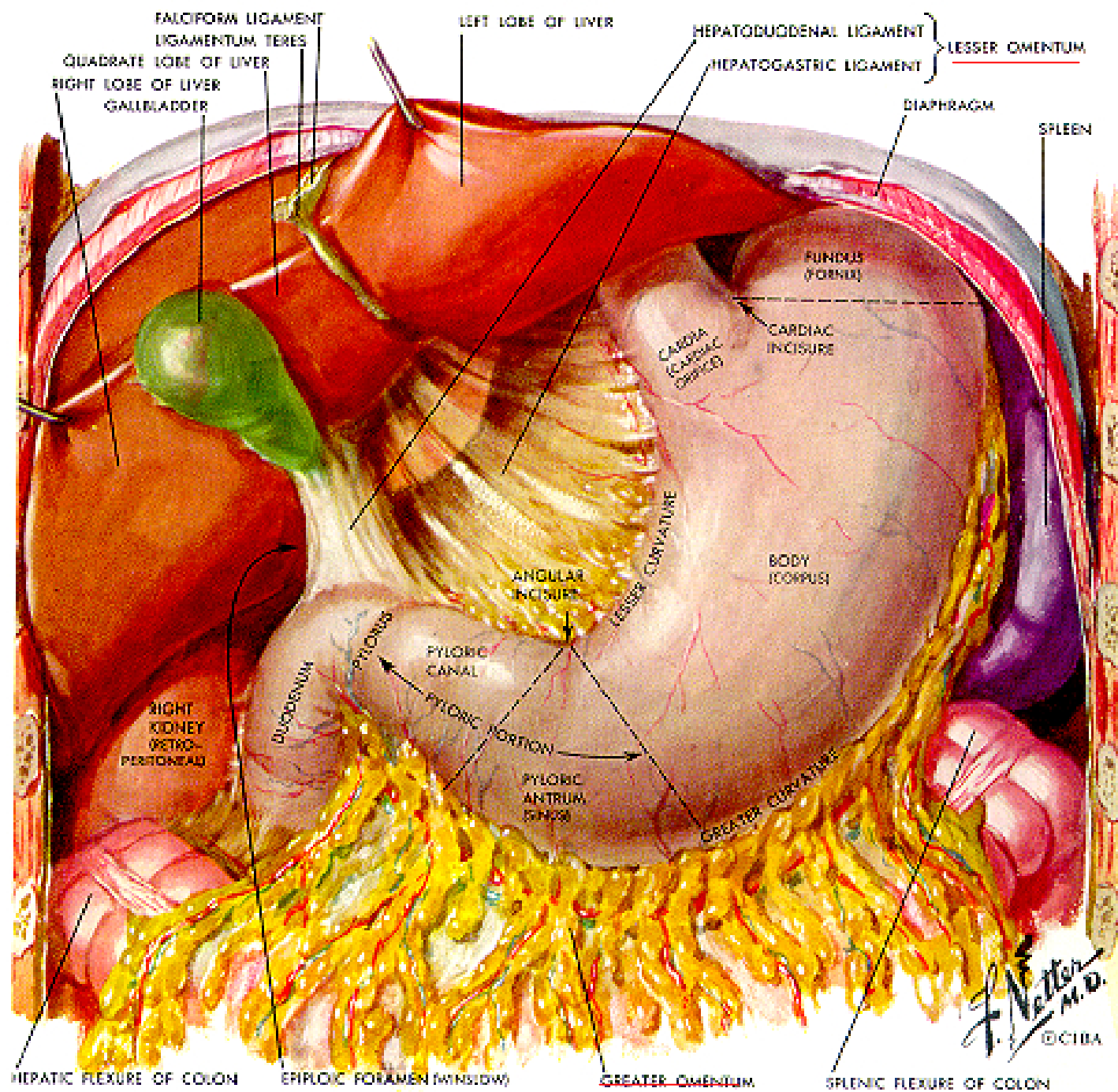


Falciform ligament- attaches the liver to the anterior abdominal wall and diaphragm.

Greater Omentum

- **Greater omentum-** a sheet of fat that hangs from the left inferior margin (greater curvature) of the stomach and drapes over the transverse colon and coils of the intestine like a apron.
 - It contains many lymph nodes that combat infection that may occur in the abdominal cavity.
- **Lesser omentum-** peritoneal fold that suspends the stomach (at the lesser curvature) and the duodenum form the liver





FALCIFORM LIGAMENT
 LIGAMENTUM TERES
 QUADRATE LOBE OF LIVER
 RIGHT LOBE OF LIVER
 GALLBLADDER

LEFT LOBE OF LIVER

HEPATODUODENAL LIGAMENT
 HEPATOGASTRIC LIGAMENT } LESSER OMENTUM

DIAPHRAGM
SPLEEN

FUNDUS (VOMIX)

CARDIA (CARDIAC ORIFICE)

CARDIAC INCISURE

ANGULAR INCISURE

LESSER CURVATURE

BODY (CORPUS)

RIGHT KIDNEY (RETRO-PESTONEAL)

DUODENUM

PYLORUS

PYLORIC CANAL

PYLORIC PORTION

PYLORIC ANTRUM (SIGMA)

GREATER CURVATURE

HEPATIC FLEXURE OF COLON

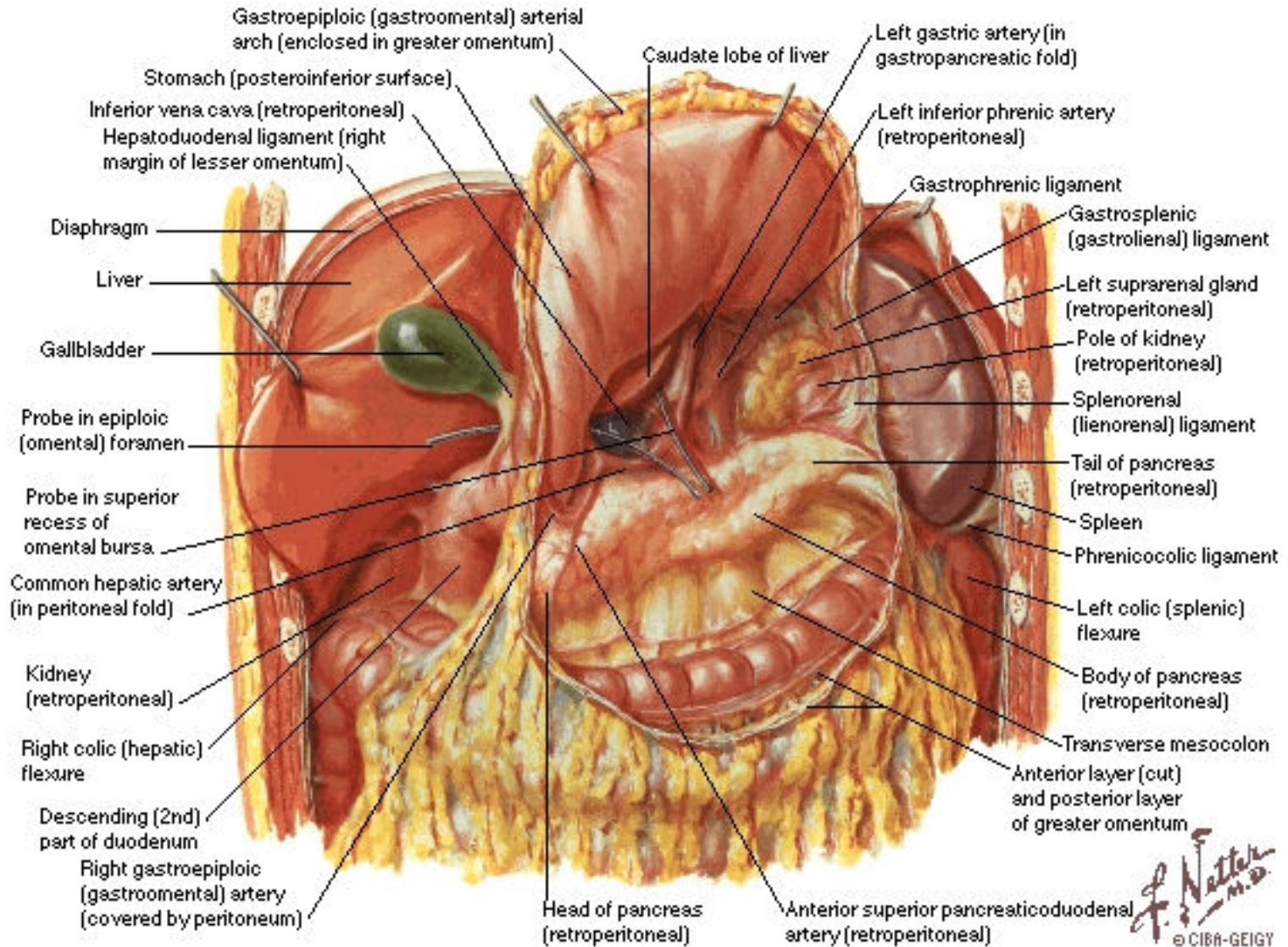
EPILIC FORAMEN (WINLOW)

GREATER OMENTUM

SPLenic FLEXURE OF COLON

F. Netter
 M.D.
 © CIBA

Stomach Reflected



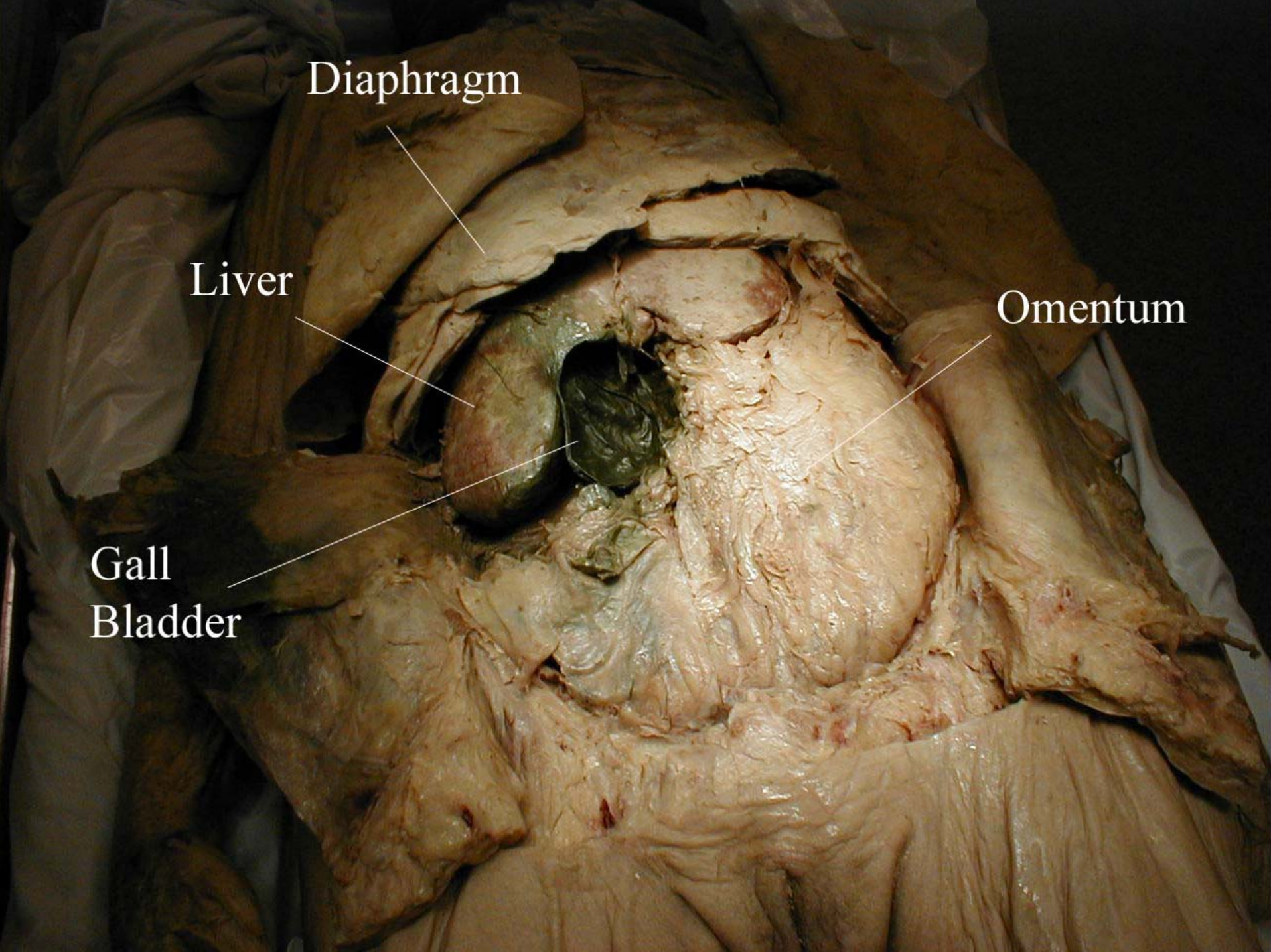
F. Netter M.D.
© CIBA-GEIGY

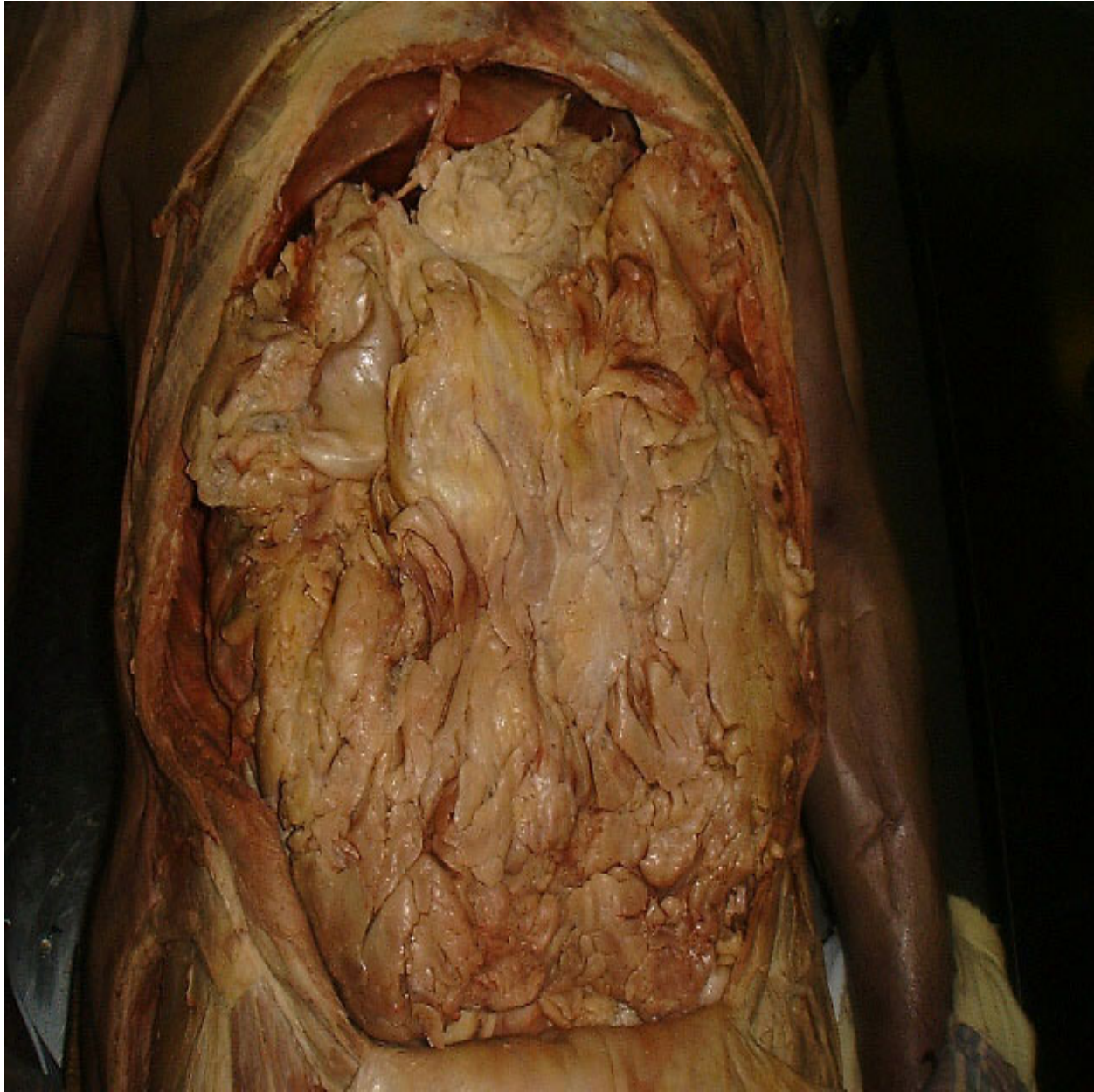Diaphragm

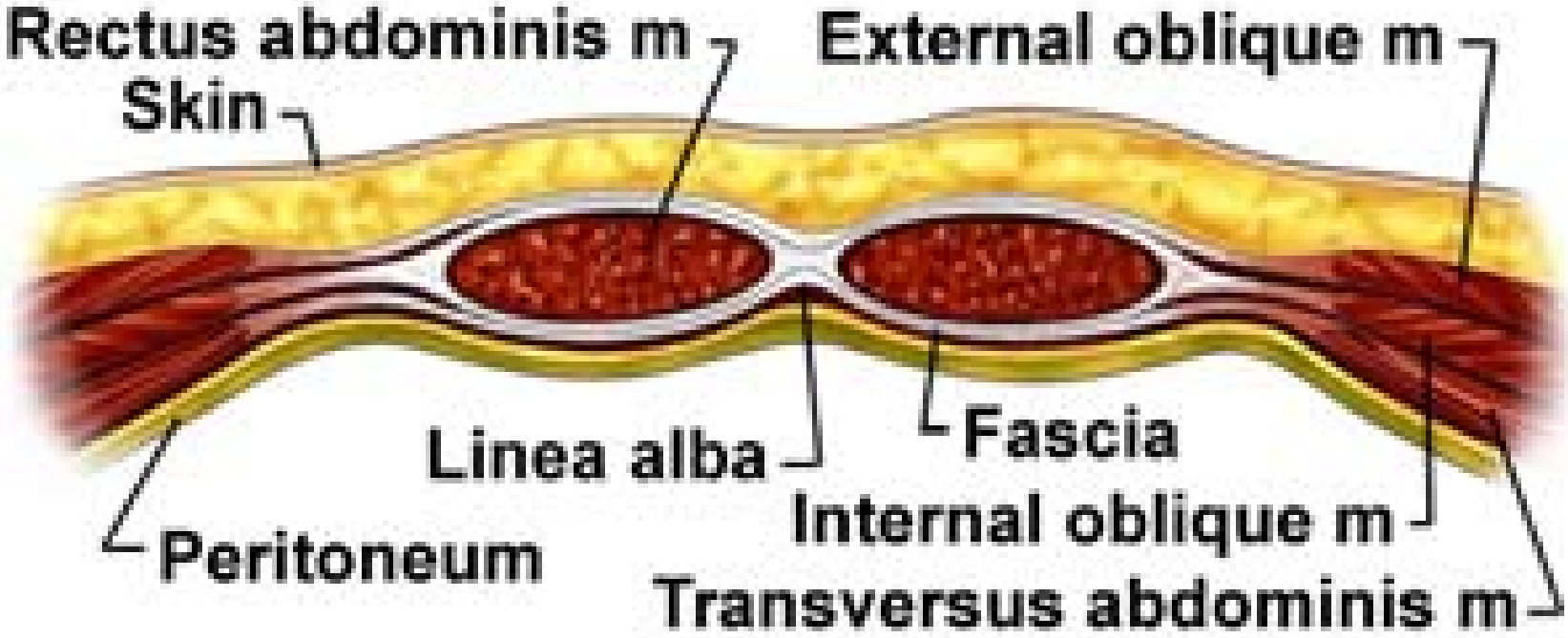
Liver

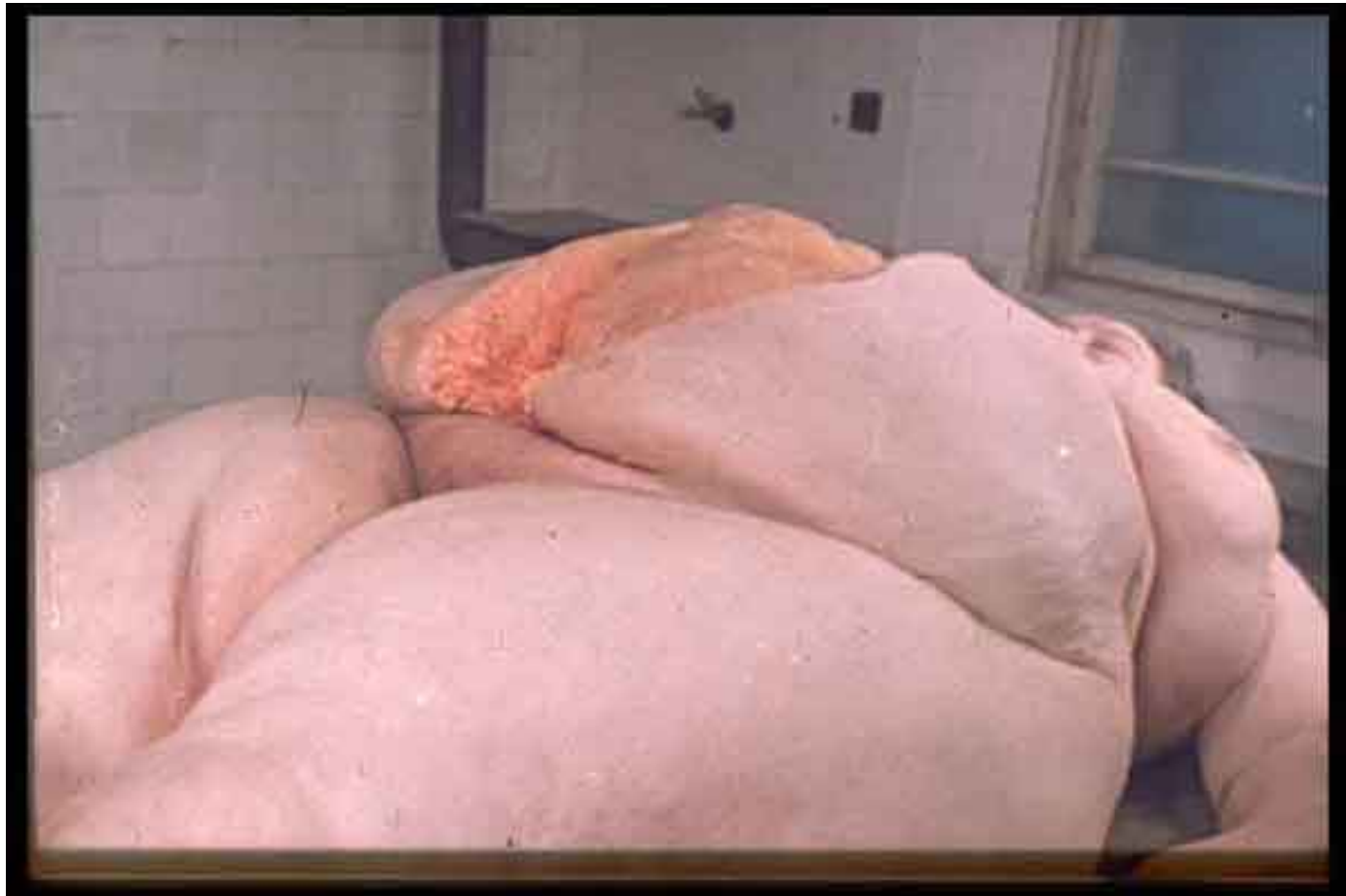Omentum

Gall
Bladder

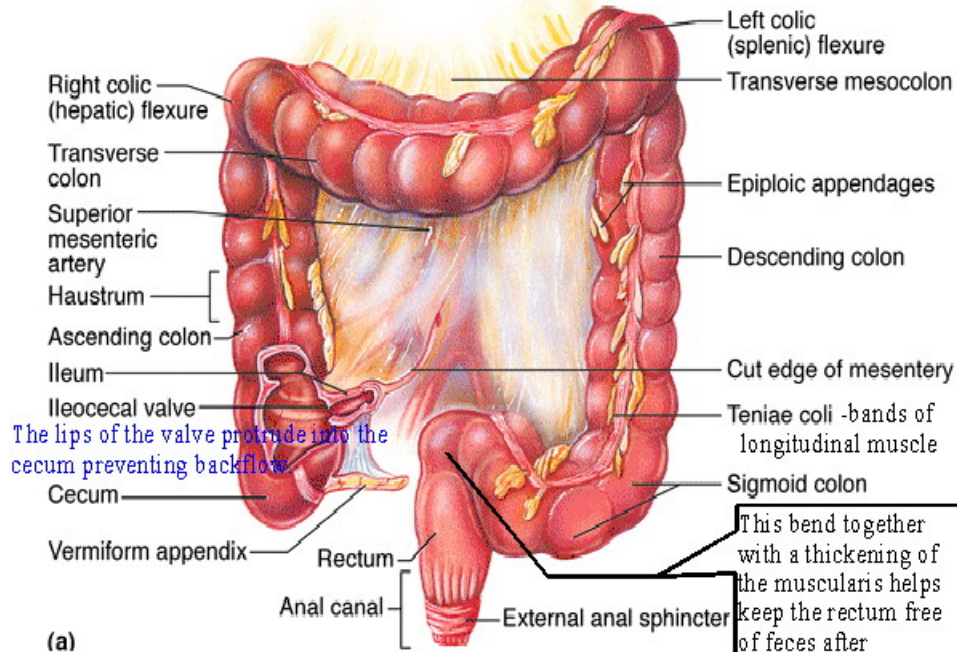




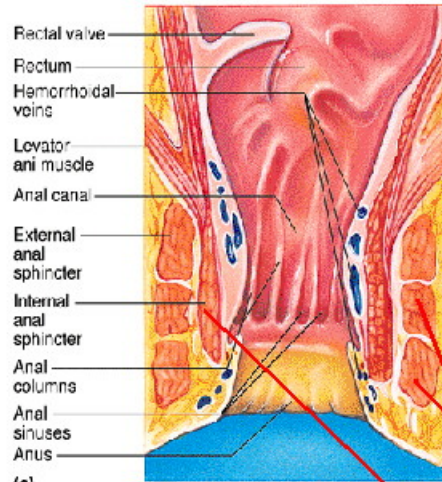




The Colon

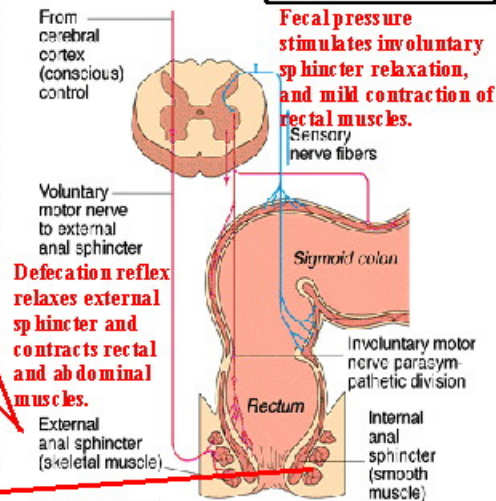


(a)

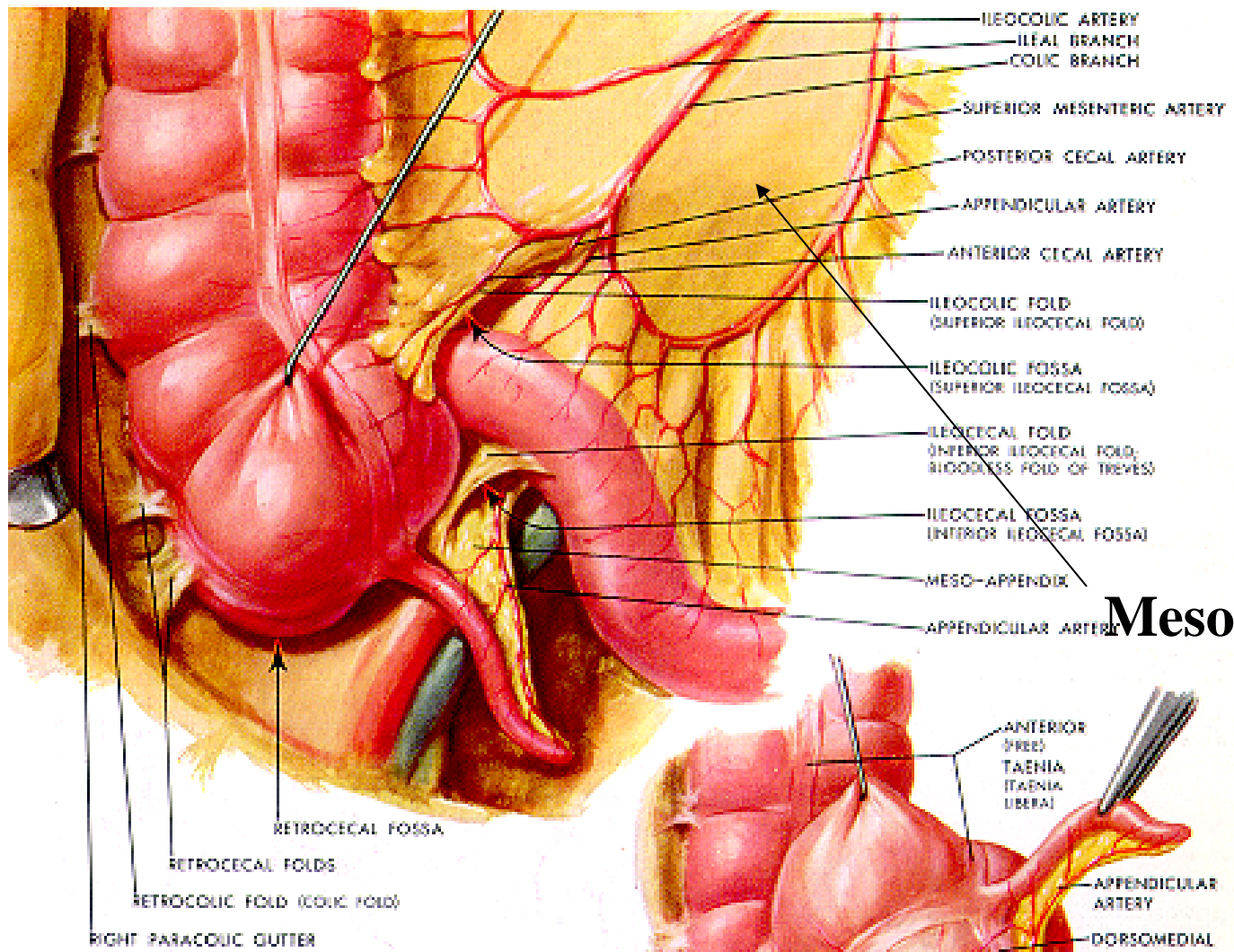


(c)

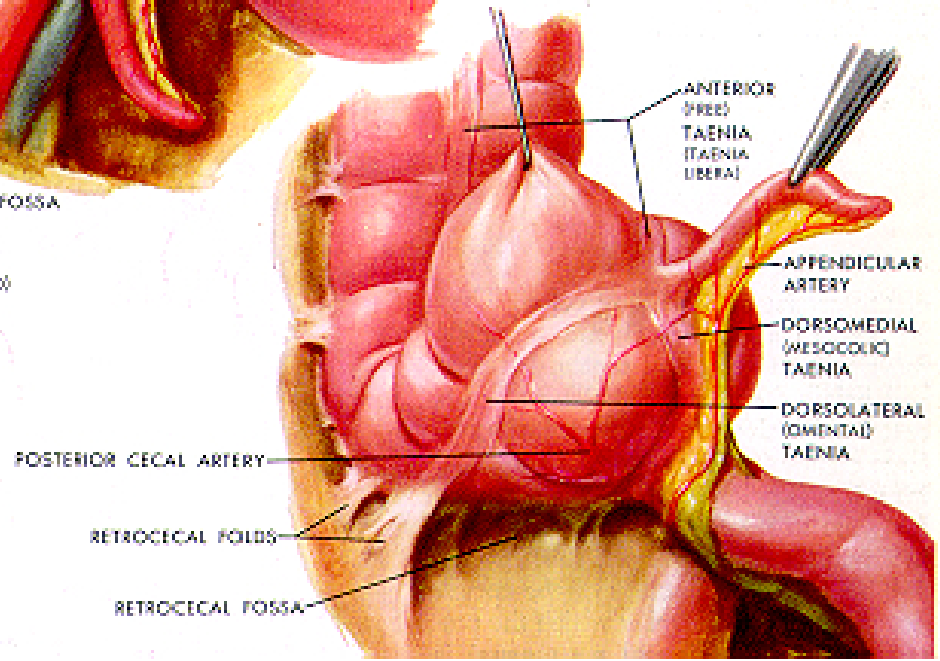
© BENJAMIN CUMMINGS

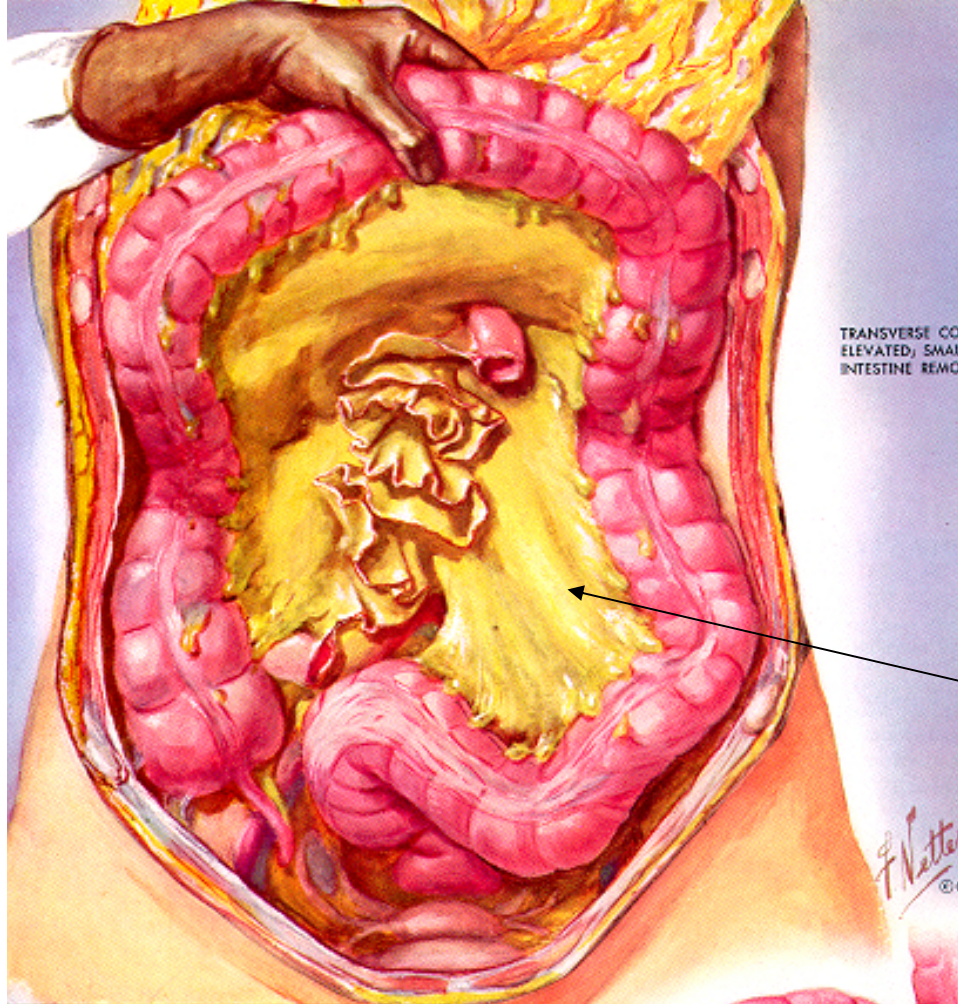


© BENJAMIN CUMMINGS



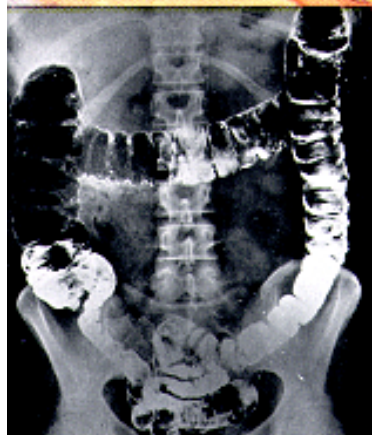
Mesocolon



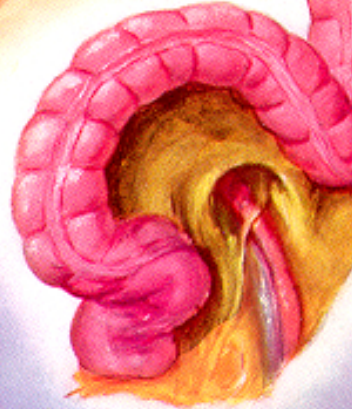

TRANSVERSE COLON
ELEVATED; SMALL
INTESTINE REMOVED

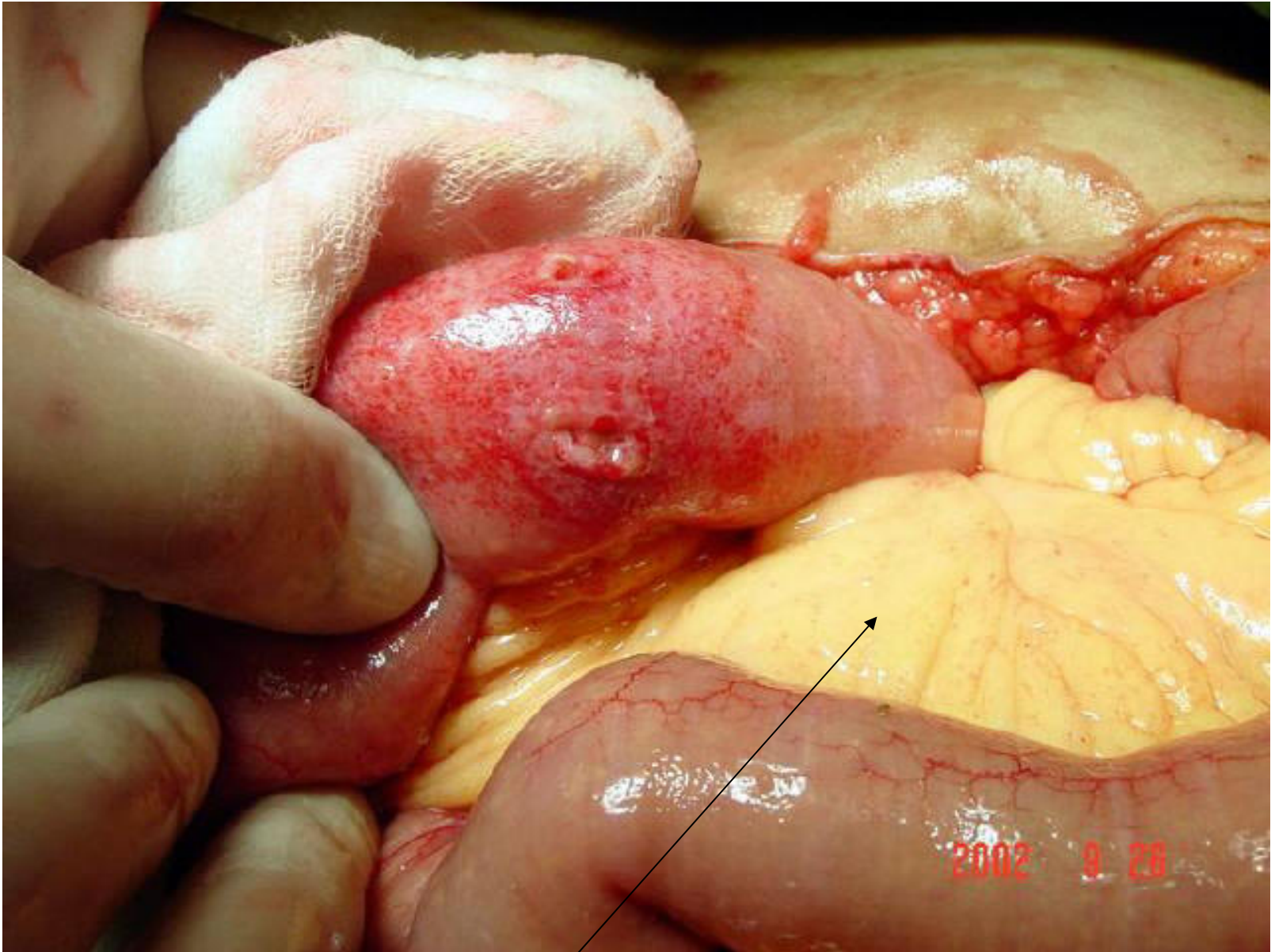
Mesocolon



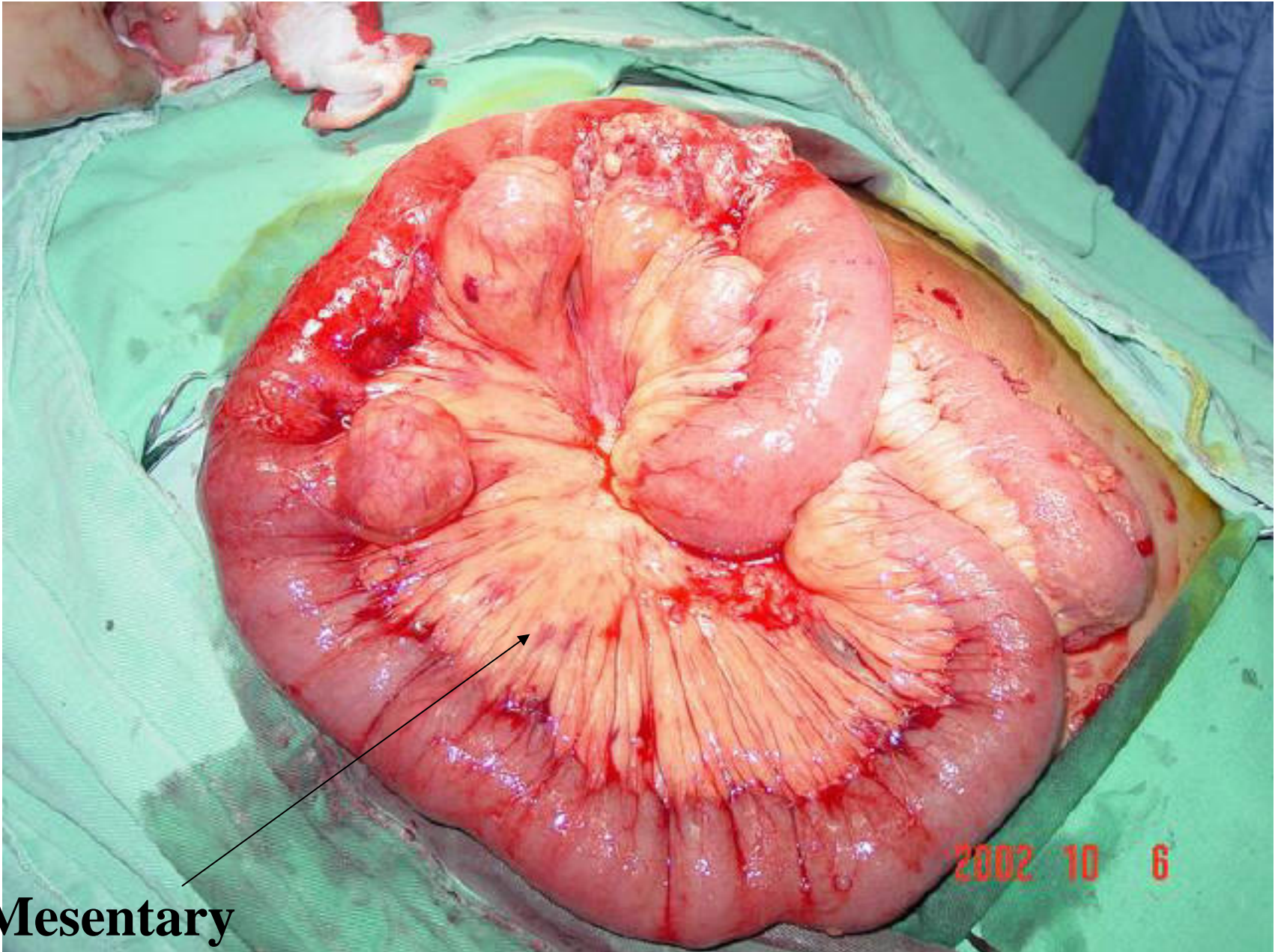
X-RAY OF COLON
(DOUBLE CONTRAST METHOD,
BARIUM AND AIR FILLING)



INTERSIGMOID FOSSA

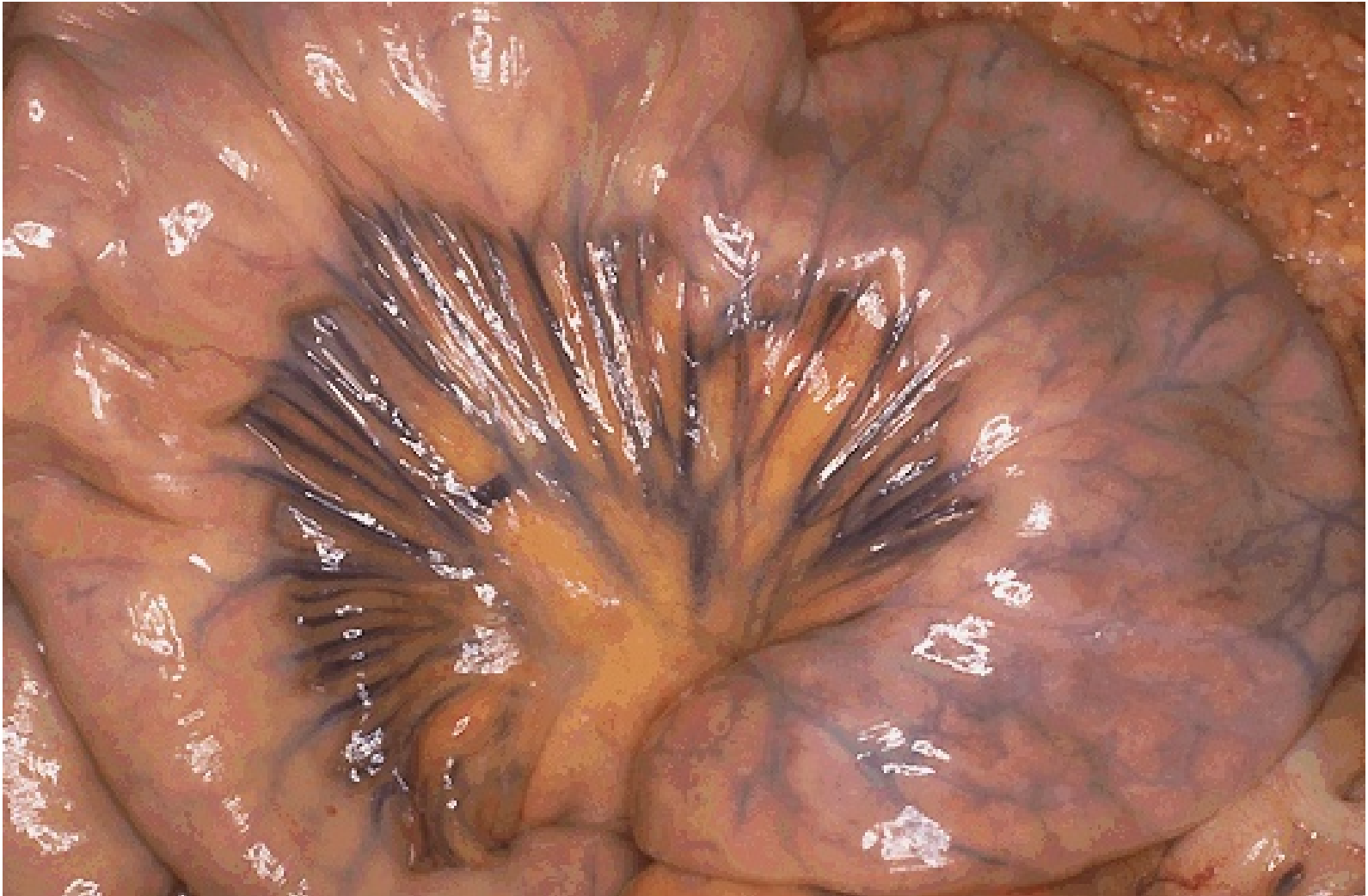


Mesentary

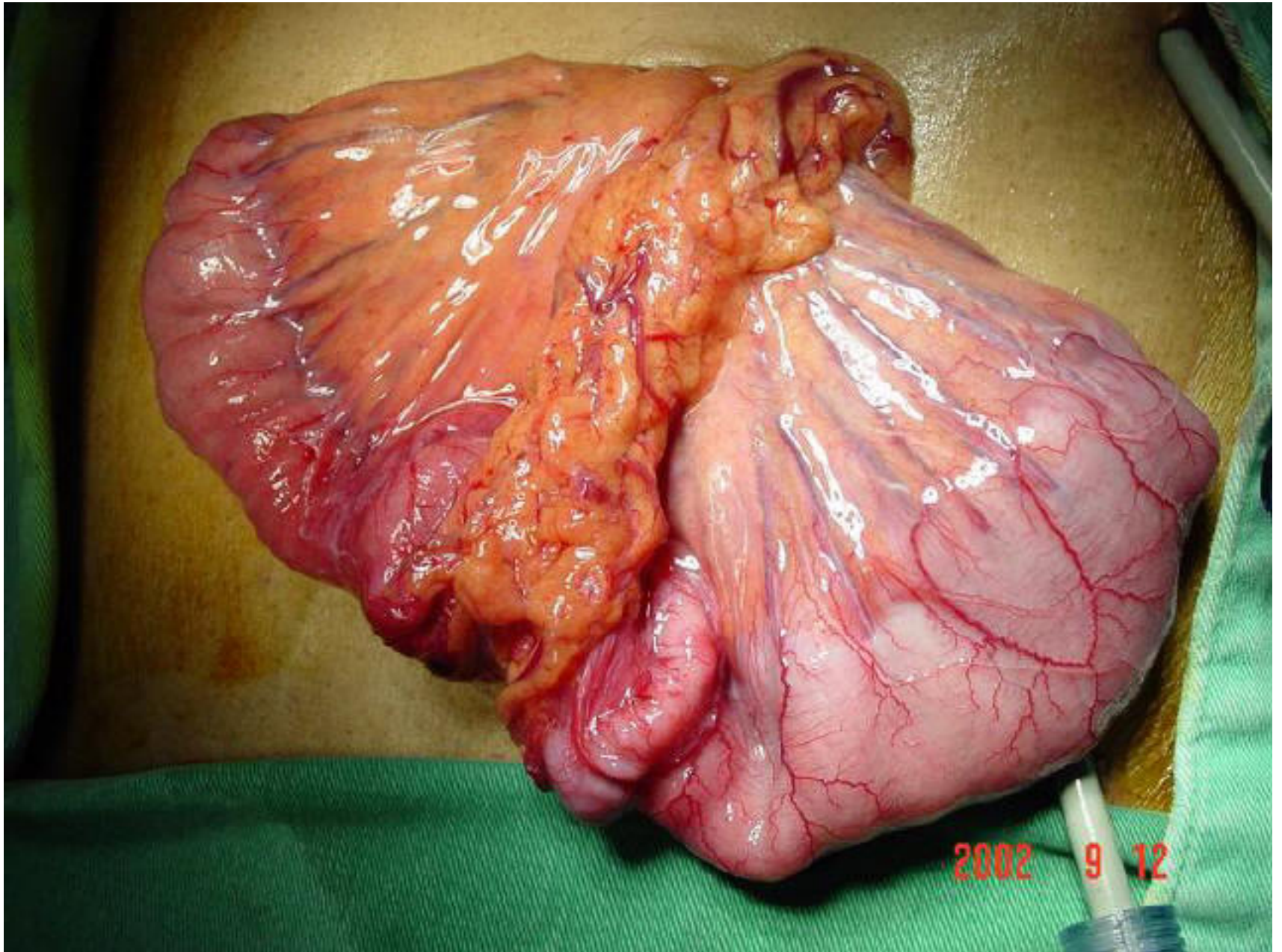


Mesentary

Mesentery

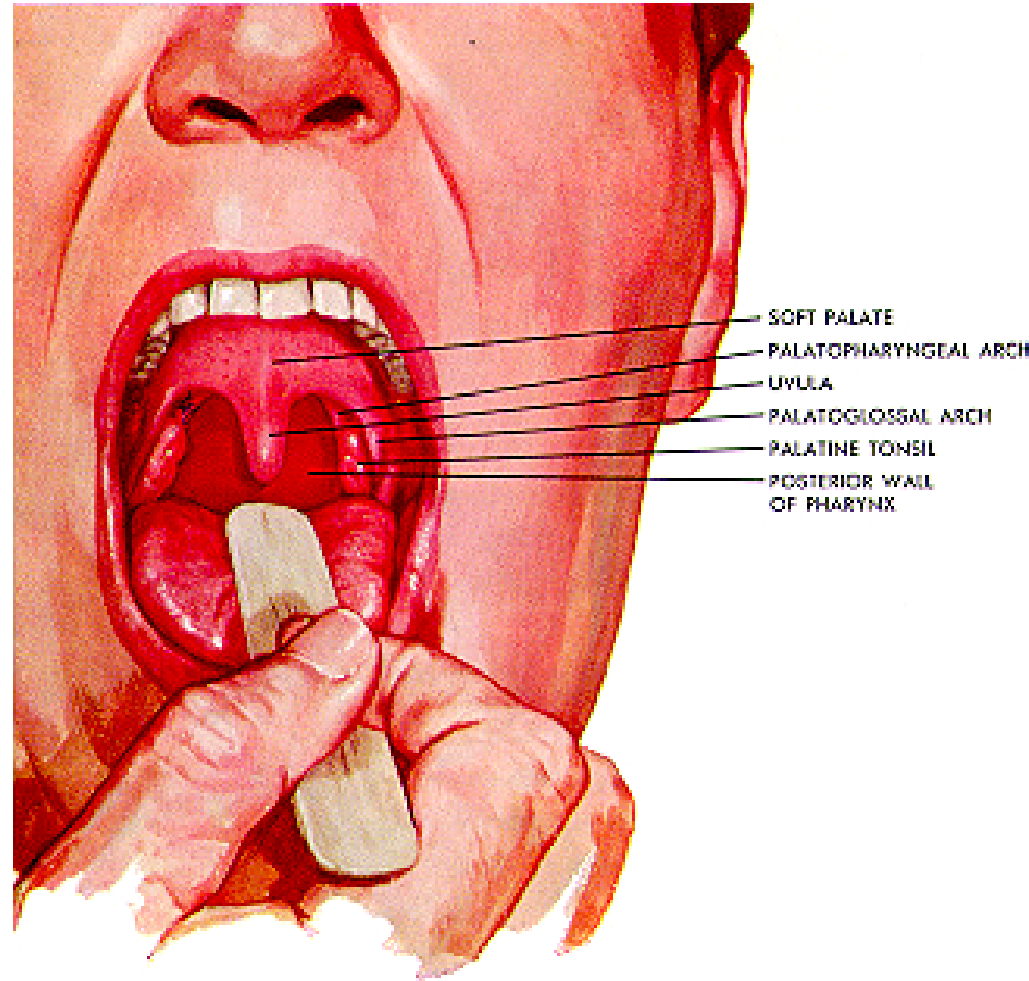


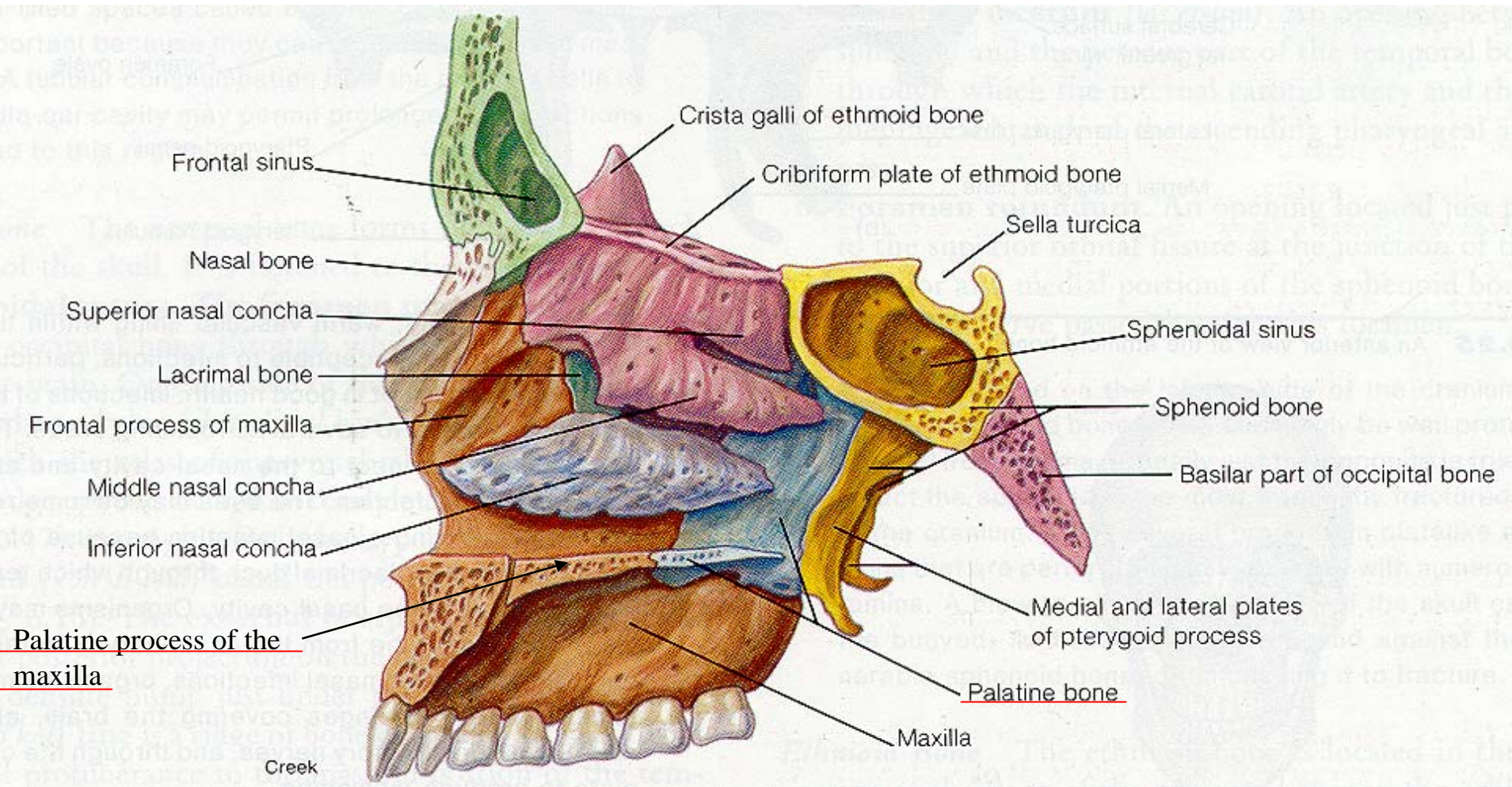
Seen here is a loop of bowel attached via the mesentery. Note the extent of the veins. Arteries run in the same location. Thus, there is an extensive anastomosing arterial blood supply to the bowel, making it more difficult to infarct. Also, the extensive venous drainage is incorporated into the portal venous system heading to the liver.



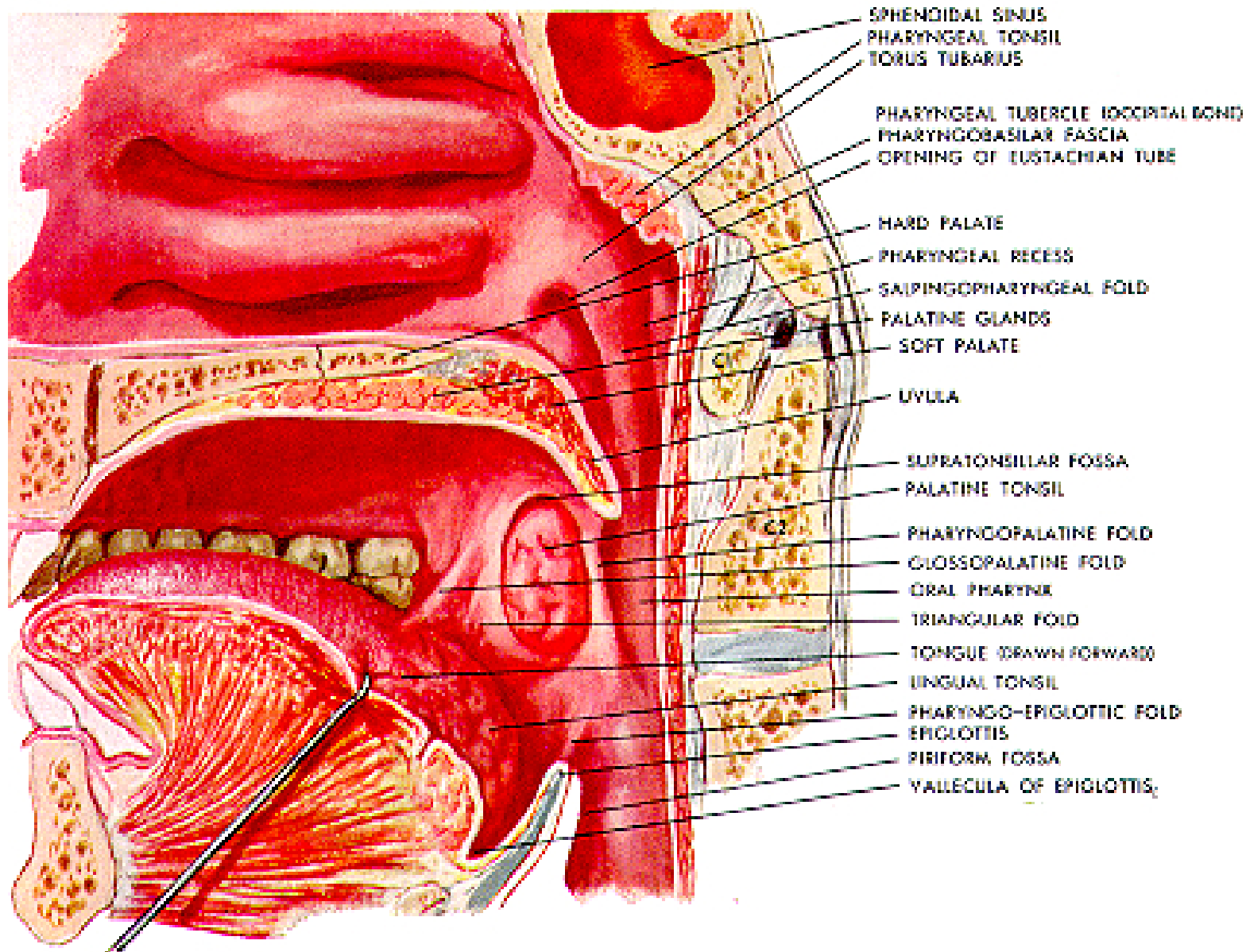
Mouth (Oral Cavity, Buccal Cavity)

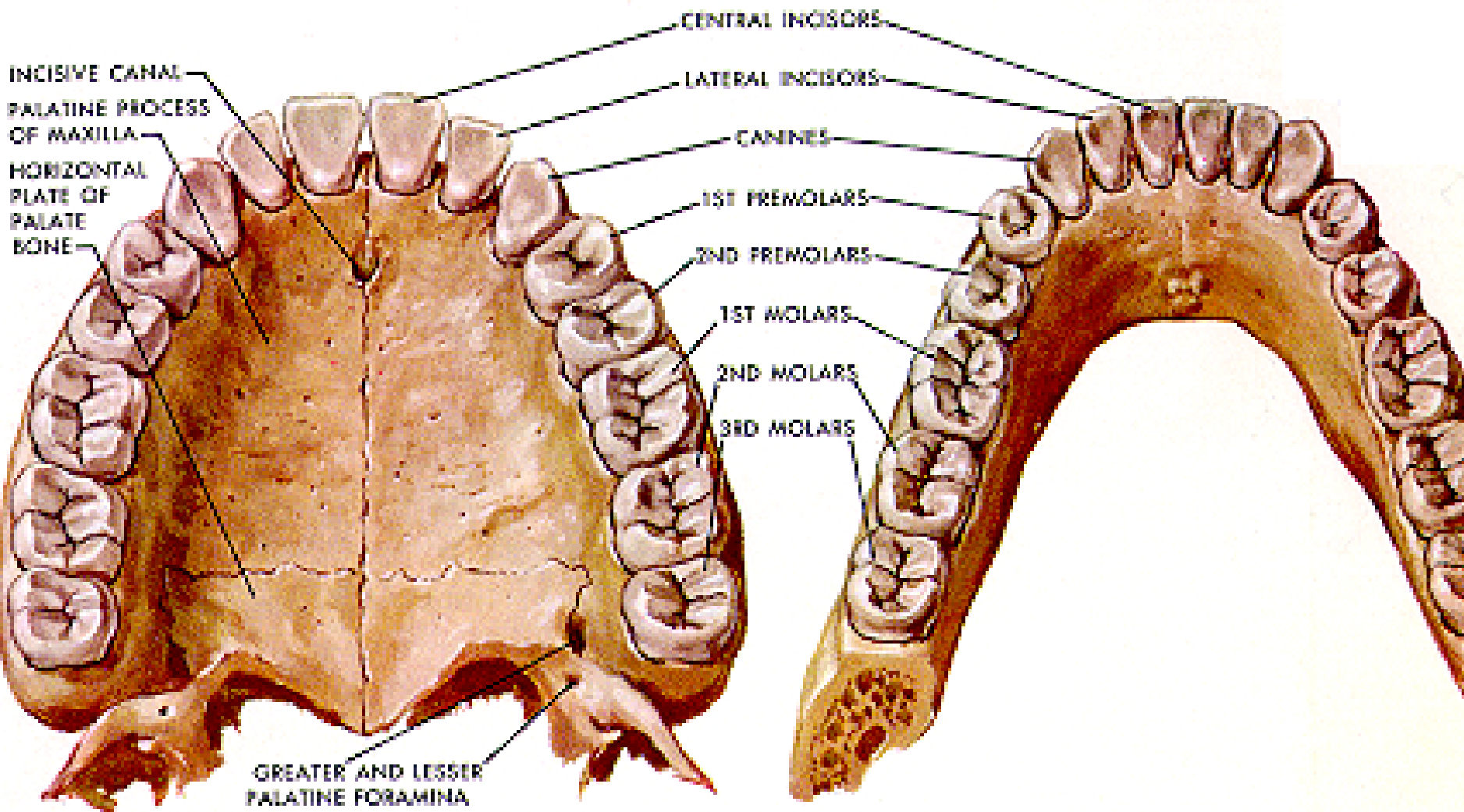
- **Lips**- assist in speech and help keep food in the mouth between the upper and lower teeth.
- **Hard palate**-the roof of the mouth that consist of the maxillae and palatine bones.
- **Soft palate**, a sheet of muscular tissue, compose the remaining posterior portion of the roof.
- **Uvula**- a soft tissue projection that hangs from the soft palate. When swallowing, the soft palate and uvula draws up preventing food from entering the nasal cavity.
- **Oral orifice**- anterior opening
- **Fauces**- the opening of the mouth that leads to the throat (oropharynx).
- Pair of muscular arches on each side of the oral cavity
 - **Palatoglossal arch**- anterior
 - **Palatopharyngeal arch**- posteiror





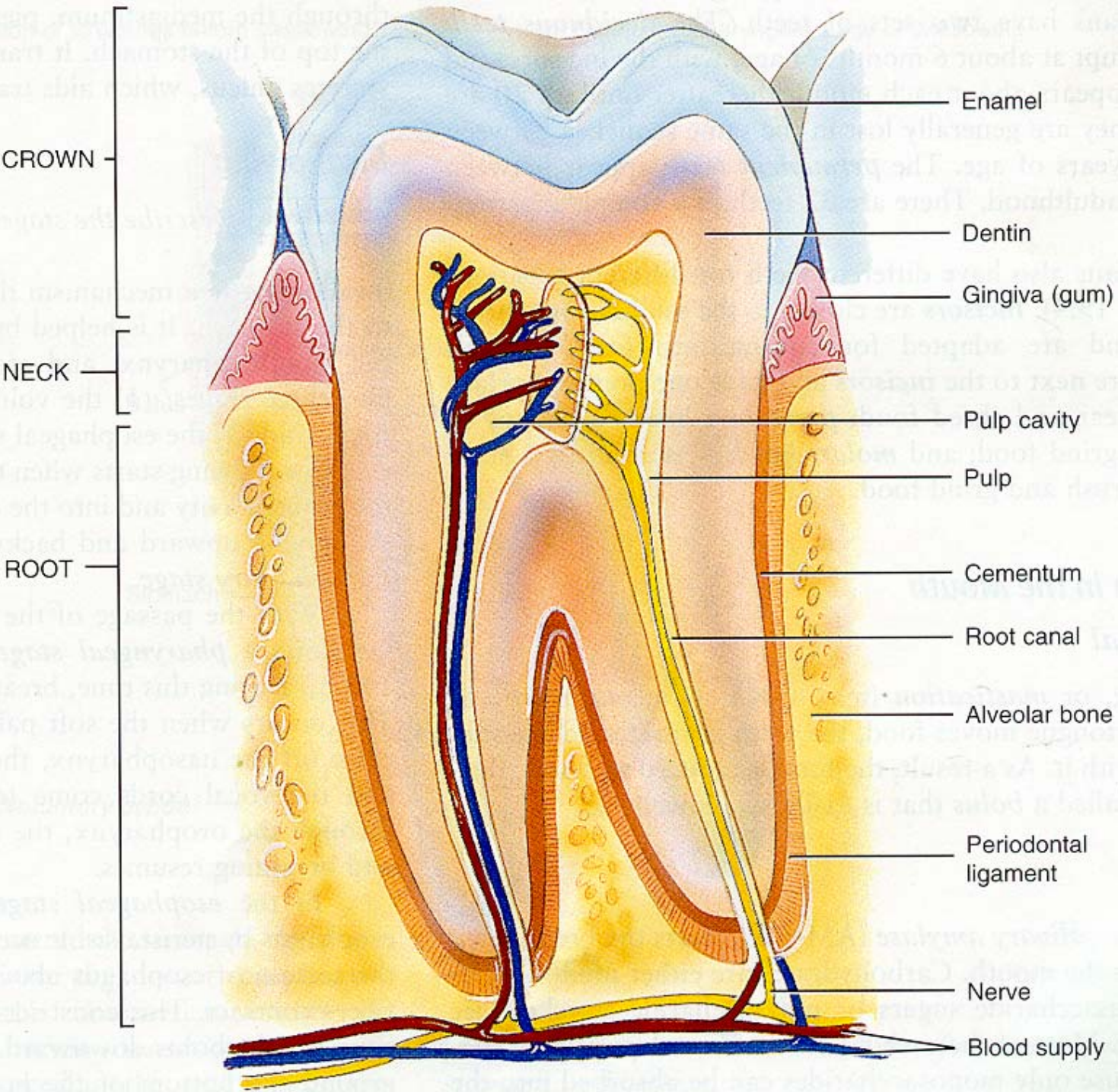
The hard palate is composed of the palatine process of the maxillary bone and the palatine bone.





UPPER PERMANENT TEETH

LOWER PERMANENT TEETH



The teeth are located in the bony socket of the mandible and maxillae.

Gingivae- gum

periodontal ligament- dense fibrous tissue that anchors the teeth to the bone.

Three parts of the teeth

•**Crown-** exposed portion

•**Root-** one to three projections embedded in the socket.

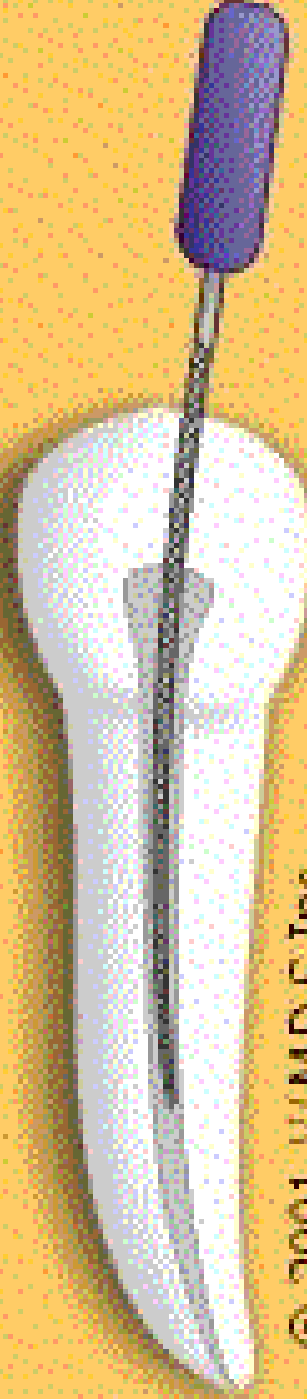
•**Neck-** the junction line of the crown and root.

Dentin- calcified connective tissue that comprises most of the teeth and gives it shape and rigidity.

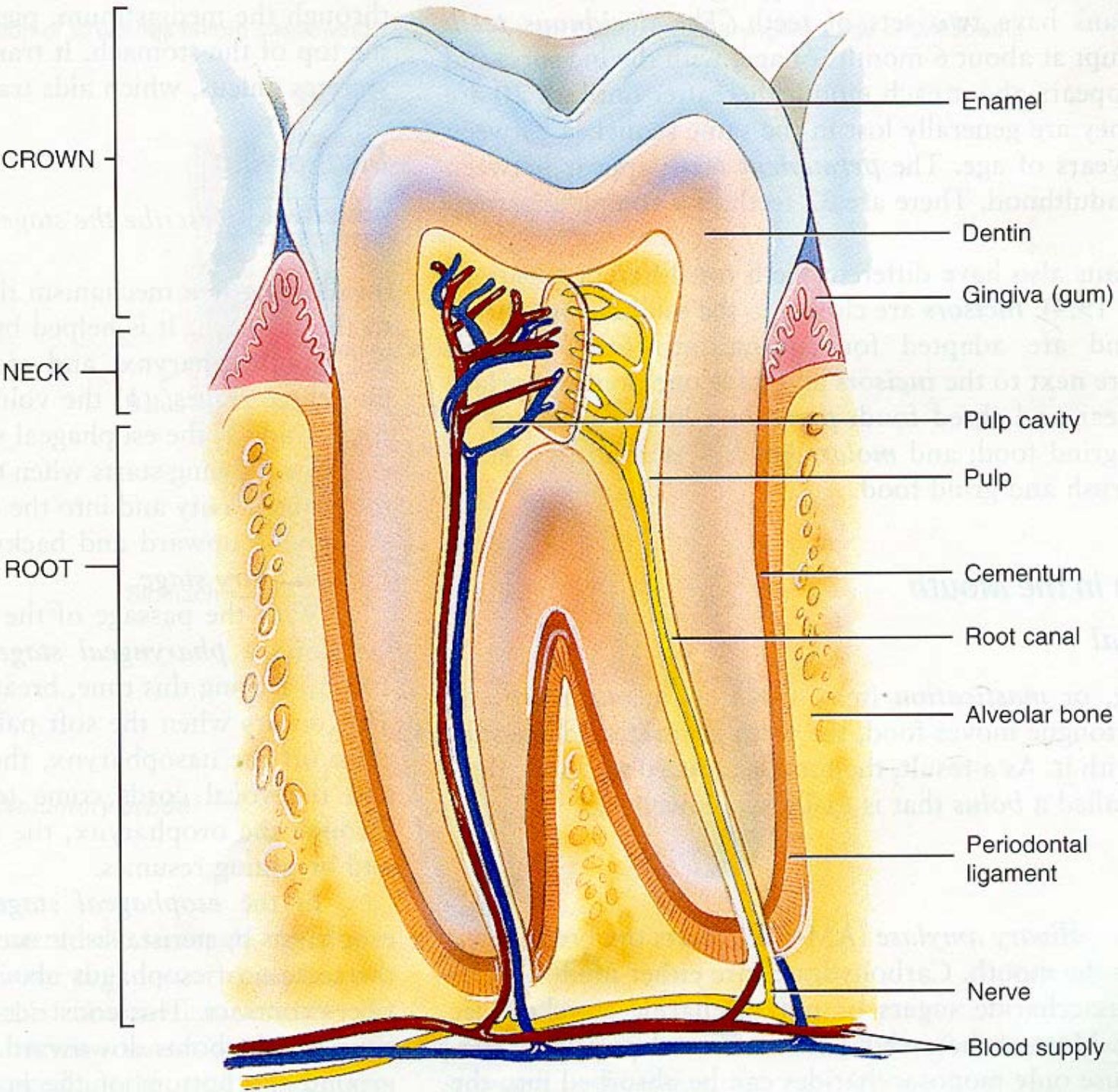
Pulp- connective tissue that contains blood vessels, nerves, and lymphatics.

Pulp cavity- a space in the crown filled with pulp.

Root canal- narrow extensions of the pulp cavity that run through the root of the tooth through which vessels and nerves course.

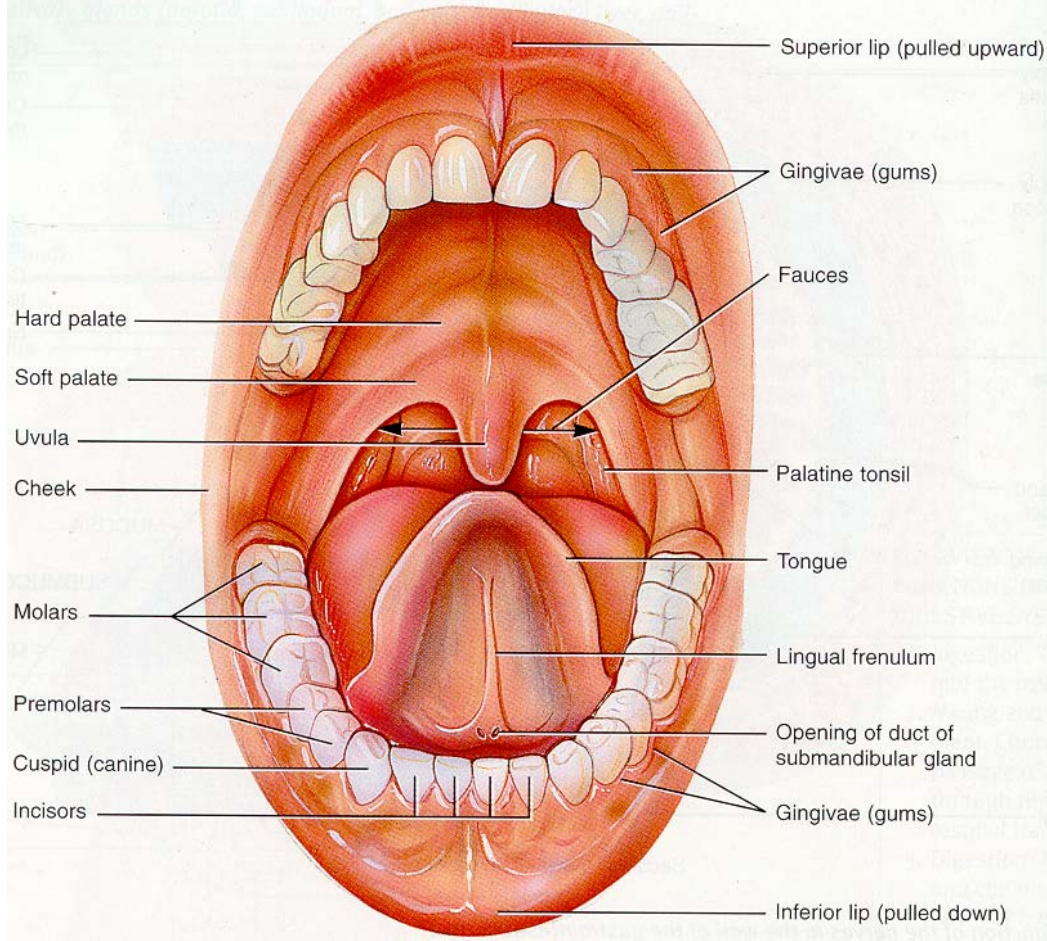


© 2001 WMD S, Inc.
Animated-Teeth.com



Enamel- a bonelike substance that consist of promarily dense calcium phosphate and calcium carbonate. Is the hardest substance in the body. It protects the tooth against the wear of chooing and is a barrier against acids that would dissolve the dentin.

Cementum- a bone-like substance that covers the dentin of the root and attaches the root the the periodontal ligament.



Humans have two sets of teeth

Deciduous - first set that erupts at about 6 mo., starting with the incisors. They appear about one pair per month until all 20 are in.

Permanent- appear between 6 and adulthood. There are 32 permanent teeth.

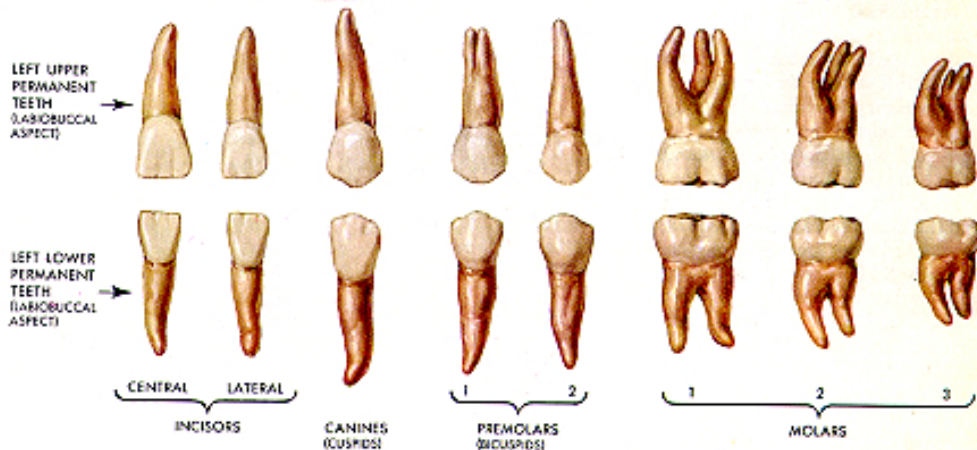
Functions of each kind of teeth

Incisors- (chisel shaped) cutting into food.

Cuspids (canine)- one pointed surface (cusp) to tear and shred.

Premolars- has two cusps to crush and grind.

Molars- have more than two blunt cusp to crush and grind.

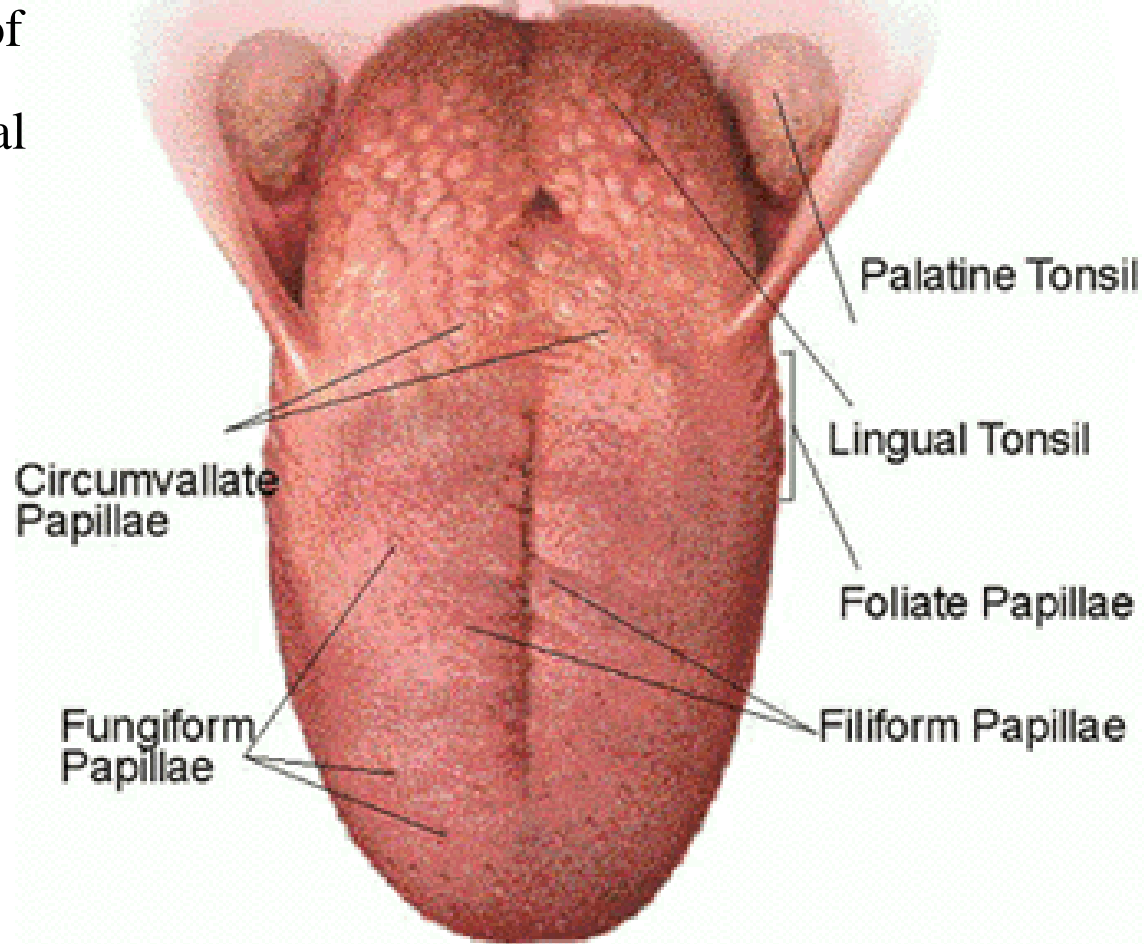


Endodontics- the branch of dentistry concerned with the prevention, diagnosis, and treatment of disease that affect the pulp, root, periodontal ligament, and alveolar bone

Orthodontics- Concerned with the prevention and correction of abnormally aligned teeth.

Tongue

- Muscular organ consisting of connective tissue and interlacing bundles of skeletal muscle fibers covered by a mucus membrane.
- The distribution and random orientation of individual skeletal muscle fibers allows increased movement during chewing, swallowing, and speaking
- Epithelium on the ventral surface is smooth
- Dorsal surface is rough because of numerous elevations or projections called papillae
- 4 types of papillae
 - Filiform
 - Foliate
 - Fungiform
 - vallate

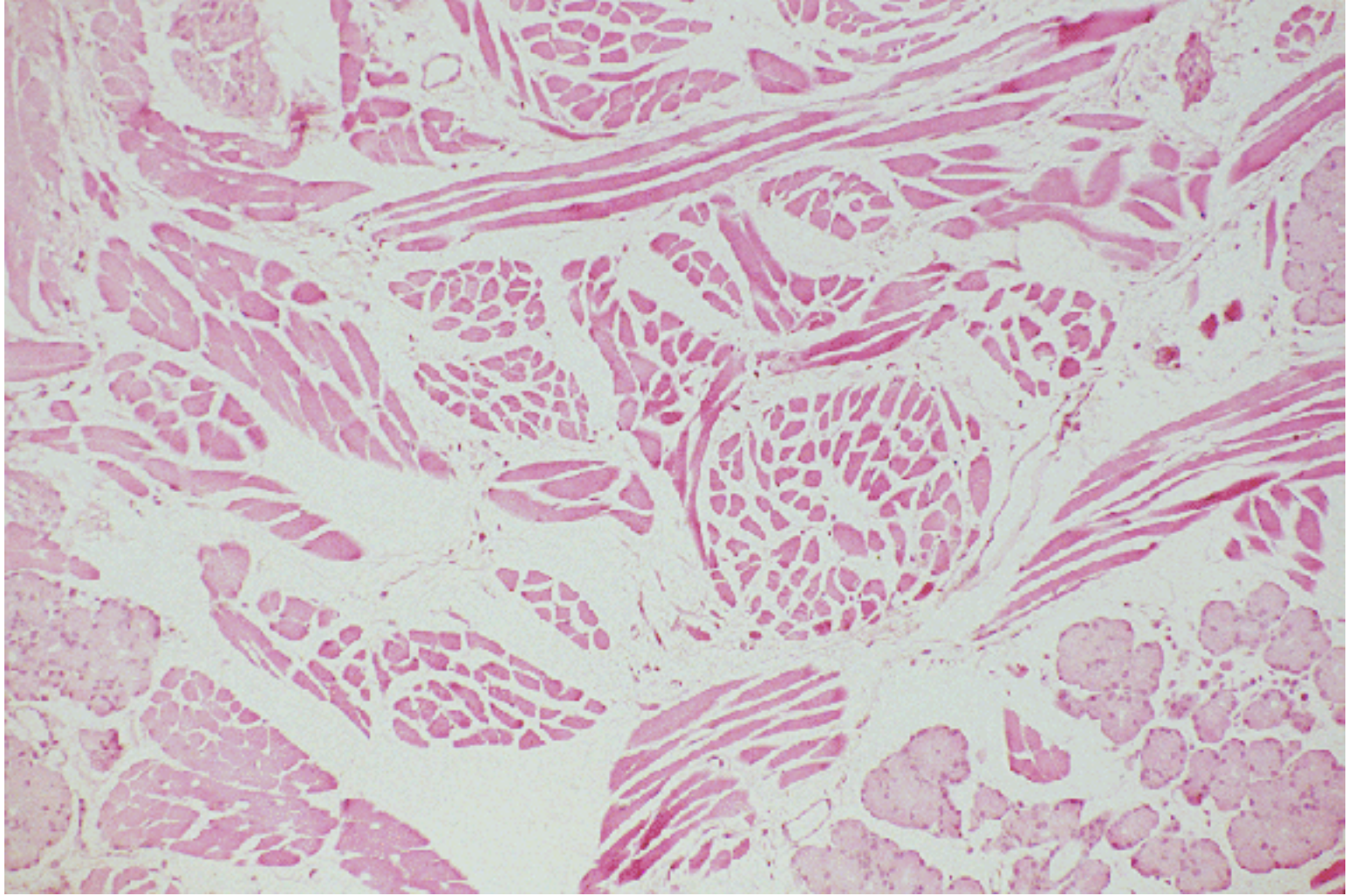


Body- anterior 2/3 of tongue

Root- posterior 1/3 of tongue

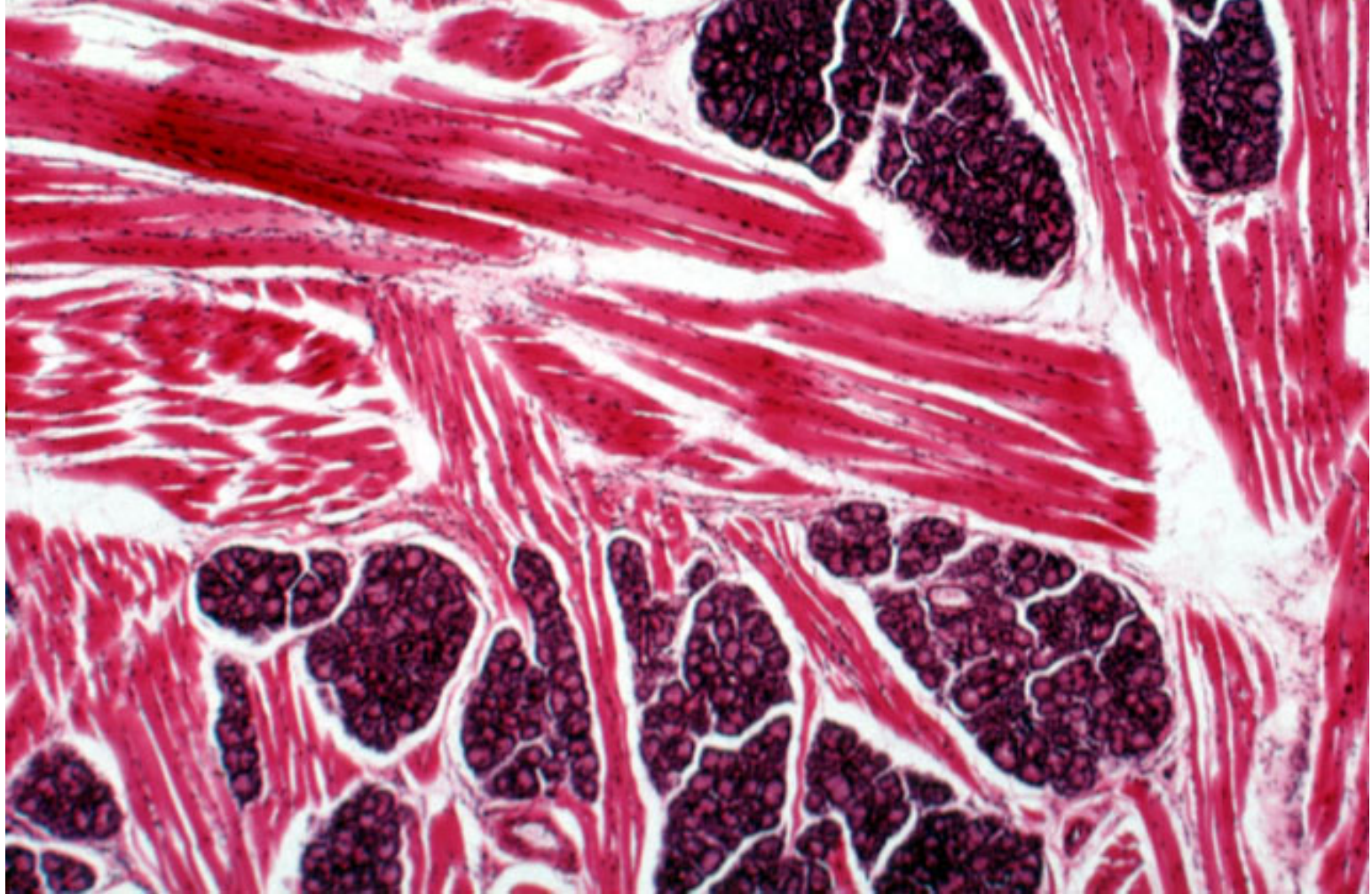
Tongue

- Maneuvers the food for chewing, shapes it into a round mass (bolus), and moves it to the back of the mouth for swallowing.
- **Frenulum**- a fold of mucous membrane in the midline of the undersurface of the tongue that limits its posterior movement.
- **Papillae**- projections on the side and posterior surface of the tongue, some of which contain taste buds.



Tongue

- Skeletal muscle running three different ways

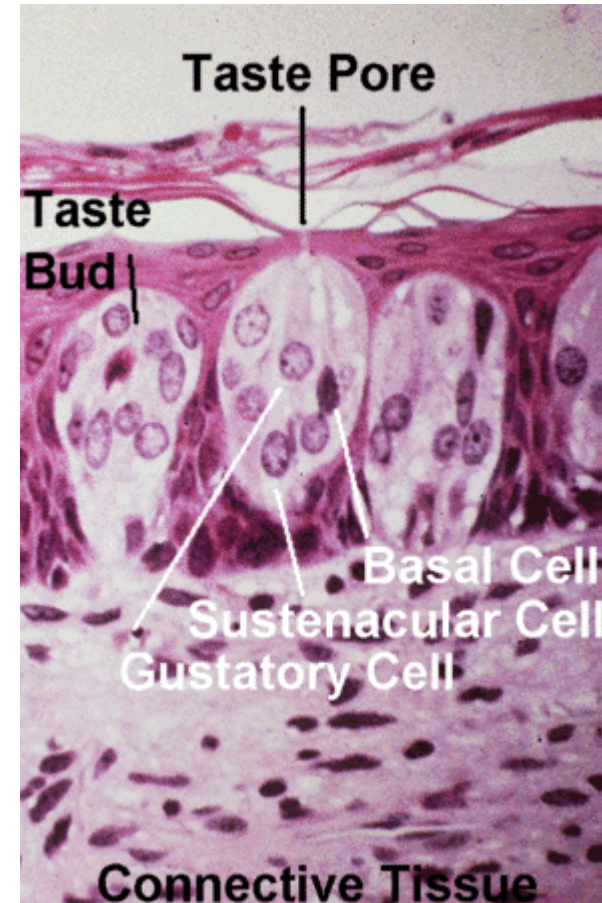


- **von Ebner's Glands & Skeletal Muscle Fibers**
Notice the tri-directional arrangement of the muscle fibers. H&E, 40x

Taste (Gustation)

- A sensation that results from the action of chemicals on the **taste buds**
 - About 4,000 taste buds located on the tongue, cheeks, soft palate, pharynx, and epiglottis

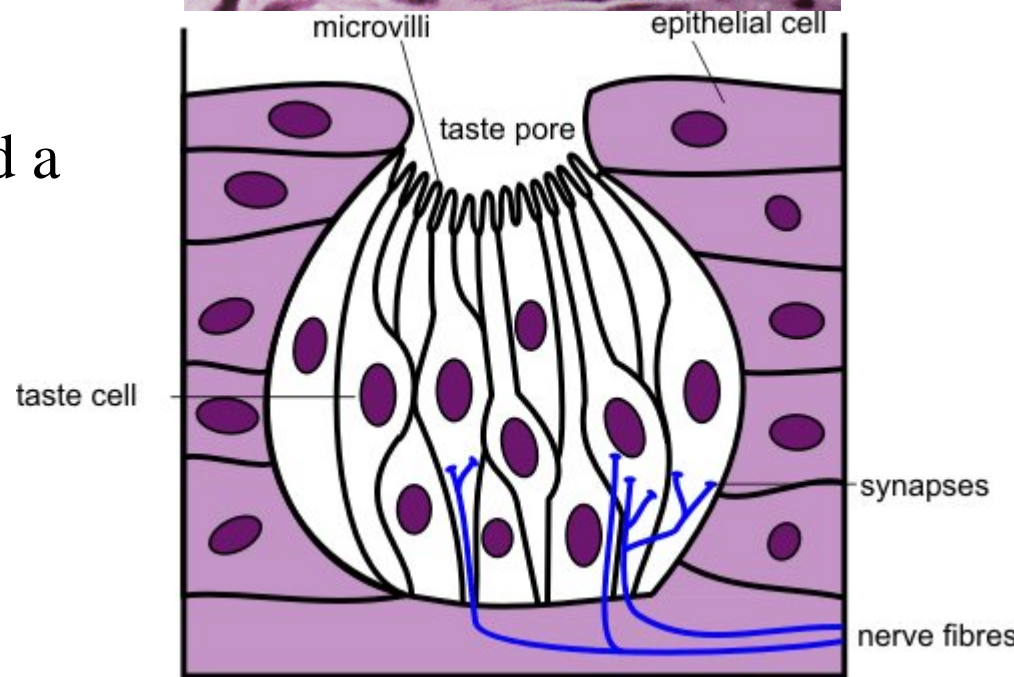
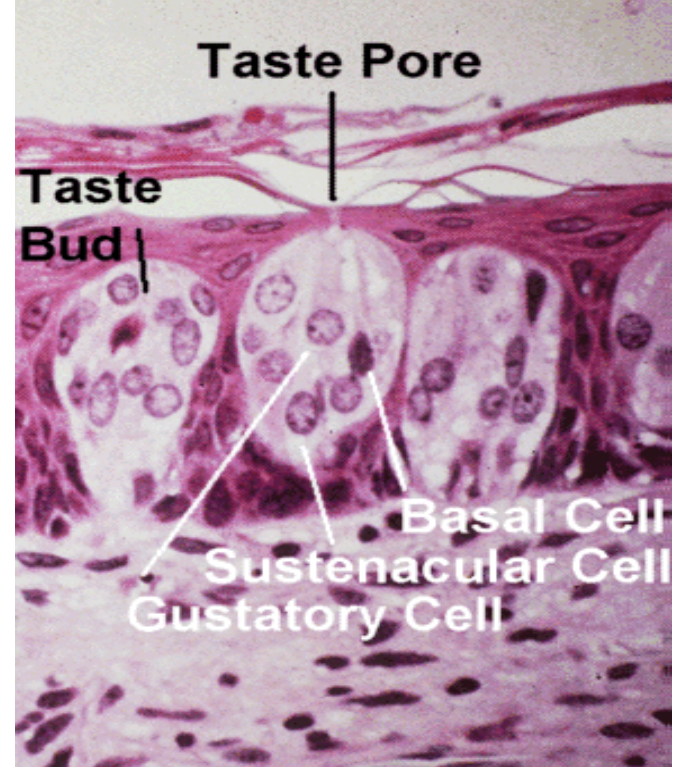
Lemon shaped groups of 40 to 60 cells



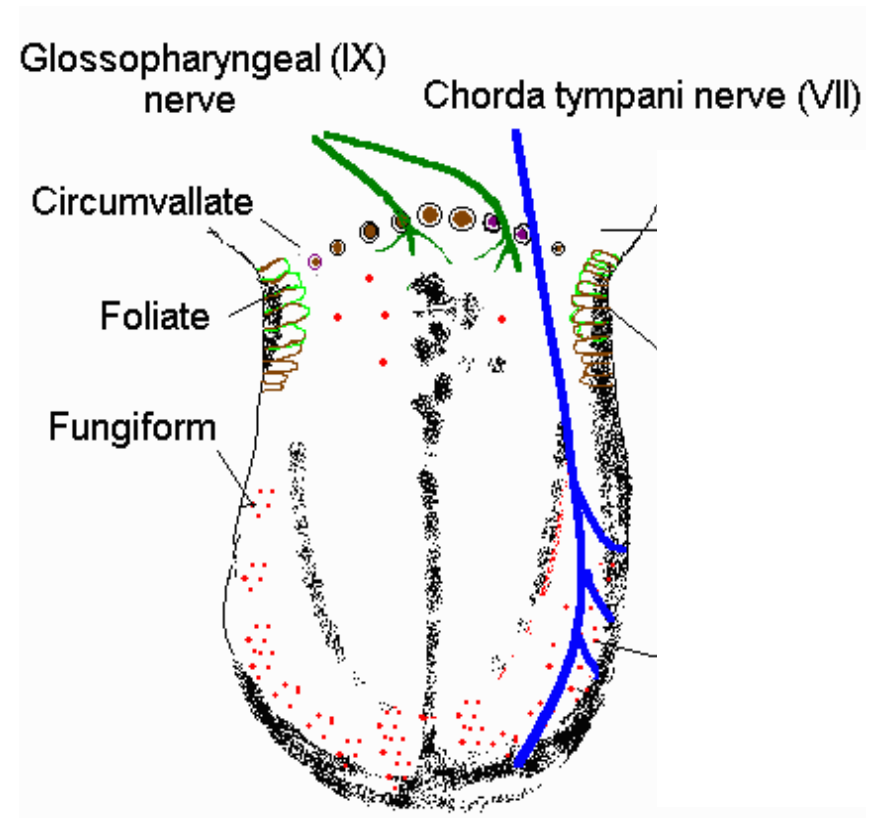
Taste Buds

Consist of three kinds of cells

- **Taste (gustatory) cells**
 - Are epithelial cells , not neurons
 - Banana shaped and have a tuft of apical microvilli called **taste hairs** that serve as receptor surface for taste molecules
 - Hairs project into a pit called a **taste pore** on the epithelial surface of the tongue
 - Cells synapse with sensory fibers at their base

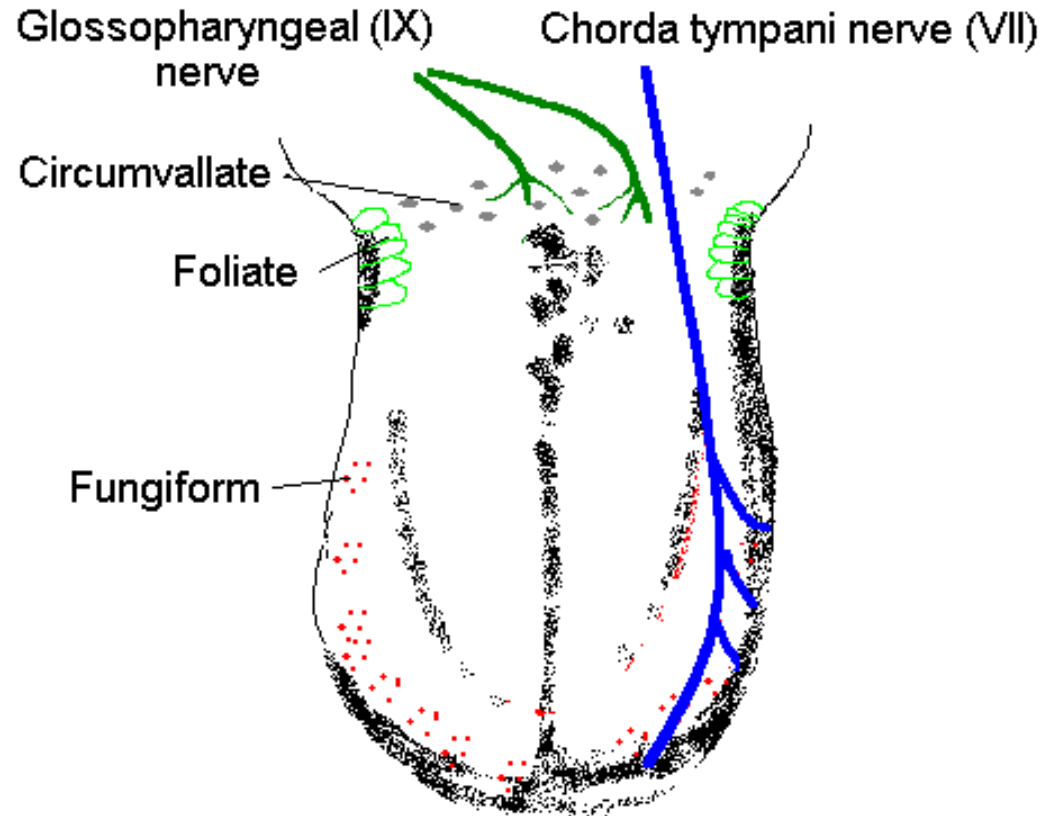


- Taste is conveyed to the brain through three different nerves (the cranial nerves VII (*N. facialis*), IX (*N. glossopharyngeus*), and X (*N. vagus*)).

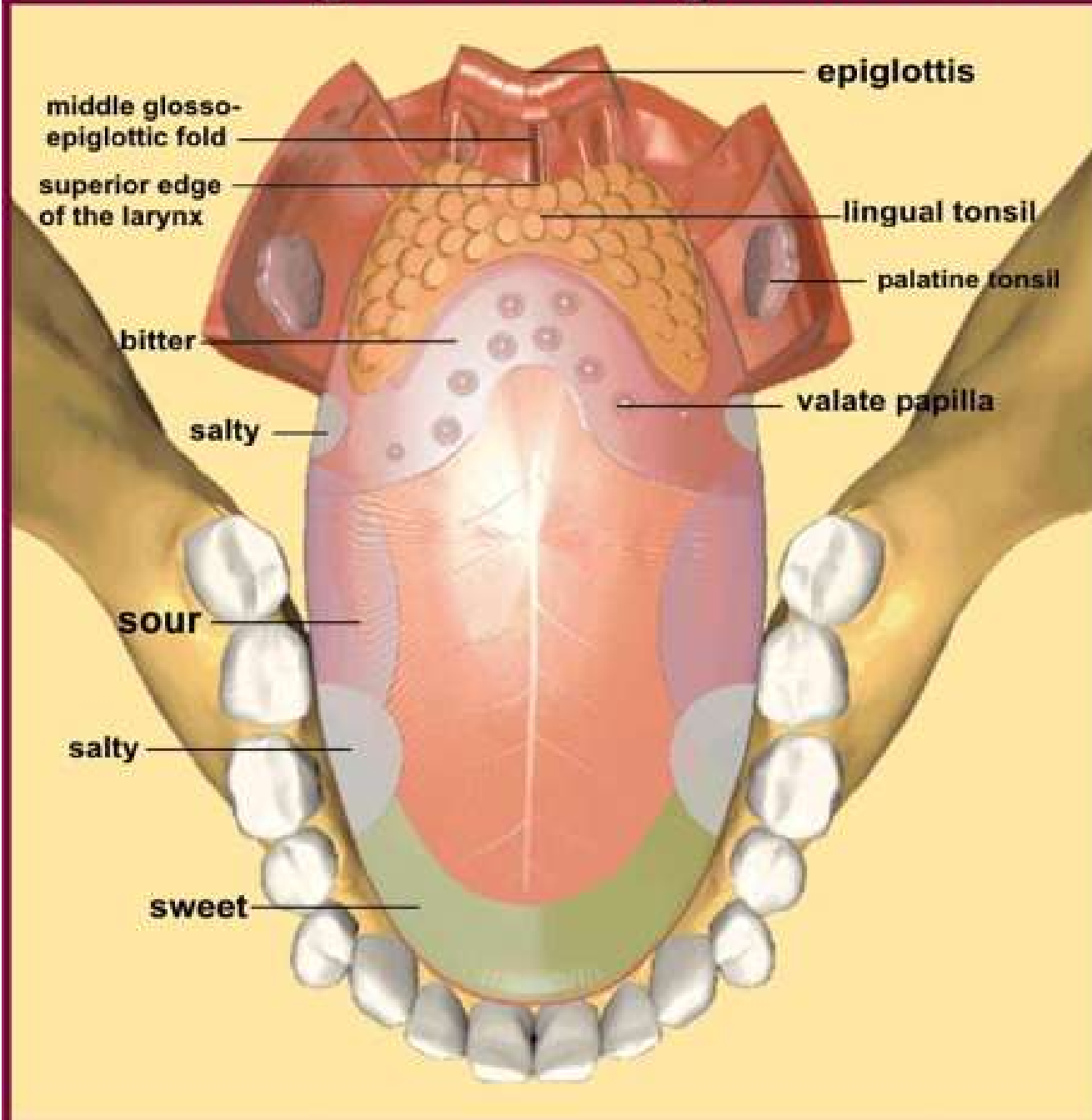


- Glossopalatine
 - *origin*, under surface of soft palate; *insertion*, side of tongue; *innervation*, pharyngeal plexus of vagus; *action*, **elevates tongue, constricts fauces.**
- levator veli palatine
 - *origin*, apex of petrous portion of temporal bone and cartilaginous part of auditory tube; *insertion*, aponeurosis of soft palate; *innervation*, pharyngeal plexus of vagus; *action*, **raises soft palate.**

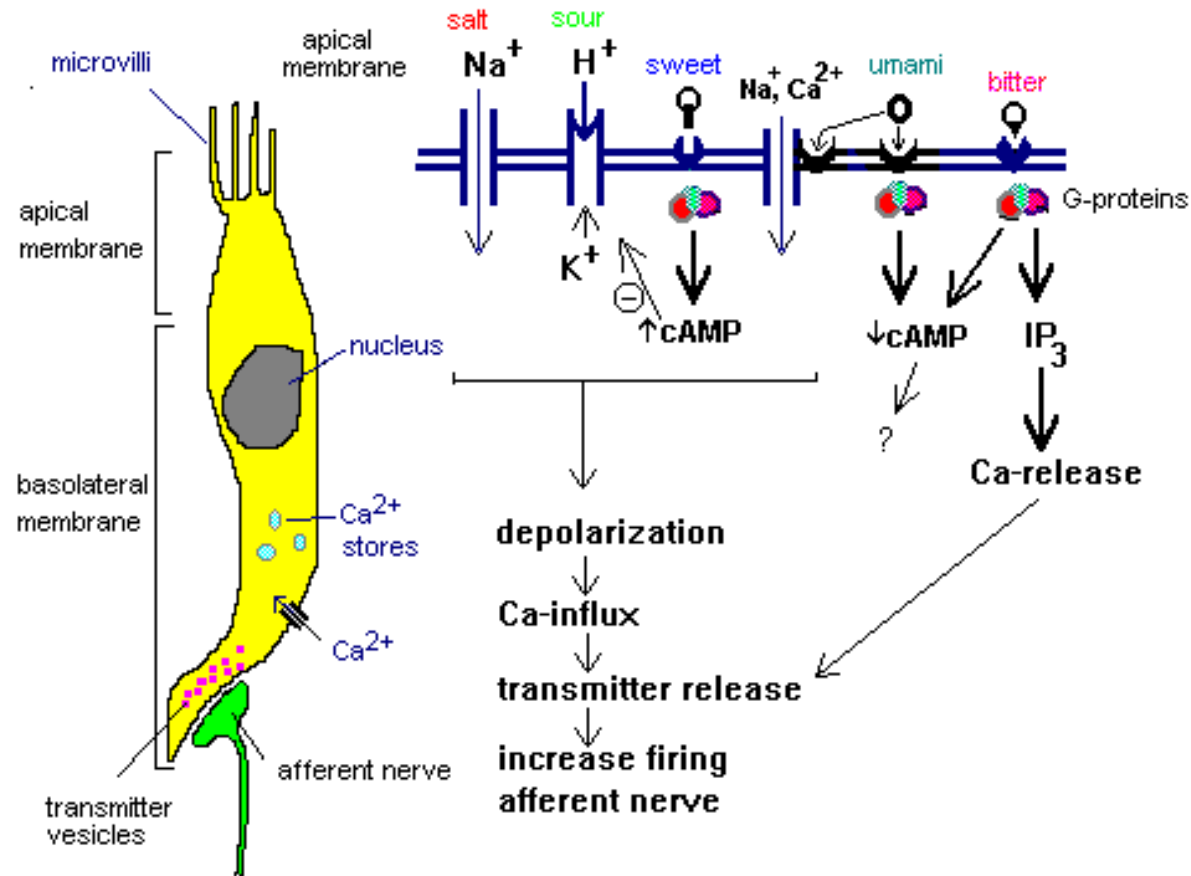
- Primary gustatory fibres synapse centrally in the medulla (in a thin line of cells called the nucleus of the solitary tract).
- From there the information is relayed
 - (1) to the somatosensory cortex for the conscious perception of taste and
 - (2) to the hypothalamus, amygdala and insula, giving the so-called "affective" component of taste.
 - This is responsible for the behavioural response, e.g. aversion, gastric secretion, feeding behaviour.



The Tongue - The Organ of Taste



Taste Receptor Cell

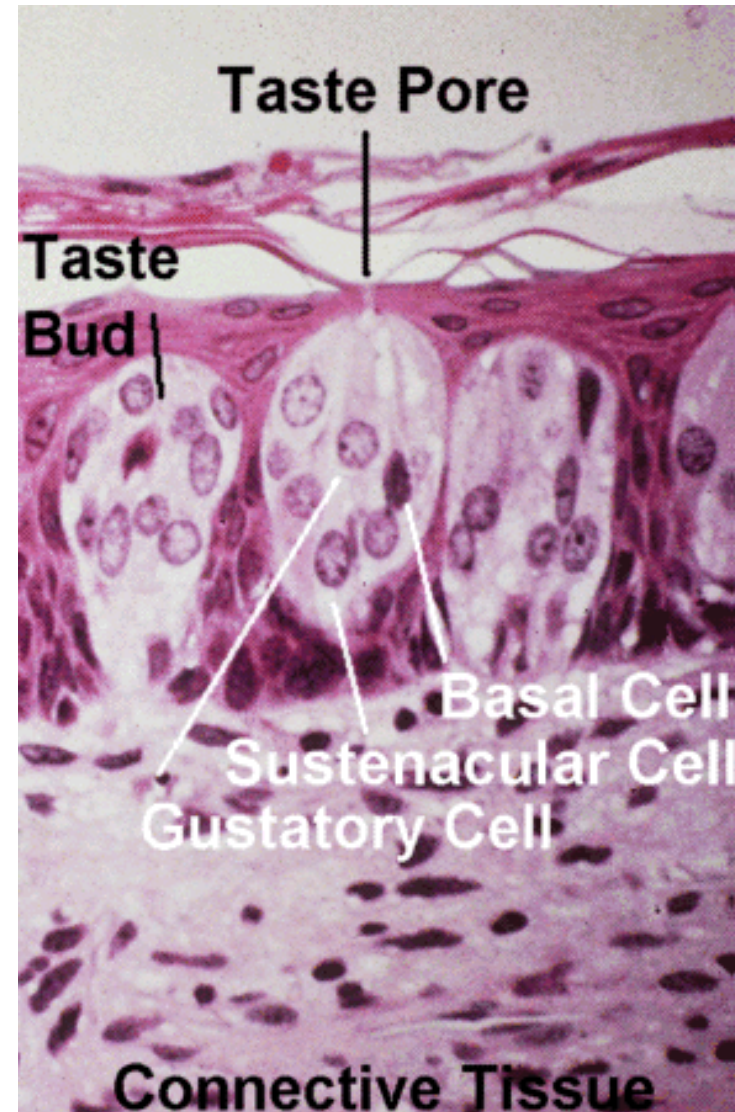


Umami taste-(meaty taste)
is the taste of certain amino acids

- Different taste stimulation causes different responses in the cell to cause nerve firing

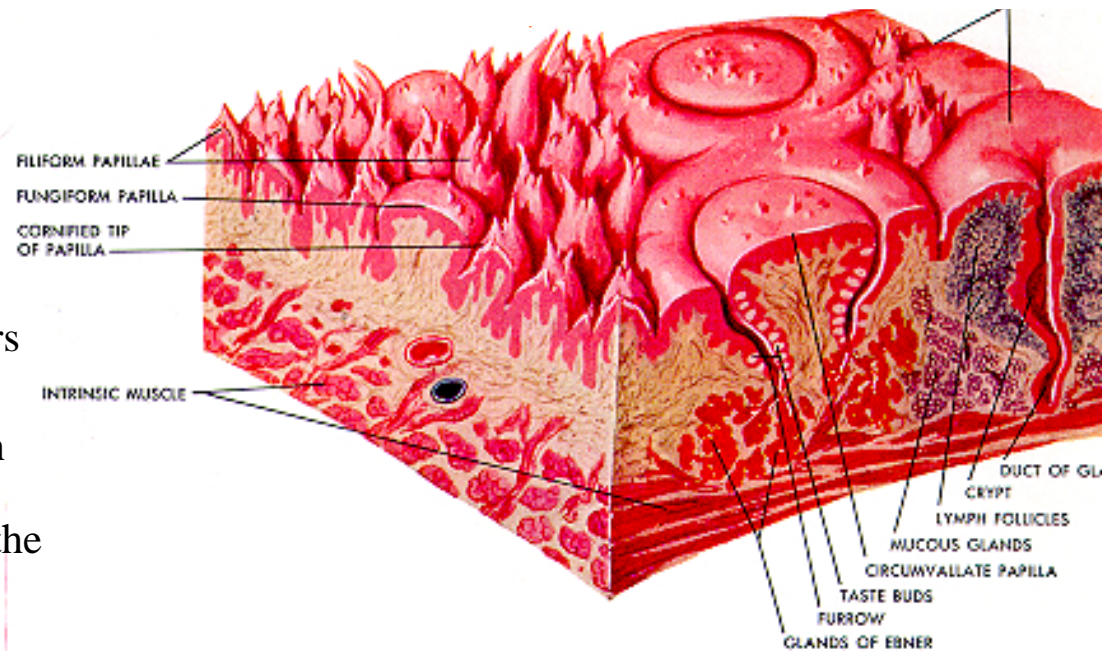
Taste Buds (cont)

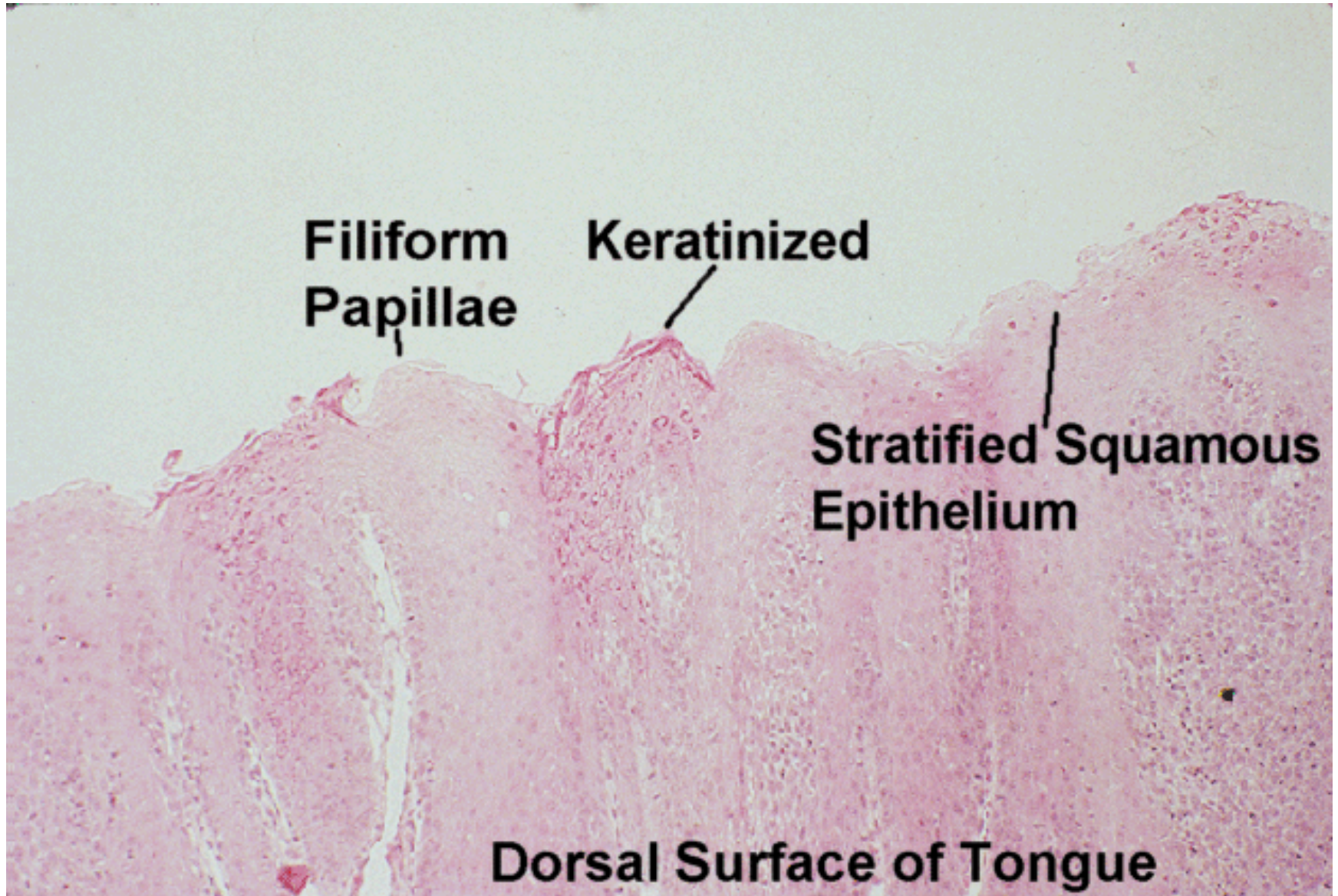
- **Supporting Cells**
 - contain microvilli, appear to secrete substances into lumen of taste bud.
- **Basal cells-**
 - Replace degenerated taste cells after their life span of 7 to 10 days



Lingual papillae

- **Filiform papillae-**
 - tiny spikes without taste buds
 - Helps appreciate the texture of food
- **Foliate papillae**
 - Weakly developed in humans
 - Form parallel ridges on the side of tongue, 2/3 of the way back from the tip
 - Most are degenerated by age 2-3 years
- **Fungiform papillae**
 - Mushroom shaped, located mainly on the apex
 - Are widely distributed, especially at the tip and sides of the tongue
- **Vallate (circumvallate) papillae**
 - Arranged in a V at the rear of the tongue
 - Each is surrounded by a deep circular trench
 - Are only 7-12 and contain 250 taste buds each



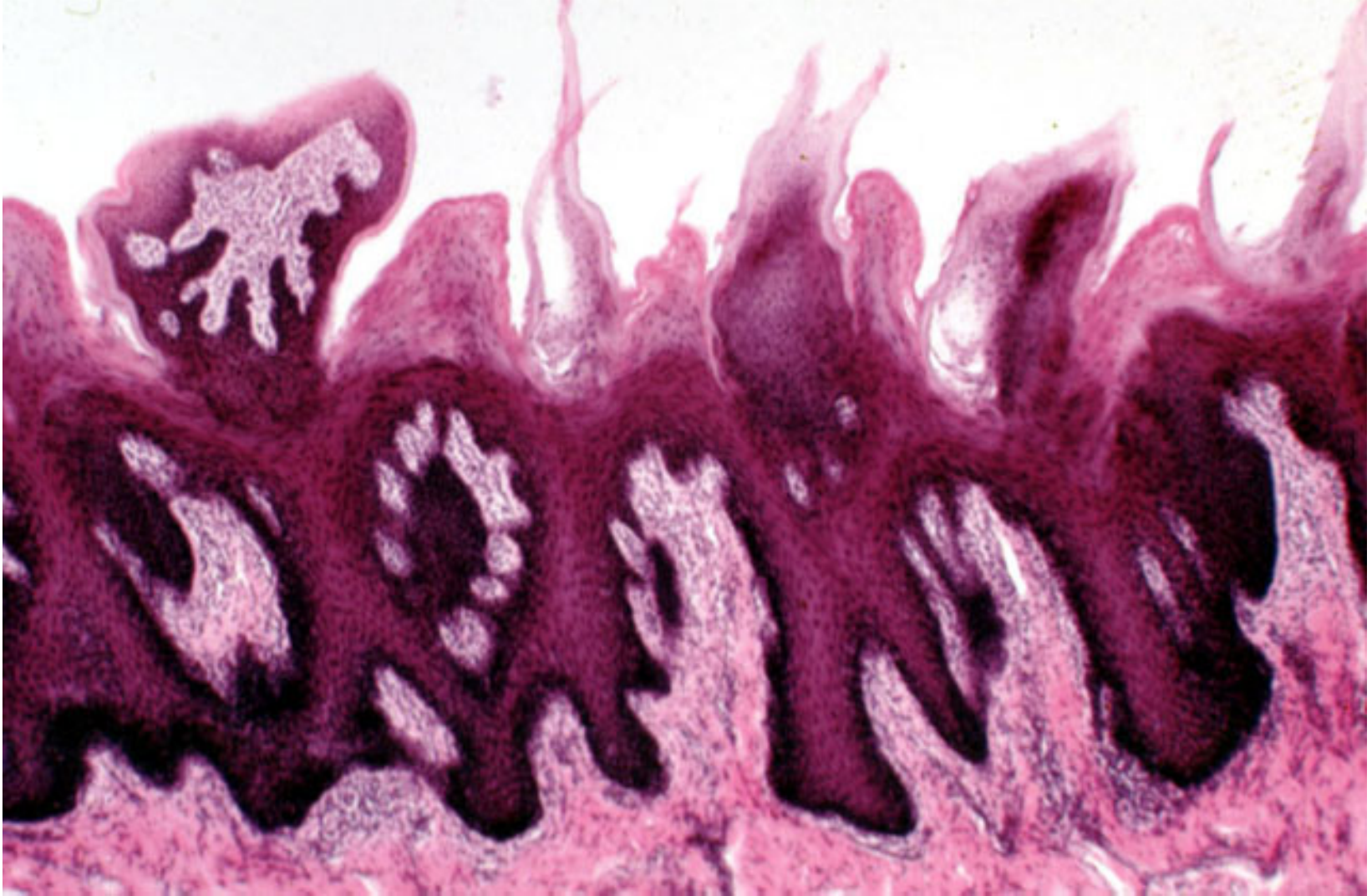


**Filiform
Papillae**

Keratinized

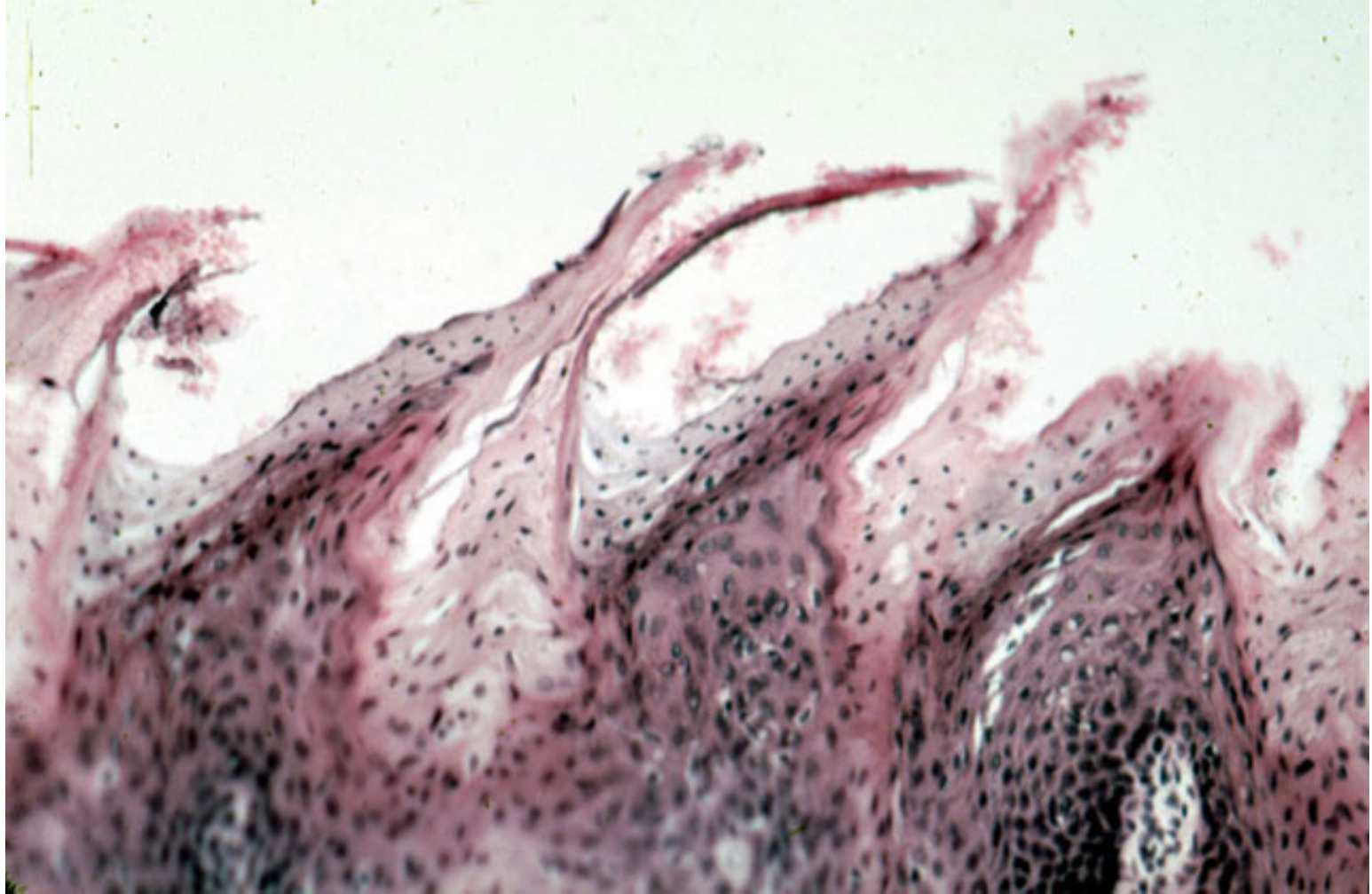
**Stratified Squamous
Epithelium**

Dorsal Surface of Tongue



- **Filiform & Fungiform Papillae**

The filiform papillae are roughly conical in shape. Each contains a small connective tissue core and a keratinized epithelial lining. The fungiform papillae are dome-shaped and contain a core of connective tissue with a rich vascular component. The lining epithelium is relatively thin and is generally thinly keratinized. H&E, 40x

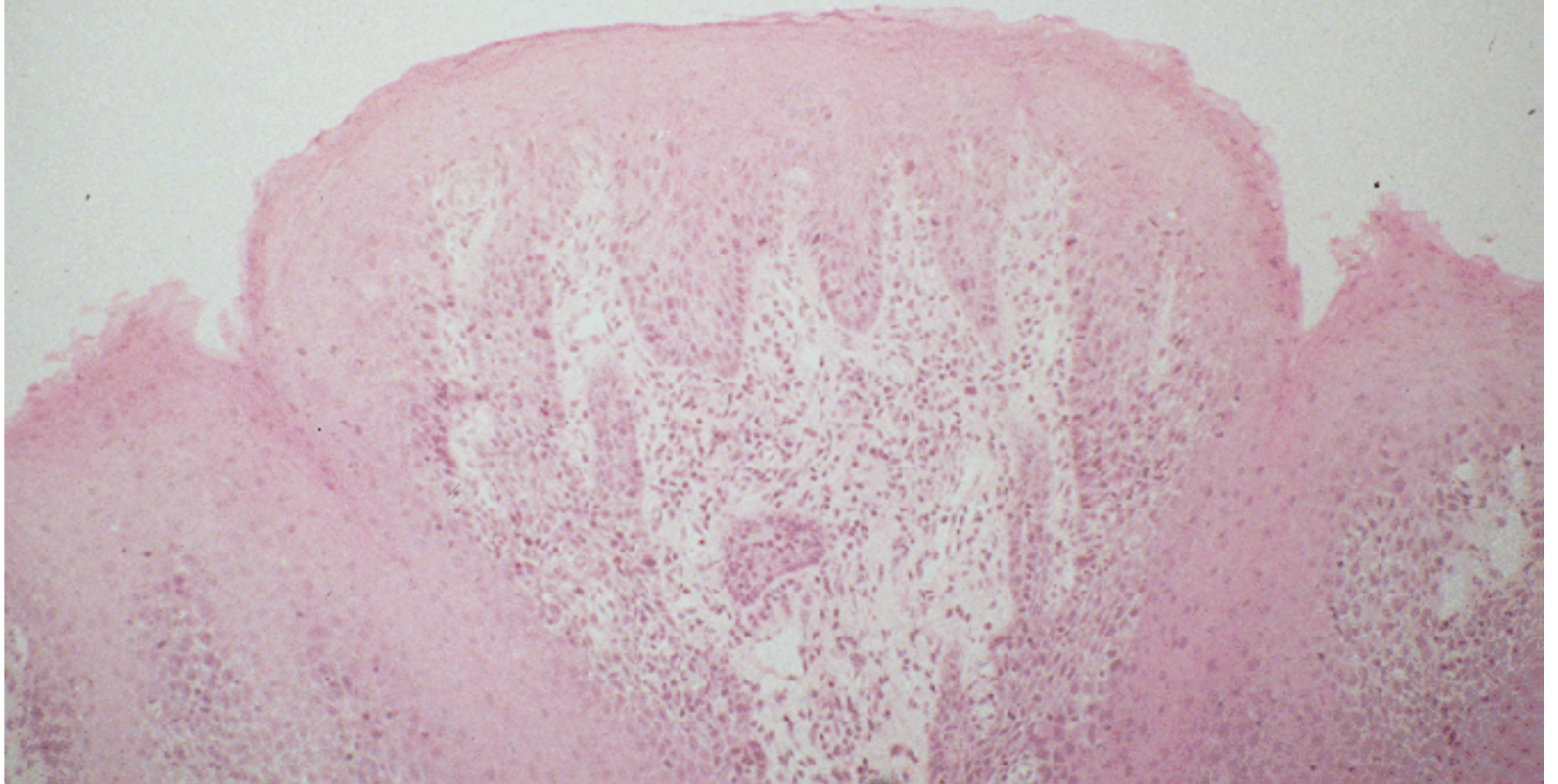


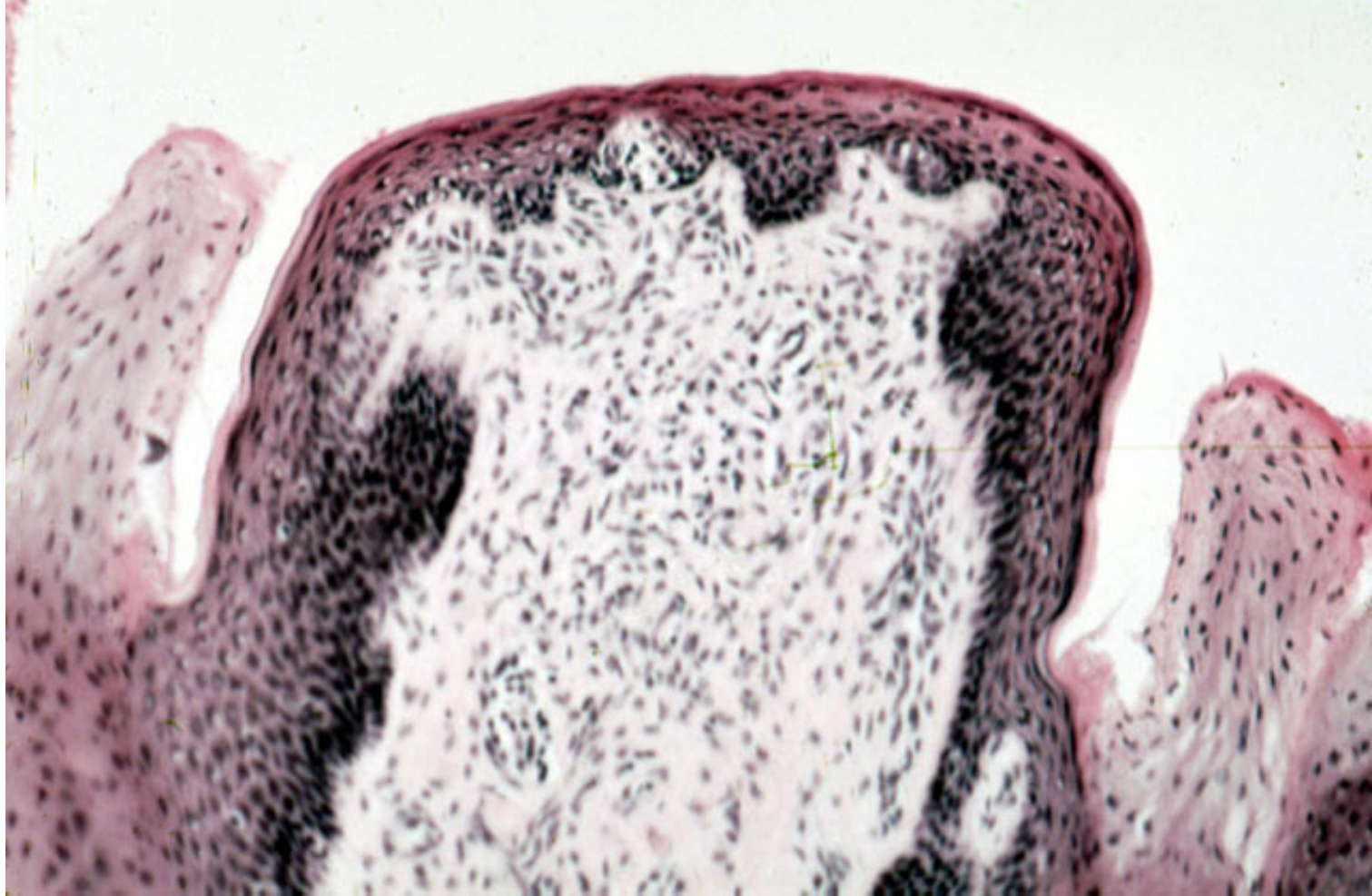
- **Filiform Papillae**

The details of filiform papillae come into view.

H&E, 100x

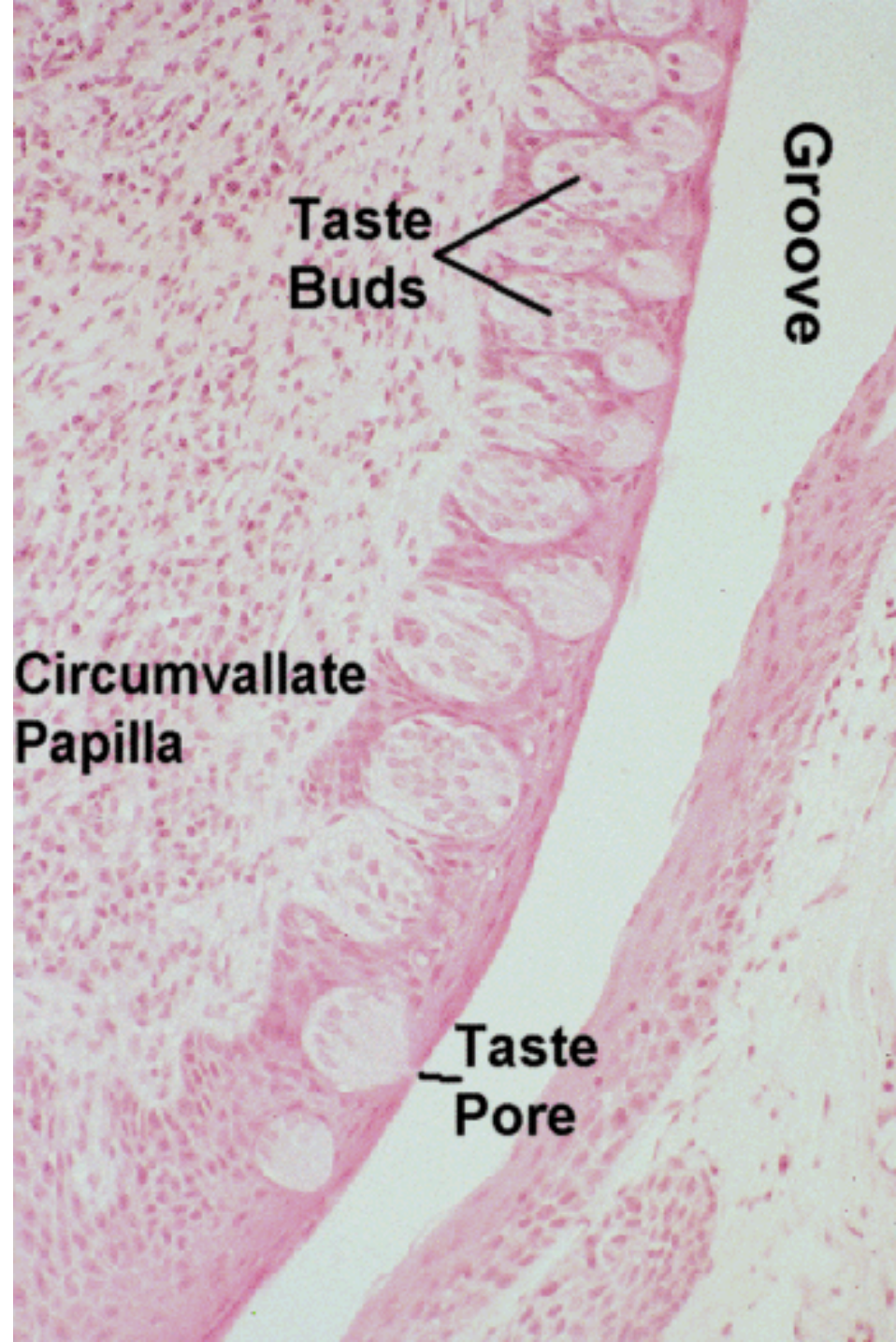
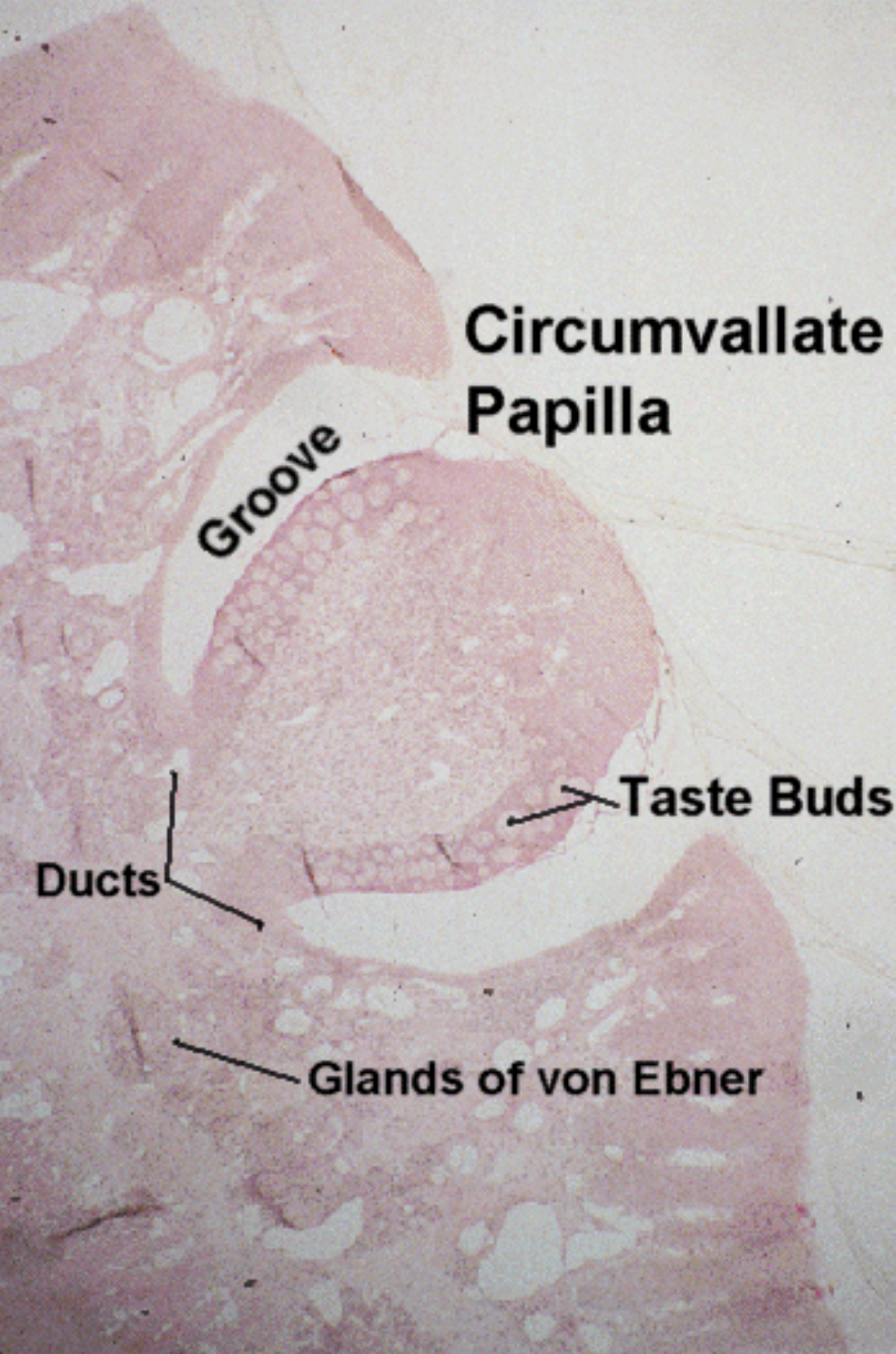
Fungiform Papilla

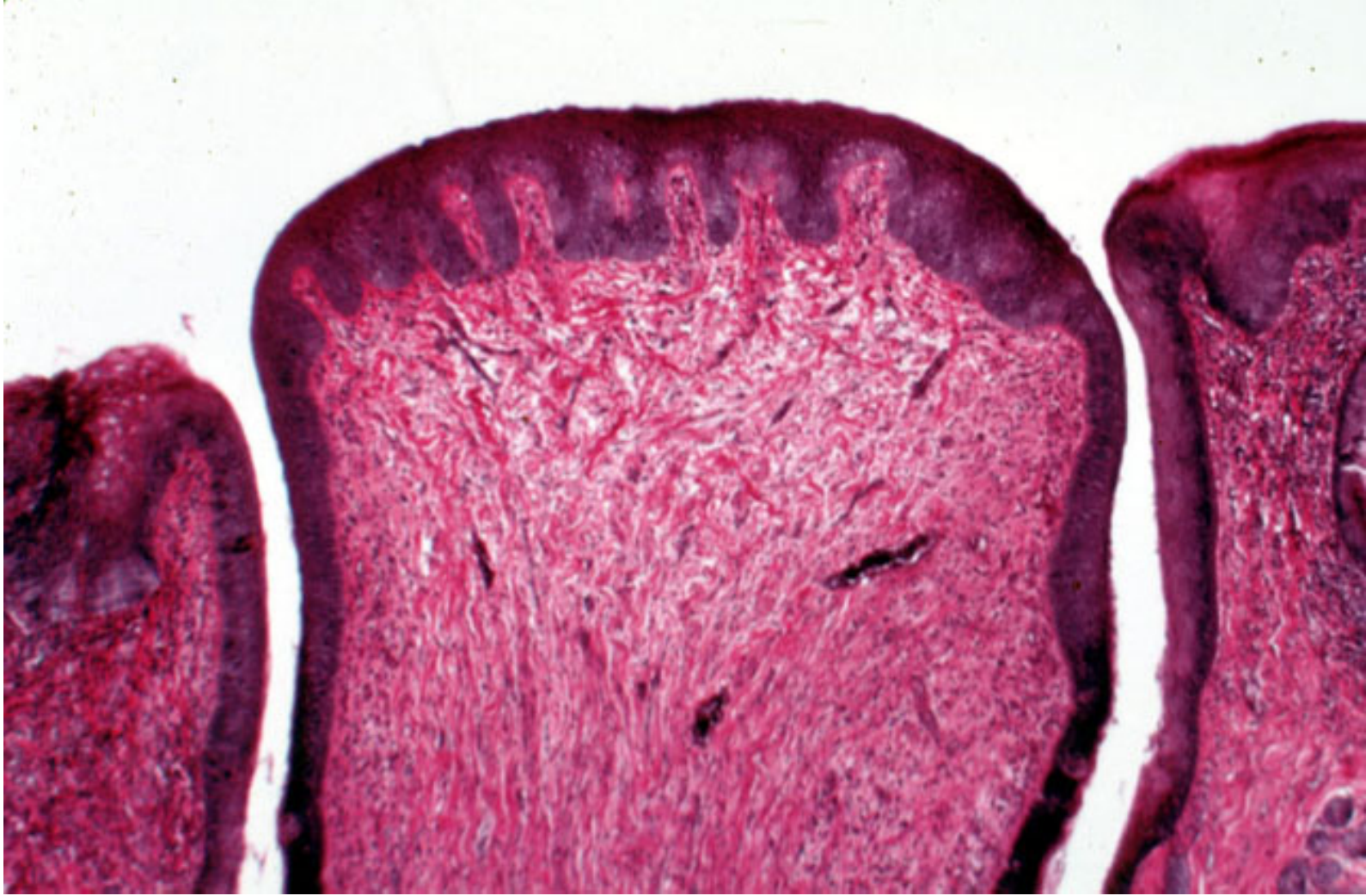




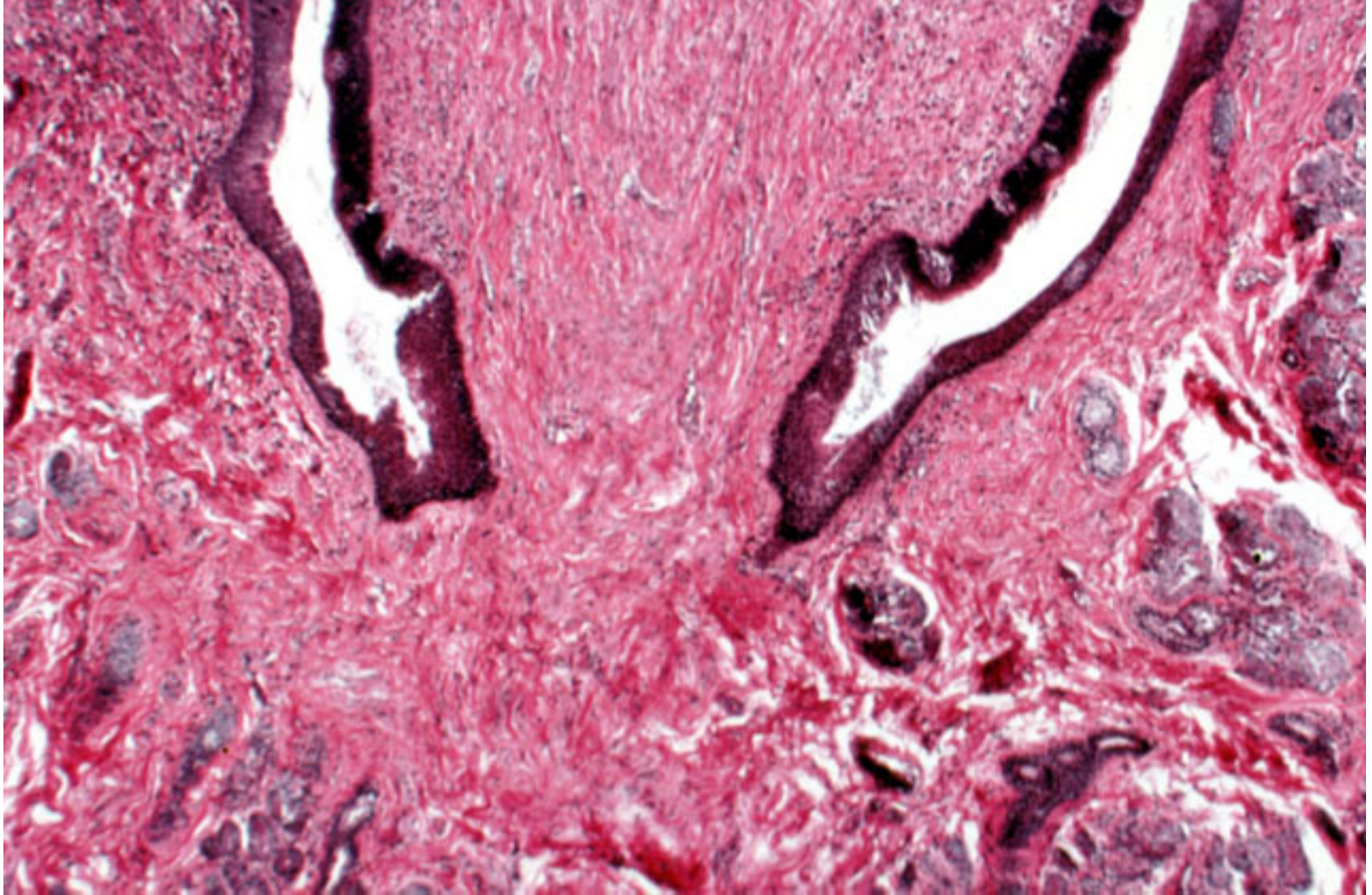
- **Fungiform Papilla**

This is a higher magnification view of a fungiform papilla. H&E, 100x





Circuvallate Papilla H&E, 40x



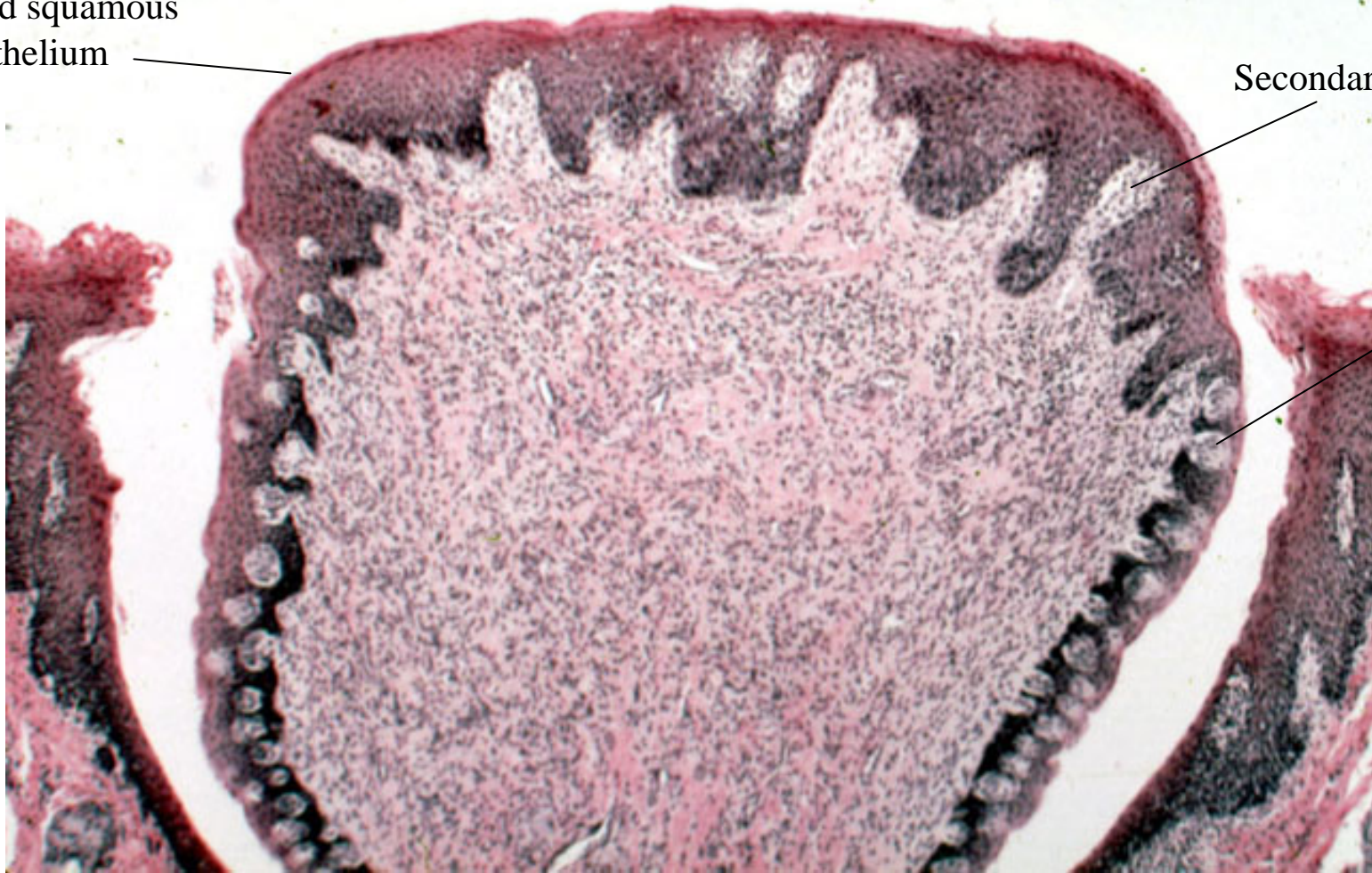
- **Circumvallate Papilla**

Note the taste buds and the few serous acini of von Ebner's glands. H&E, 40x

Stratified squamous
epithelium

Secondary papillae

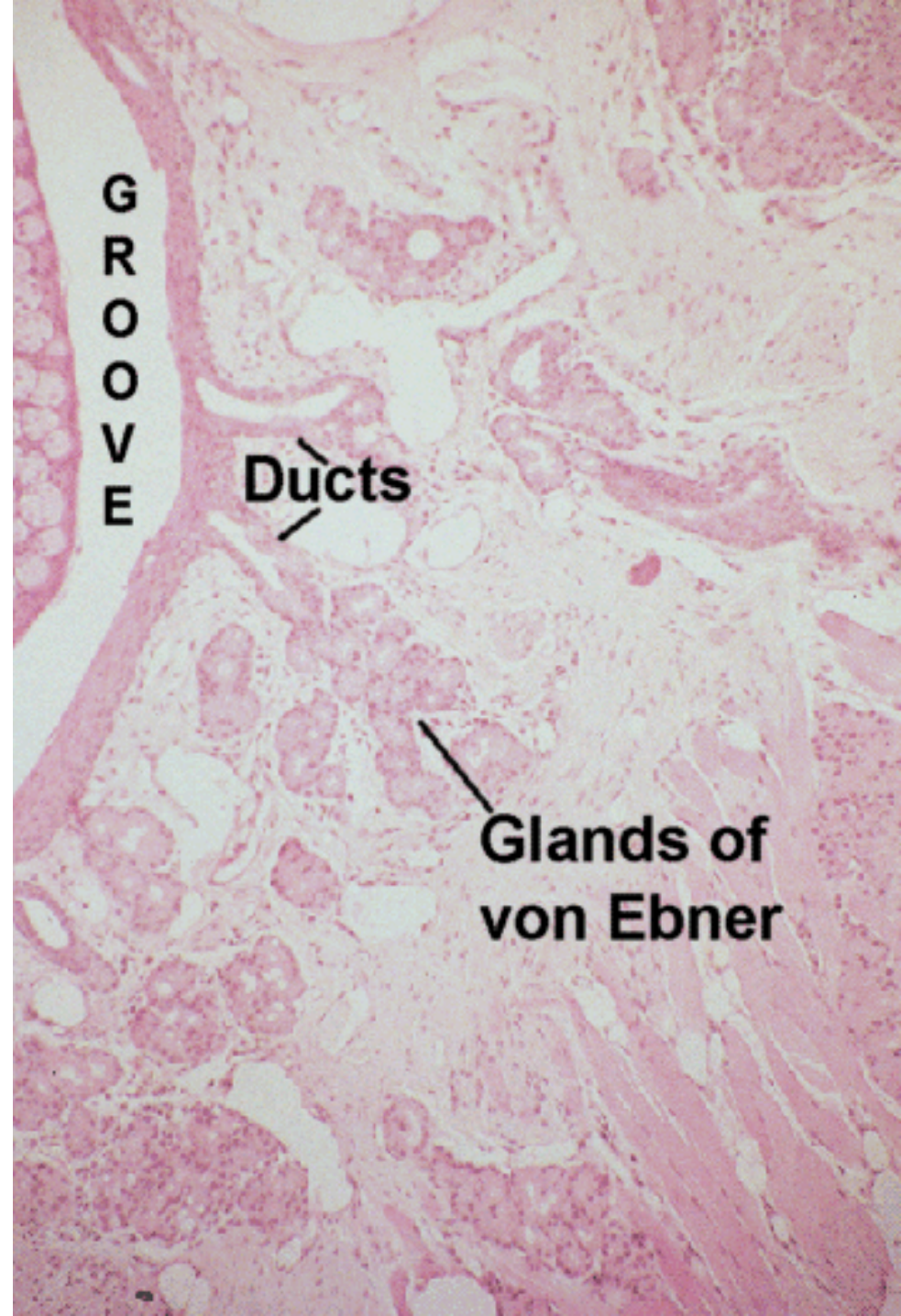Taste buds

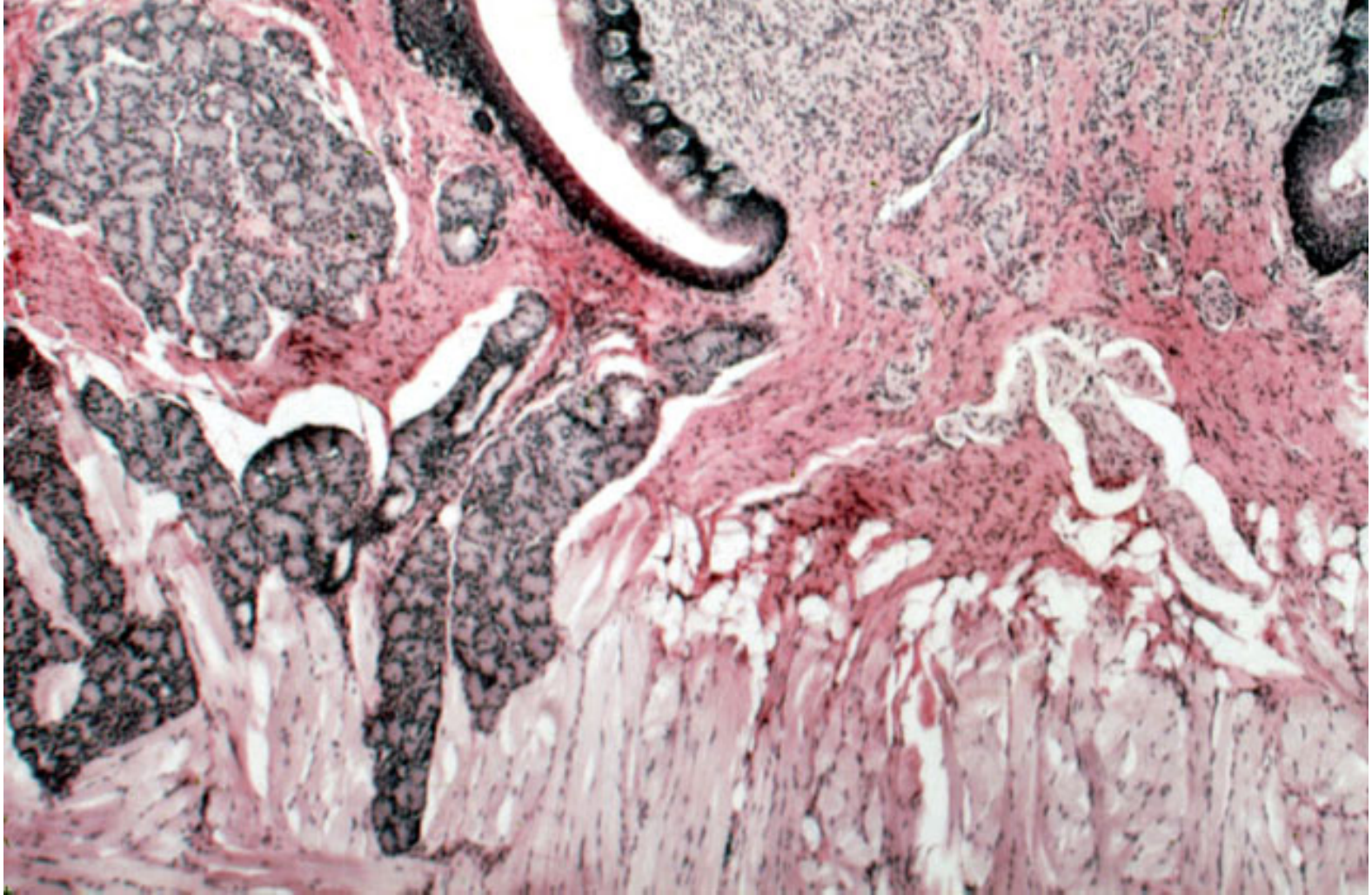


- **Circumvallate Papilla**

The circumvallate papillae are large mushroom-shaped structures which may be up to several millimeters in width. They are characteristically circumscribed by a trough. Numerous taste buds are located within the epithelium that lines the walls of the trough. H&E, 40x

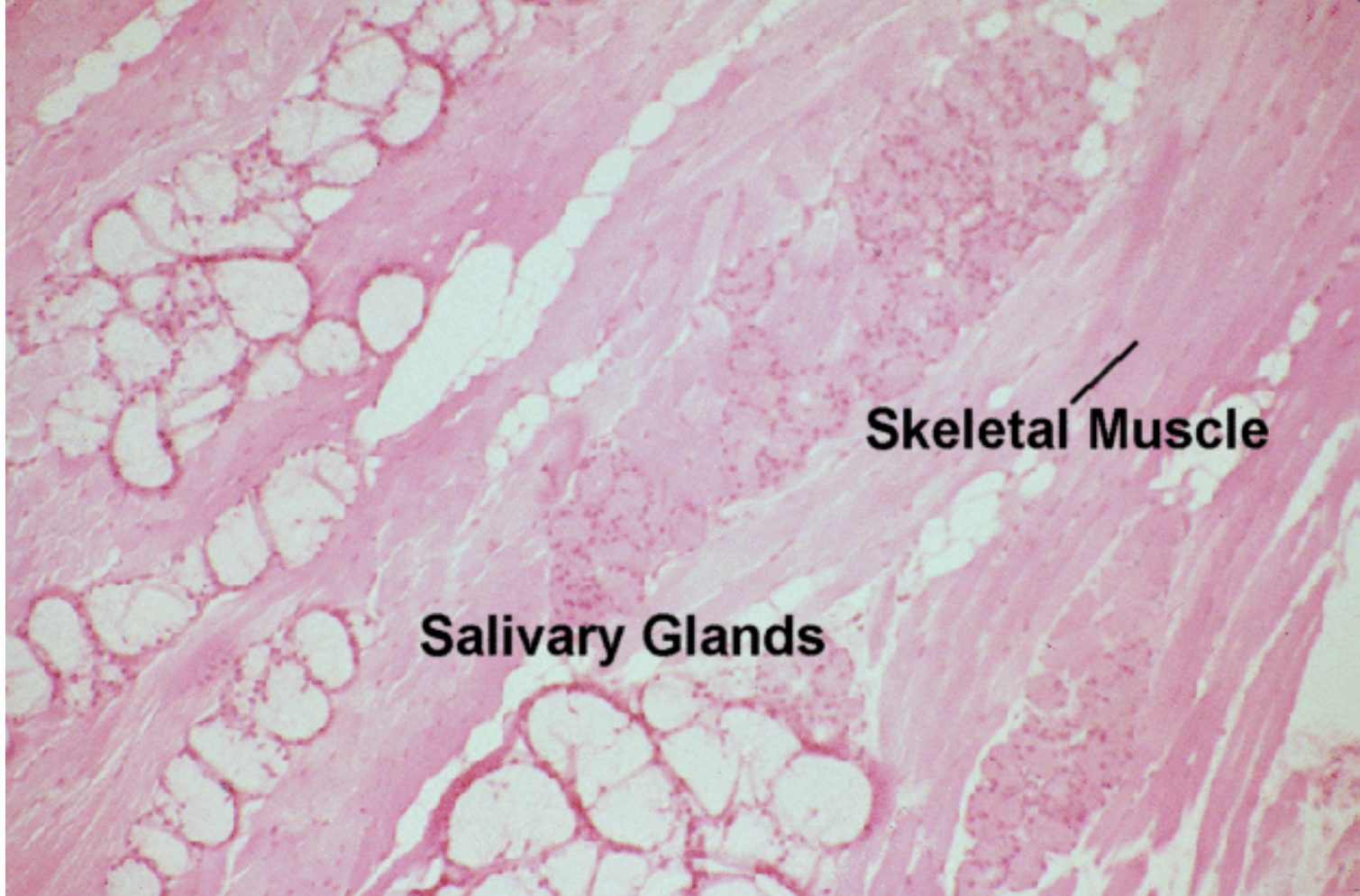- **von Ebner's Glands**
The serous glands located at the base of the circumvallate papilla.
- The secretory product from the glands acts as a solvent for taste-inducing substances



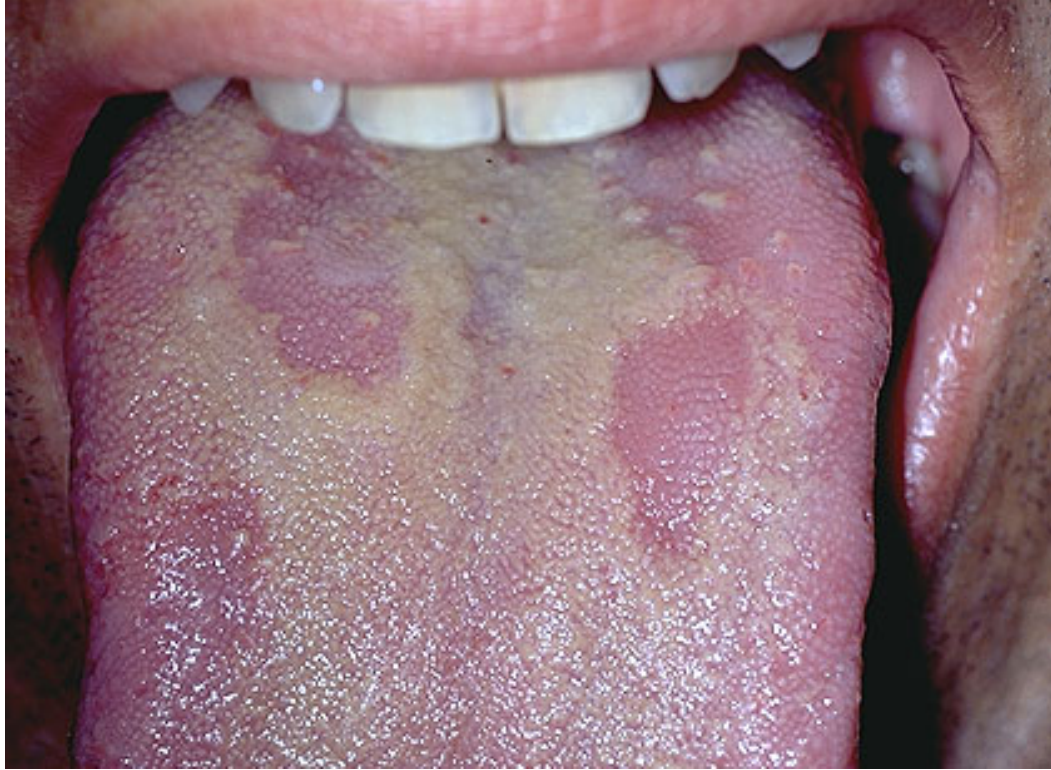

- **von Ebner's Glands**

The serous glands located at the base of the circumvallate papilla. The secretory product from the glands acts as a solvent for taste-inducing substances

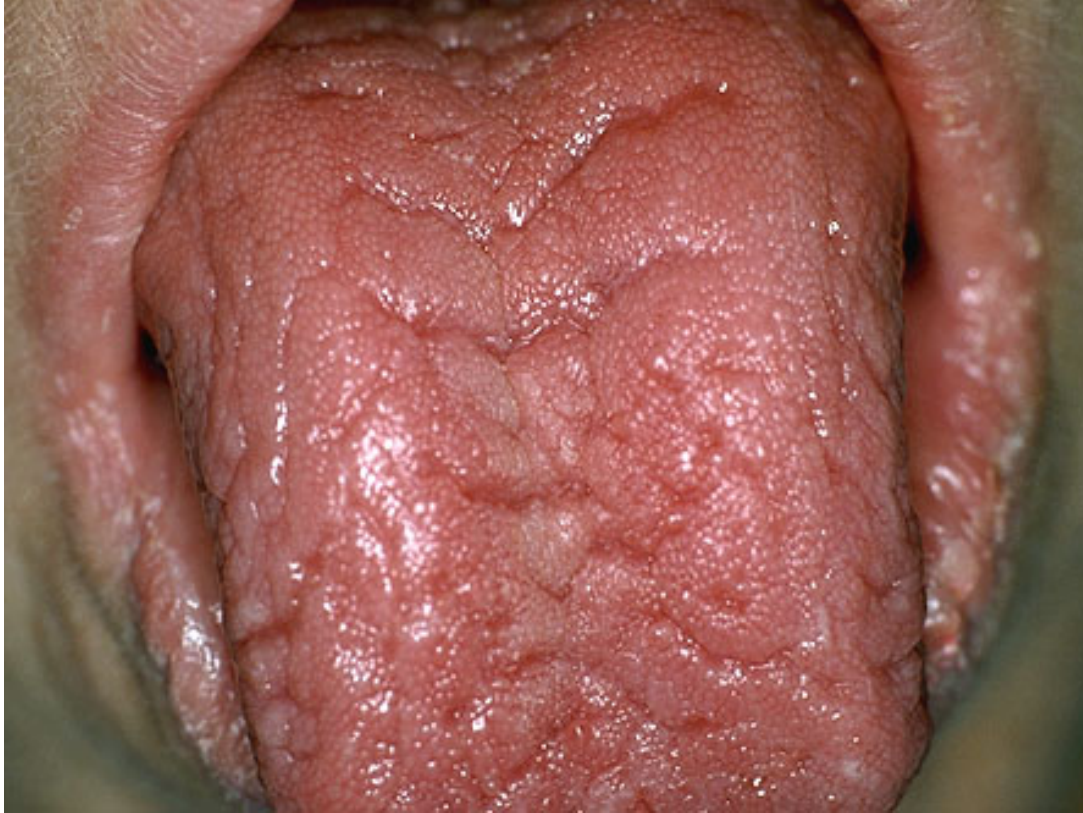

Serous and mucous glands of the tongue



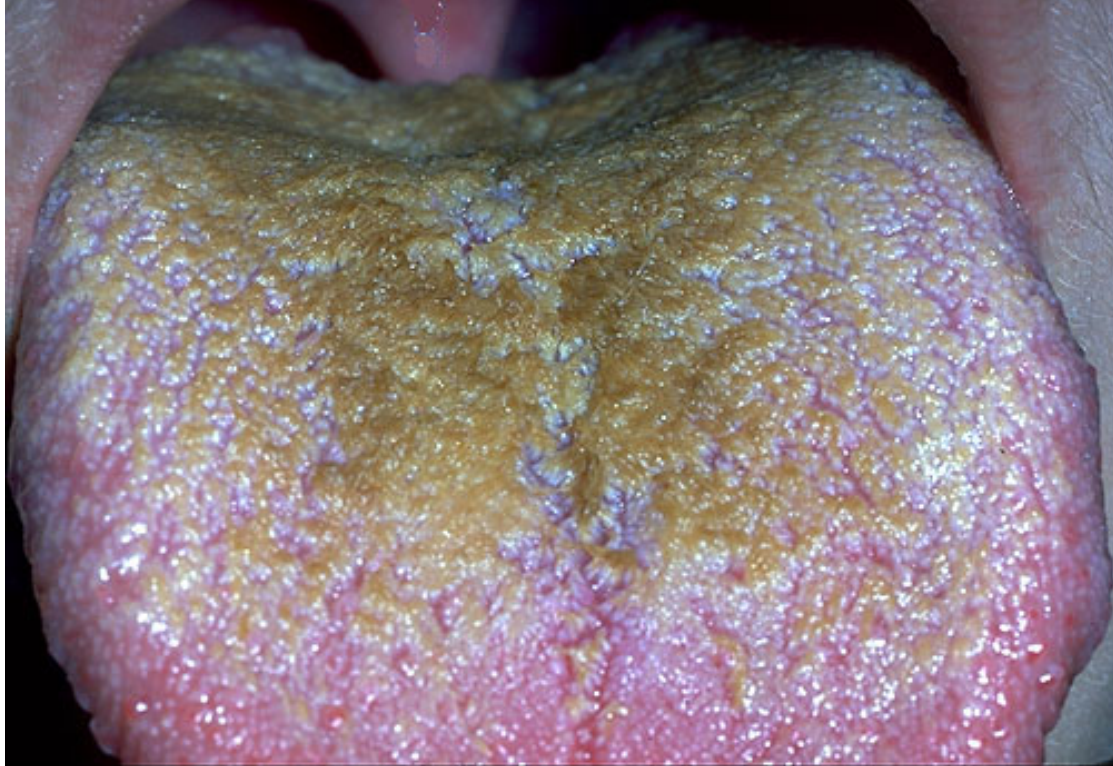Geographic tongue

- is a common condition, associated with life stresses (common cold, work/home stresses)
- characterized by a loss of the filiform papillae leaving reddened areas of atrophic tongue that at times can look like geographic locations.
- The areas heal and another crops up. Then there is healing and recurrence at another time.
- Foods can bother it and it is one of the considerations for a burning mouth in burning mouth syndrome.



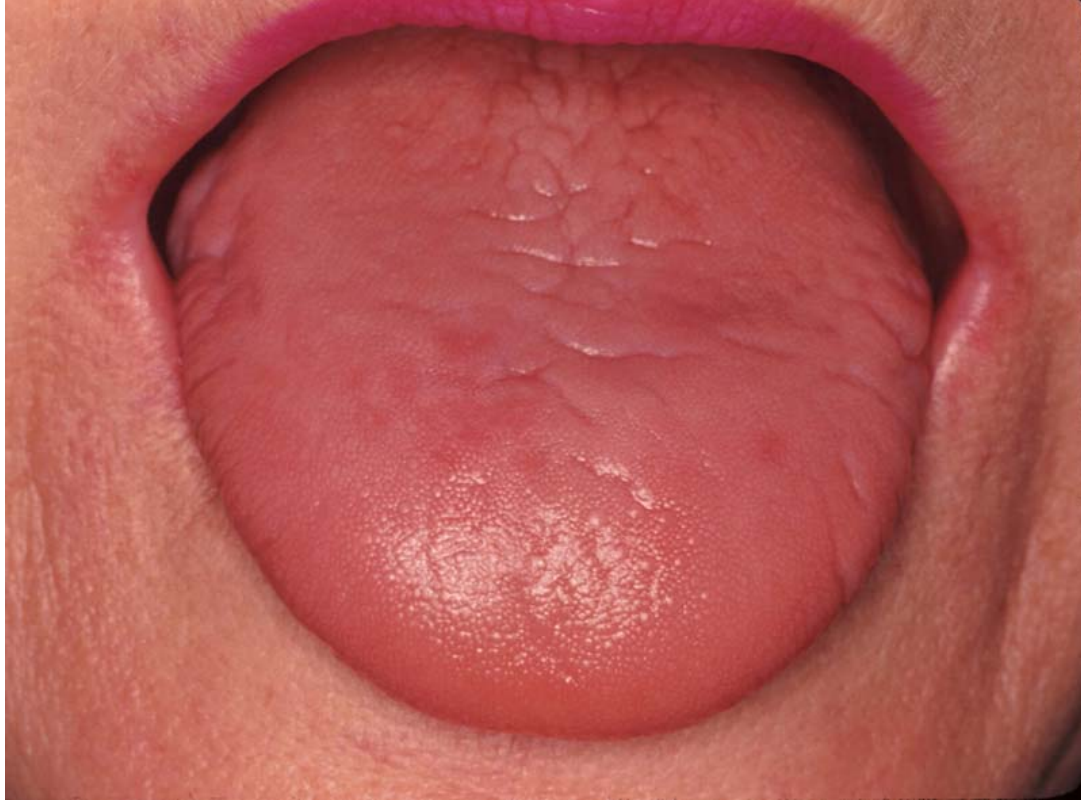This is a fissured or **furrowed tongue**.

- The grooves tend to appear and get deeper or more prominent with age
- If there is ulceration at the base, it is a true fissure with necrotic debris.
- If the base is lined with epithelium, it is a furrow in which bacteria can accumulate accounting for a malodor.
- Other than brushing the tongue, there is no treatment.



Hairy tongue

- due to the fact that the filiform papillae elongate and do not desquamate normally.
- It can be triggered by many things, such as smoking, medications like antibiotics, and others.
- The color may be white or other colors depending on what is introduced to the mouth.
- This is brown from the tobacco staining.
- Treatment is stopping the cause and/or brushing the tongue with a medium or heavy brush.



Smooth tongue

Vitamin deficiency (vit. B) and anemia

Saliva

- Moistens the mouth
- Digest a little starch and fat
- Cleanses the teeth
- Inhibits bacterial growth
- Dissolves molecules so they can stimulate taste buds
- Dilute and buffer foods
- Moistens food and binds particles together to aid in swallowing
- Is a hypotonic solution of 99% water and other solutes
- pH of 6.8 to 7.0

Saliva

Composition of Saliva

- Is a hypotonic solution of 99% water and other solutes
- pH of 6.8 to 7.0

Solutes in saliva

- **Salivary amylase**- an enzyme that begins starch digestion
- **Lingual lipase**- activated by stomach acid and digest fat after the food is swallowed
- **Mucus**- binds and lubricates the food mass and aids in swallowing
- Lysozyme- kills bacteria
- **Immunoglobulin A (IgA)**- inhibits bacterial growth
- **Electrolytes**- including sodium, potassium, chloride, phosphate, and bicarbonate ions

Secretion of Saliva

- Controlled by the parasympathetic system through the **facial** and **glossopharyngeal nerves** which promotes continuous secretion to maintain a moist oral cavity.
- The sympathetic system is in control when under stress and prevents the secretion, resulting in dry mouth.

Salivary Glands

- Two kinds of salivary glands
 - Intrinsic- an indefinite number of small glands dispersed amid the oral tissue
 - Includes
 - Lingual glands in the tongue
 - Labial glands on the inside of the lips
 - Buccal glands on the inside of the cheeks
 - Secretion is small and fairly constant whether eating or not
 - Contains lingual lipase and lysozyme
 - Serves to moisten the mouth and inhibit bacterial growth

Salivary Glands

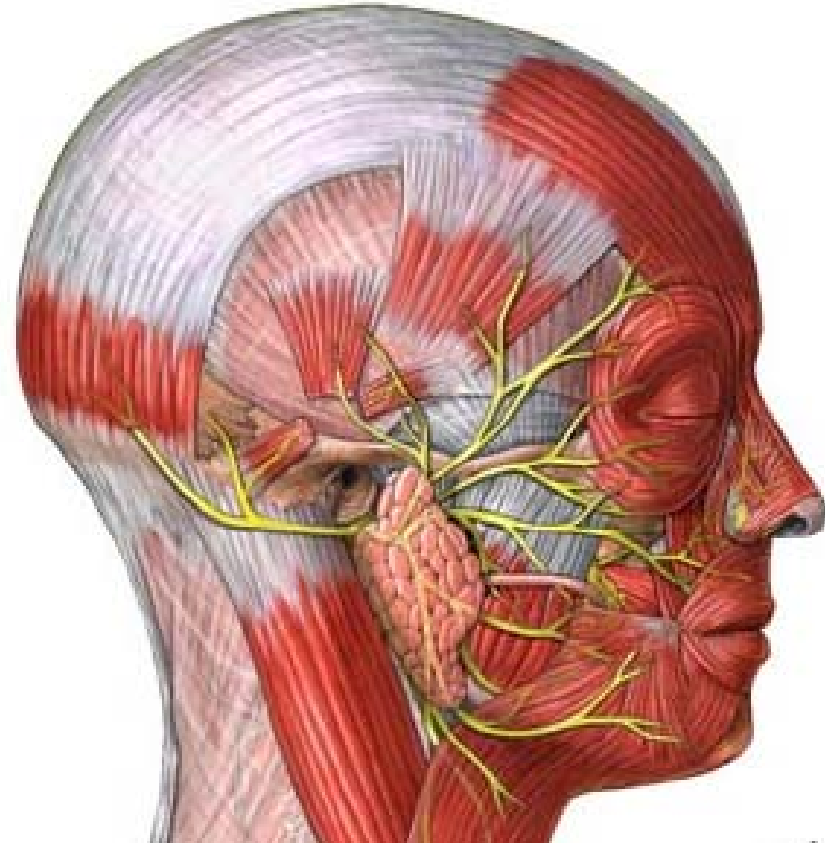
Extrinsic Glands

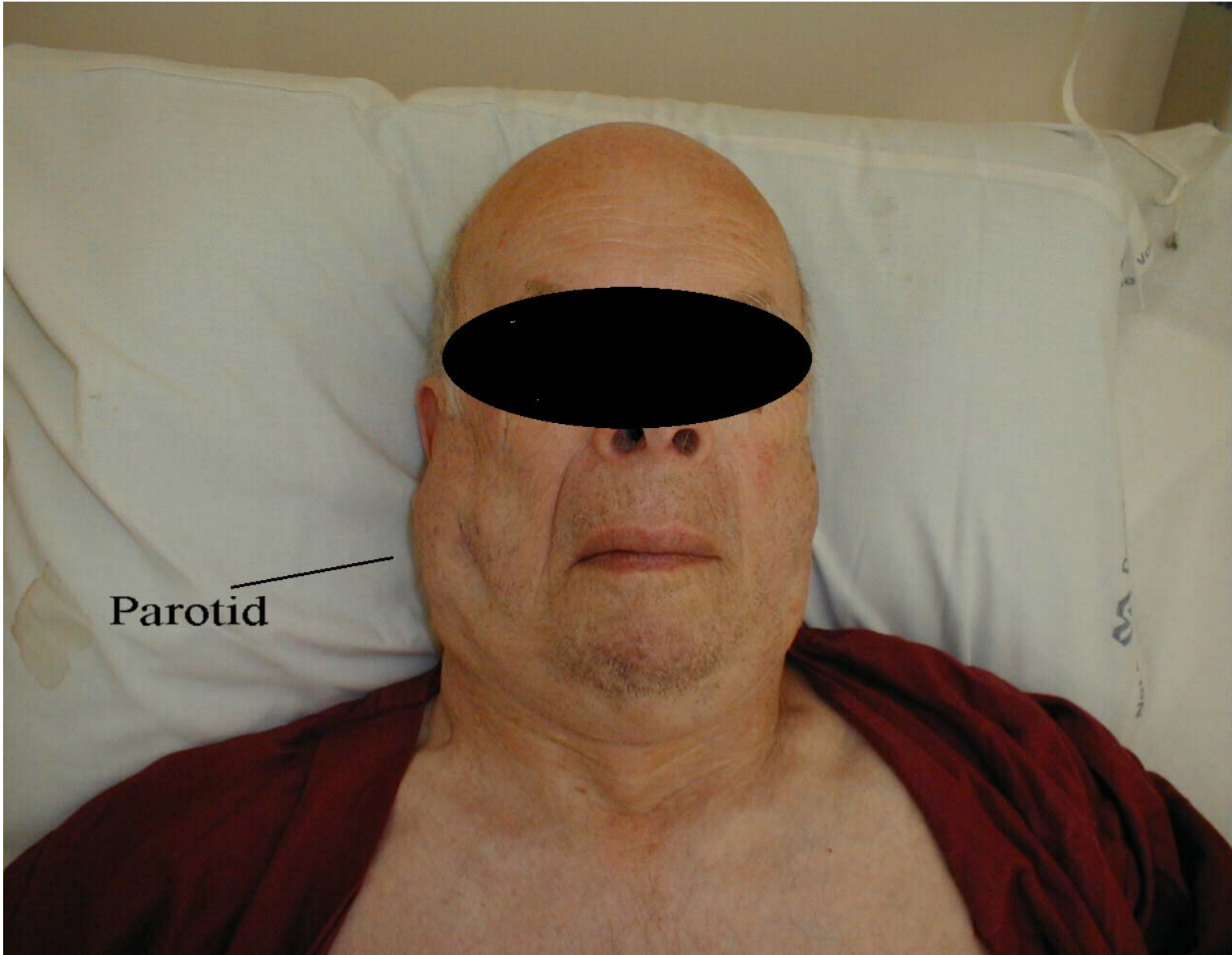- three pairs of larger more discrete organs located outside of the oral mucosa
- They communicate with the oral cavity by way of ducts

Three accessory glands that secrete saliva into the oral cavity.

- **Parotid gland-**

- is the largest of the three glands and is located below and in front of the ears, between the skin and masseter muscle.
 - parotid ducts passes superficially over the masseter, pierces the buccinator and drains into the mouth opposite the second upper molar
 - secretes a fluid rich in amylase
- Becomes infected and swollen with the mumps





Parotid

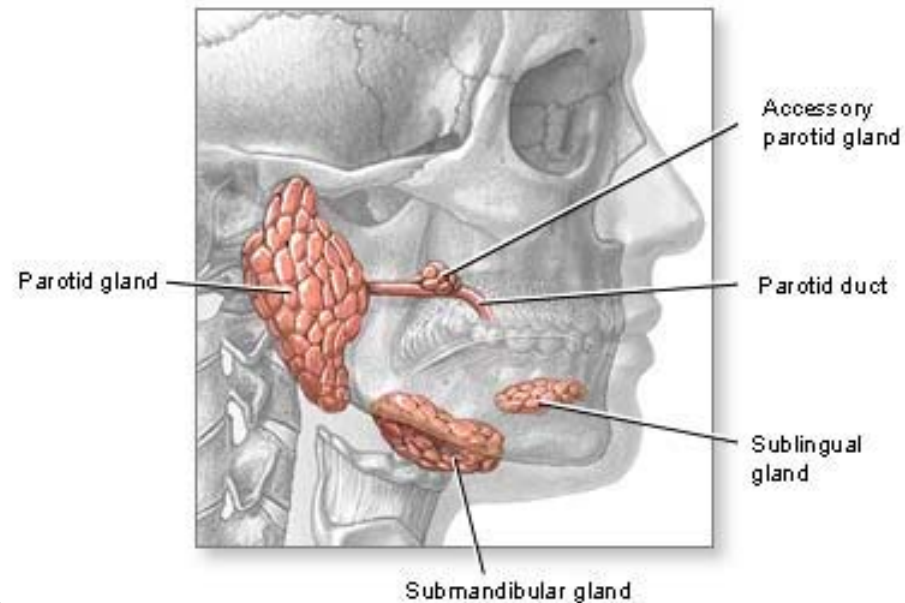
Salivary Glands

- **Submandibular Glands-**

- located in the floor of the mouth on the inside surface of the lower jaw
- Duct empties into the mouth at a papilla on the side of the lingual frenulum, near the central incisors
- Secretes mostly a serous fluid

- **Sublingual glands-**

- are the smallest of the salivary glands and is located on the floor of the mouth under the tongue.
- Has several ducts that empty into the mouth posterior to the papilla of the submandibular duct
- (secretes mostly mucous)



Composition of Saliva

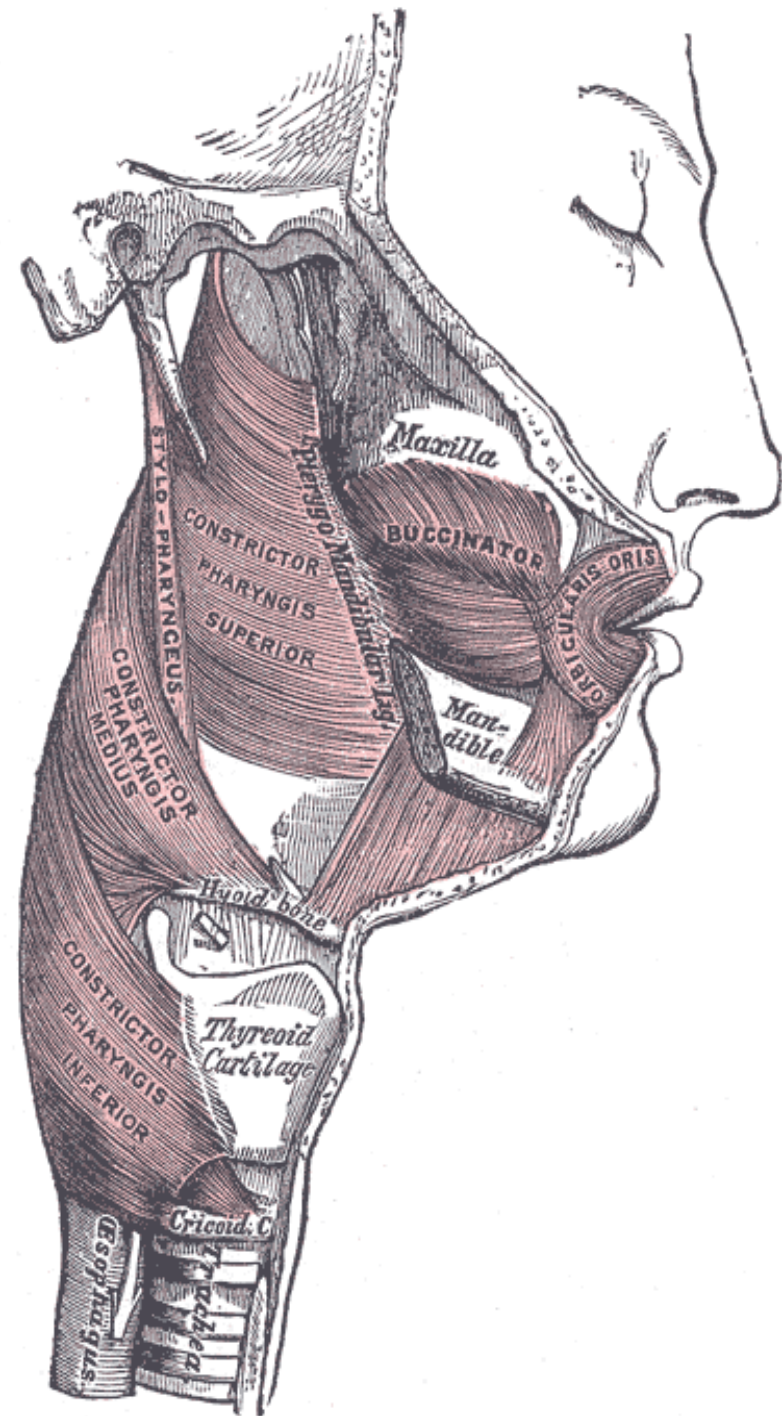
- 99.5% water which provides medium for dissolving food so they can be tasted and for starting digestion reactions
- .5% solute
 - amylase- the digestive enzyme from the parotid gland that acts on starch.
 - Mucous- lubricates food for easy swallowing
 - lysozyme- destroys bacteria to protect the mucous membranes and the teeth from decay.

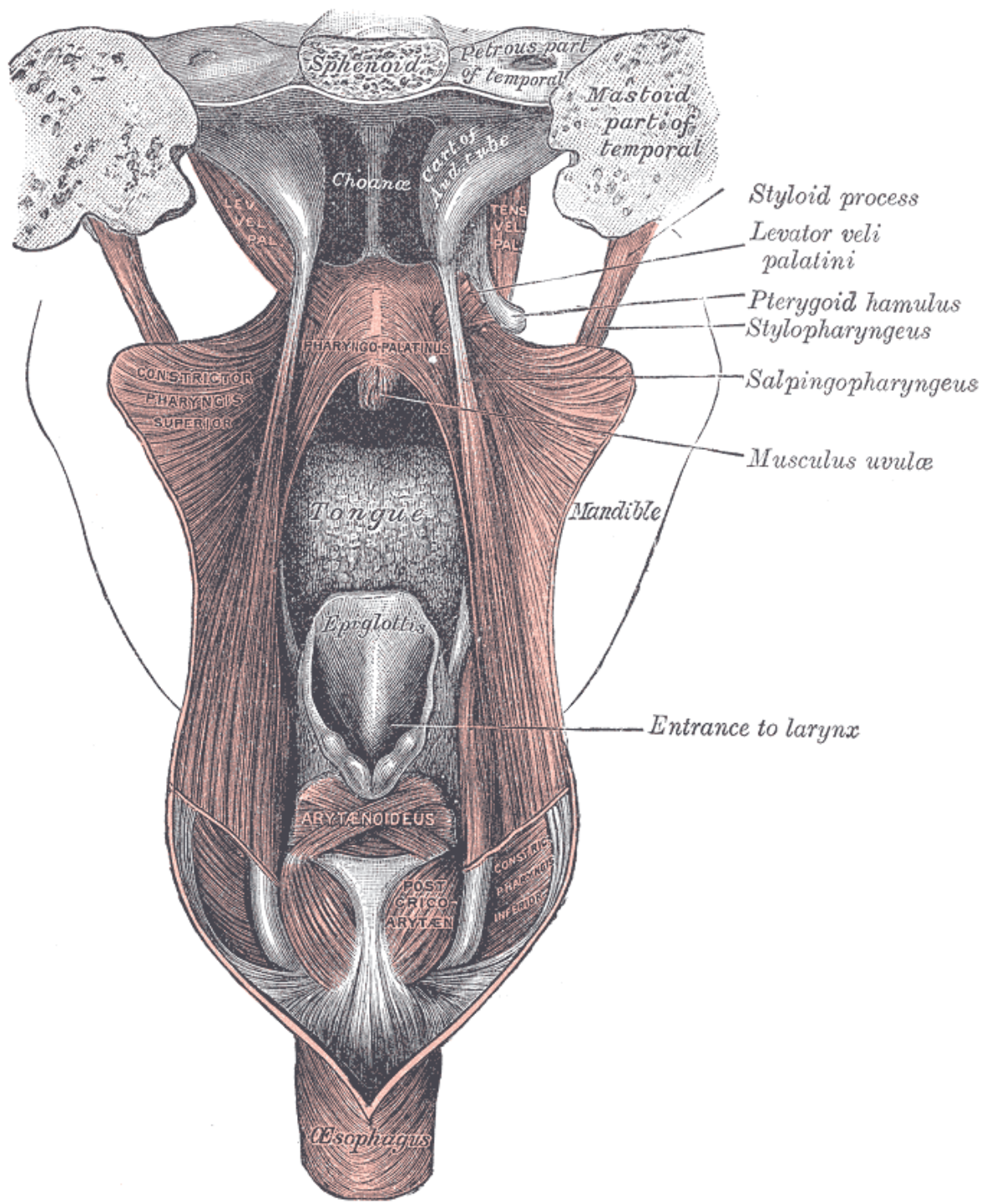
Digestion in the Mouth

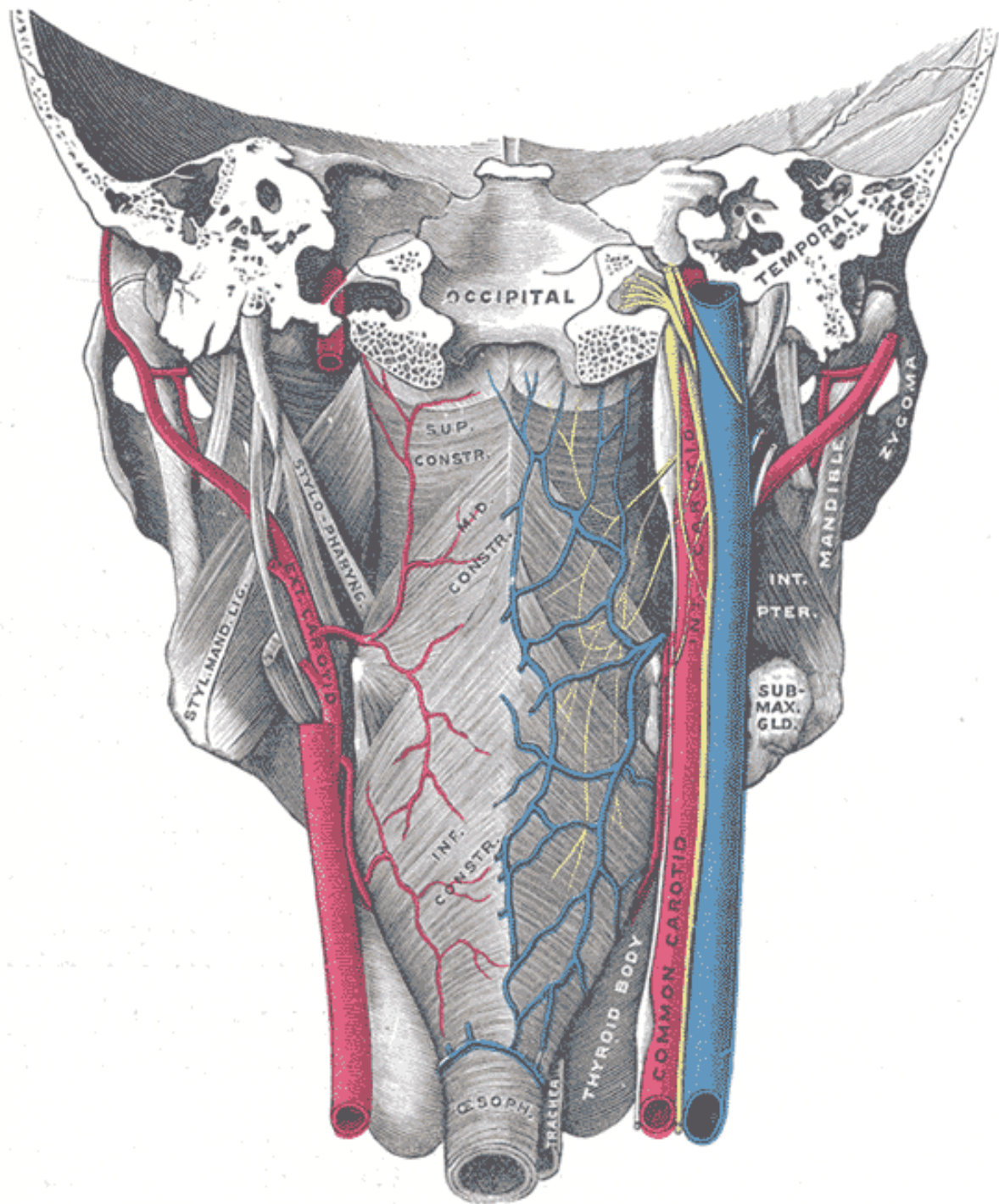
- Mastication (chewing)- the tearing, grinding and mixing of food with saliva to form a bolus that is easily swallowed.
- Chemical breakdown of starches begins in the mouth with the secretion of amylase from the parotid gland. The salivary amylase breaks the bonds between the polysaccharides, converting them to monosaccharides, that can then be absorbed through the walls of the GI tract.

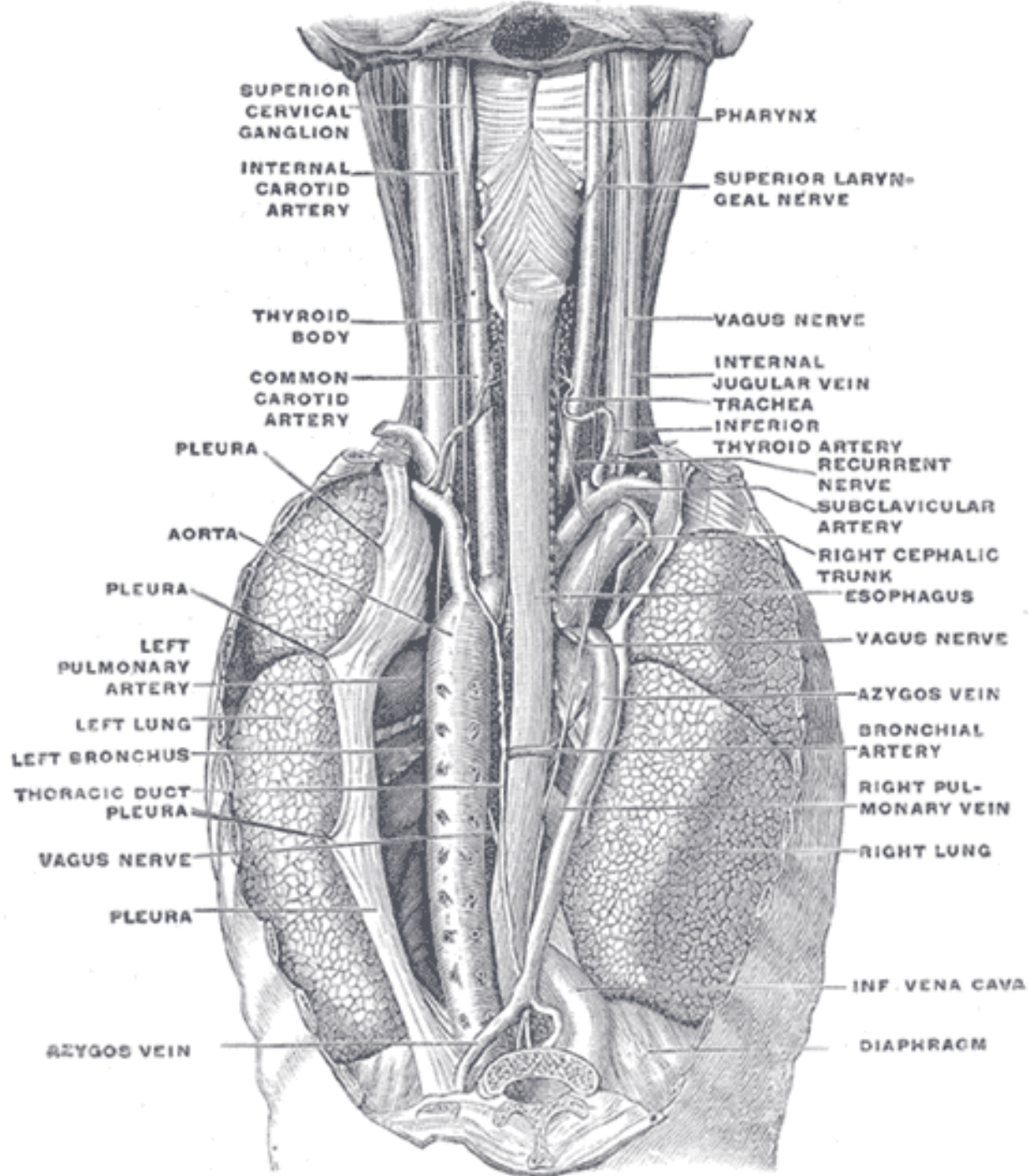
Pharynx

- The tube that extends from the internal nares to the esophagus in back and the larynx in front.
- It has both digestive and respiratory function.
- It connects the nasal and oral cavities with the esophagus.
- Has a deep layer of longitudinal oriented skeletal muscles
 - **stylopharyngus m.**- elevates the larynx & pulls it forward during swallowing
 - **salpingopharyngus m.**-raises nasopharynx
- External circular layer that is divided into three layers called the **superior, middle, and inferior pharyngeal constrictors**
- Forces food downward during swallowing





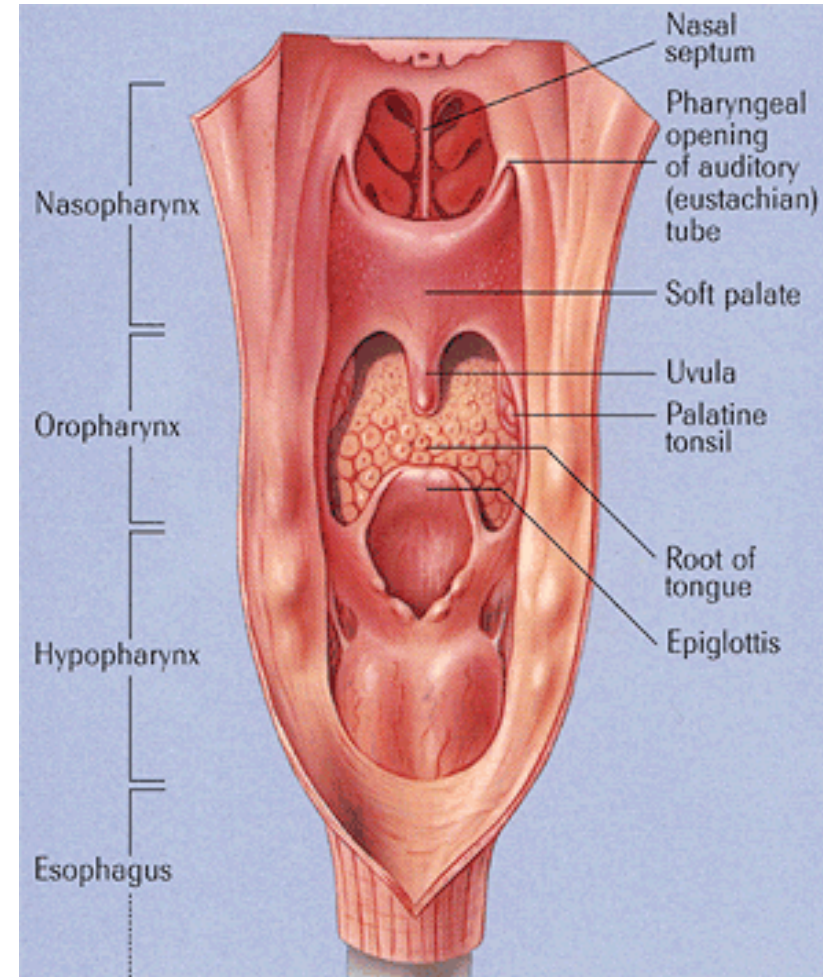




Pharynx

It can be divided into three areas:

- **Nasopharynx**- communicates with the nasal cavity and provides a passageway for air during breathing.
- **Oropharynx**- opens behind the soft palate into the nasopharynx. It functions as a passageway for food moving downward from the mouth and for air moving to and from the nasal cavity.
- **Laryngopharynx**- located just below the oropharynx. It opens into the larynx and esophagus.



Swallowing (Deglutition)

- Coordinated by swallowing center in the medulla oblongata and pons
 - Communicates with the muscles of the pharynx and esophagus via the trigeminal (V), facial (VII), glossopharyngeal (IX), and hypoglossal (XII) nerves
- Swallowing occurs in three stages
 - Buccal phase
 - Pharyngeal-esophageal phase

Stages of Swallowing

Buccal phase

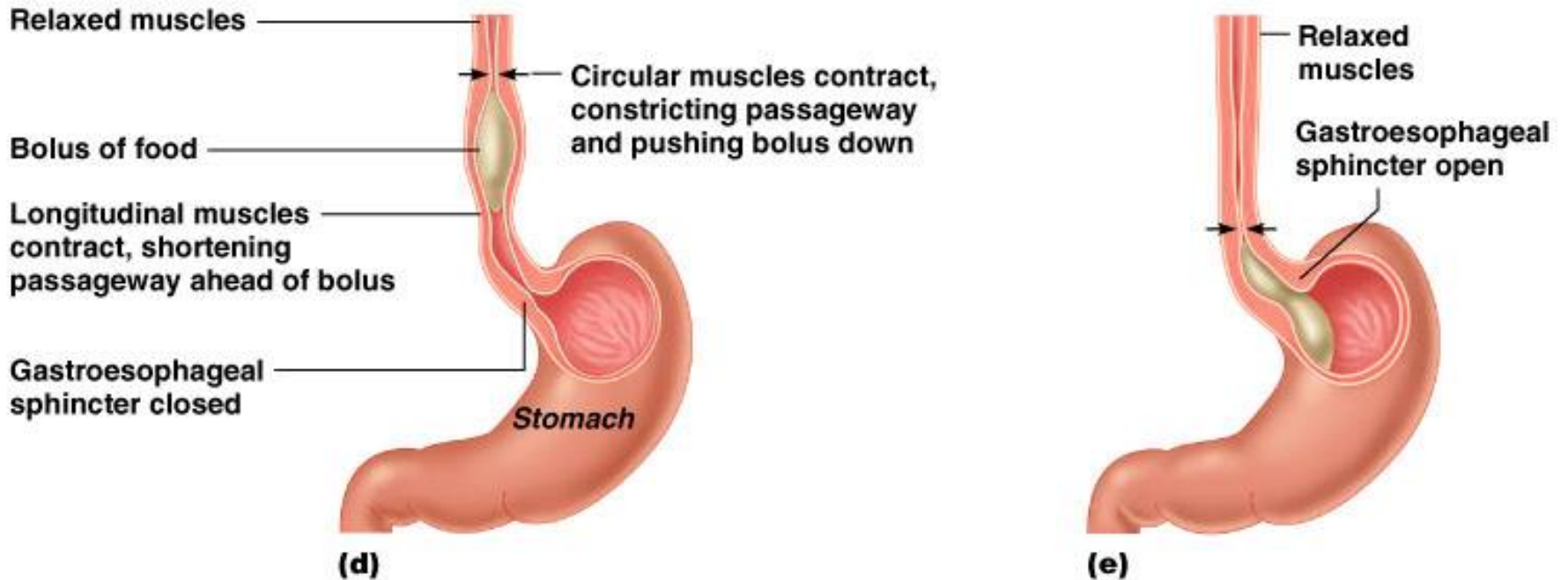
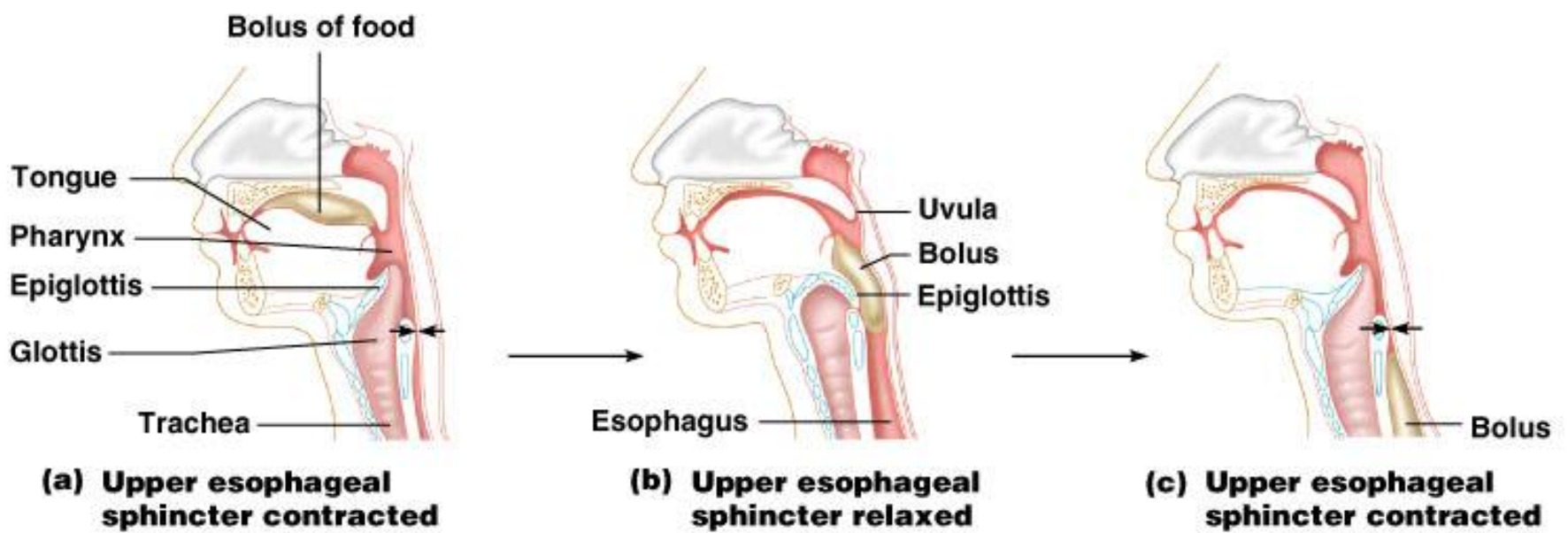
- The voluntary stage in which the tongue collects food, presses it against the plate to form a bolus, and pushes it back into the oropharynx

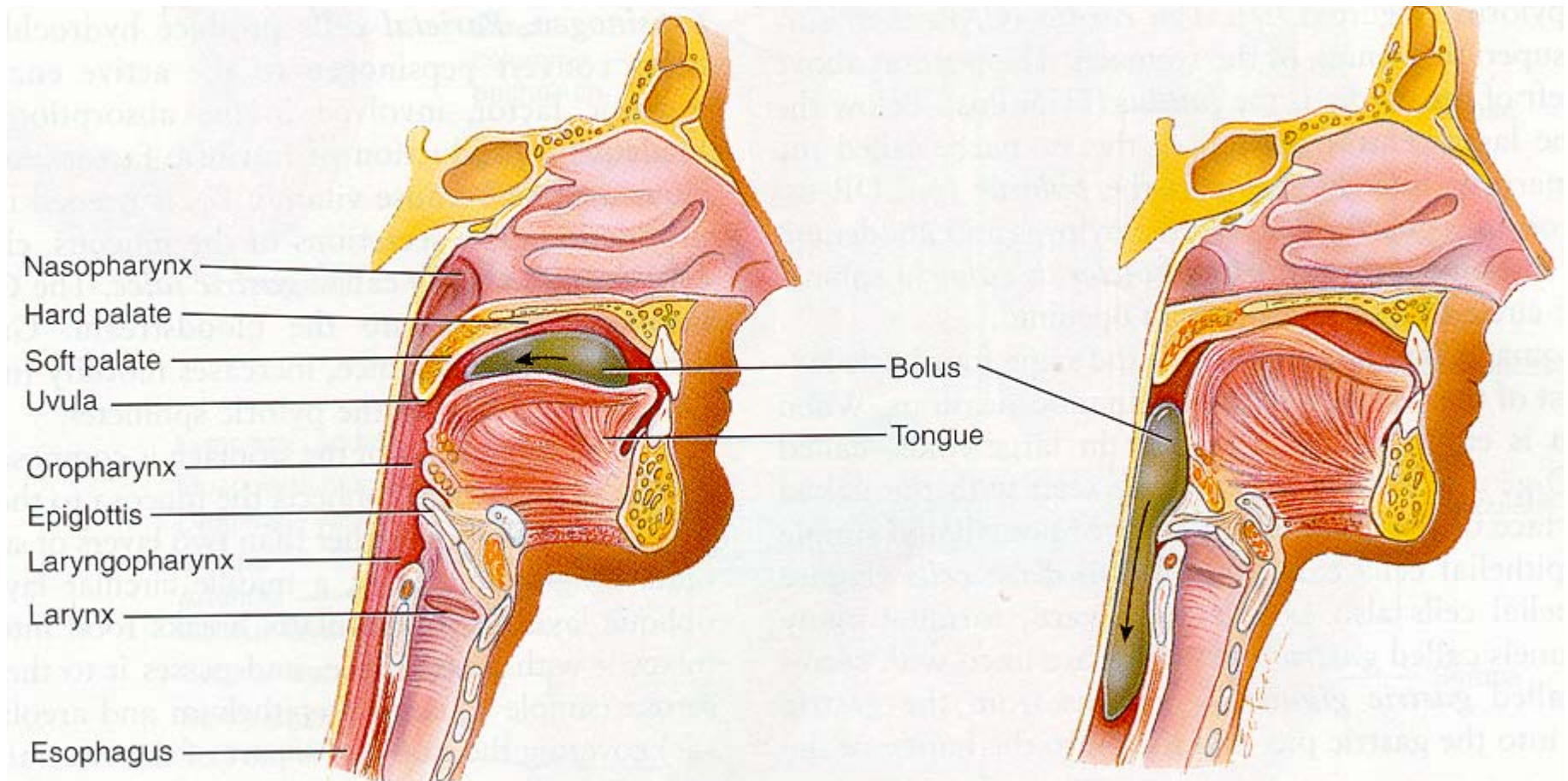
Pharyngeal-esophageal phase

- Three actions block food and drink from reentering the mouth or entering the nasal cavity or larynx
 1. The root of the tongue blocks the oral cavity
 2. The soft palate rises and blocks the nasopharynx
 3. The infrahyoid muscles pull the larynx up against the epiglottis and the vestibular folds adduct to close the airway that leads to the trachea

Stages of Swallowing

- **Esophageal Stage-** Food is moved through the esophagus by peristalsis (the wave like muscle contractions of the inner circular and outer longitudinal muscles).
- The **cricopharyngus m.** or **pharyngeal-esophageal (P.E)** segment separates the pharynx from the esophagus.
 - At the end of the pharyngeal stage of the swallow, it must relax to allow the bolus to enter the esophagus.
 - It is normally closed to prevent the reflux of food and to keep air out of the digestive system.





The soft palate closes off the nasalpharynx and the epiglottis closes off the larynx.

Muscular Movement



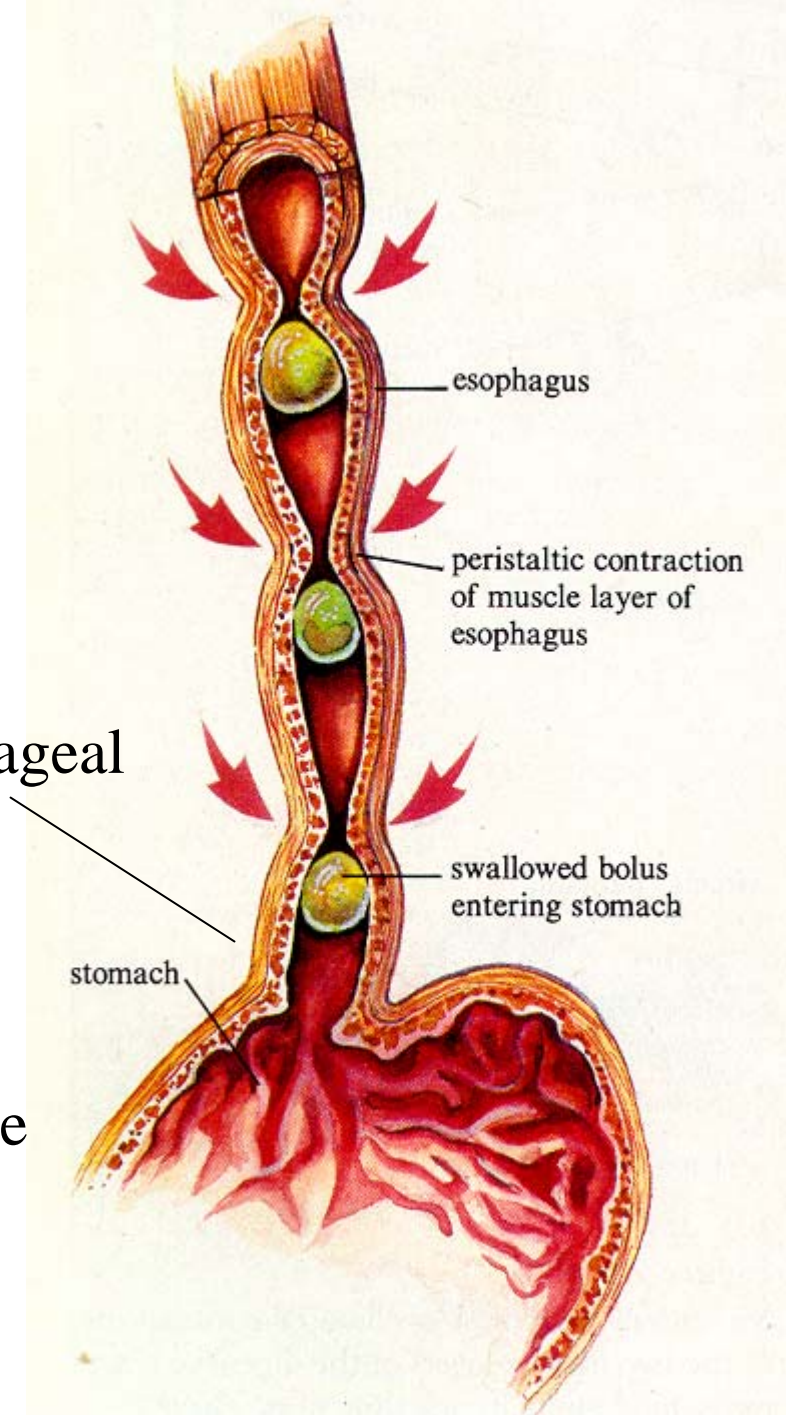
Peristalsis

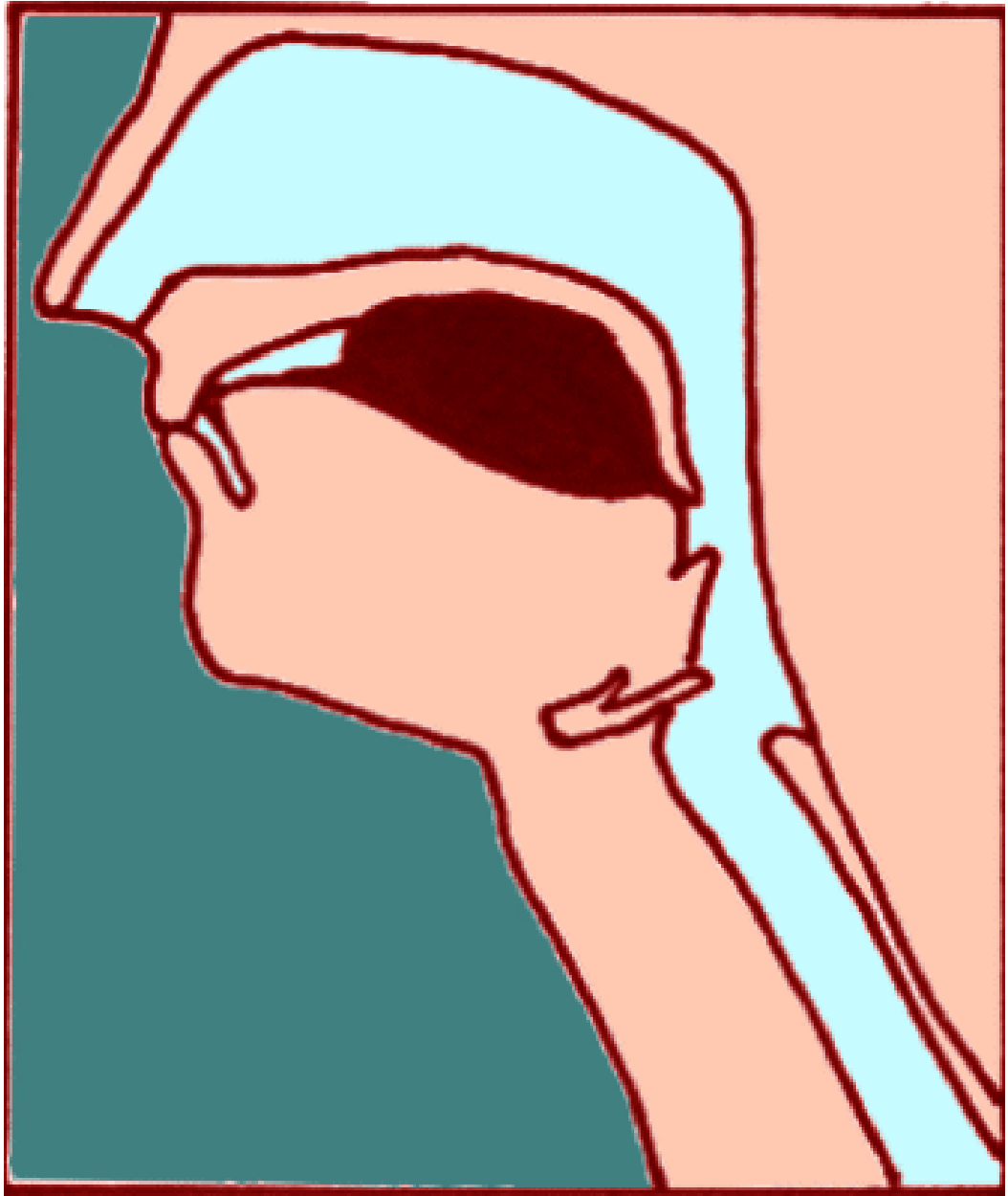


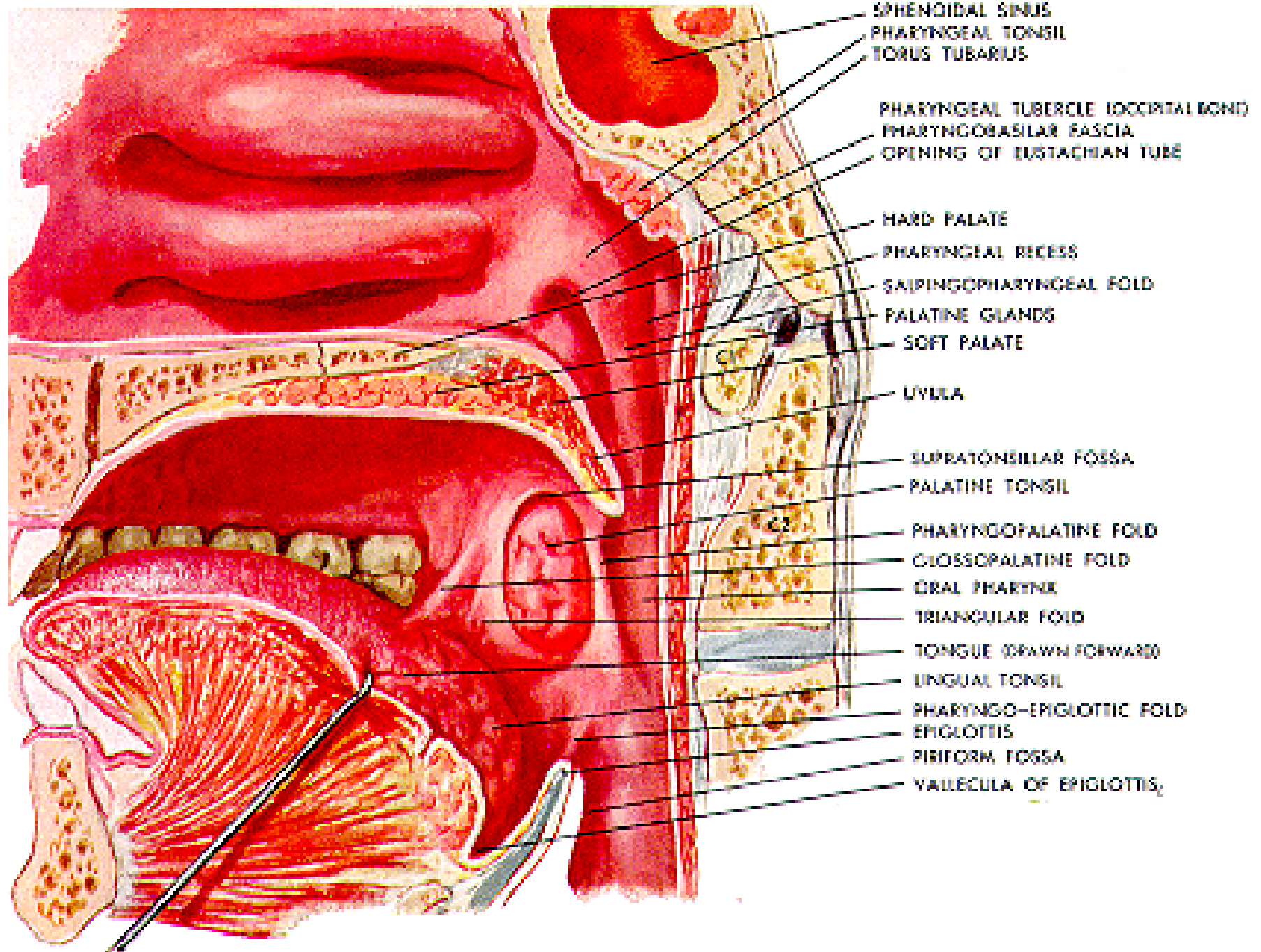
Segmental

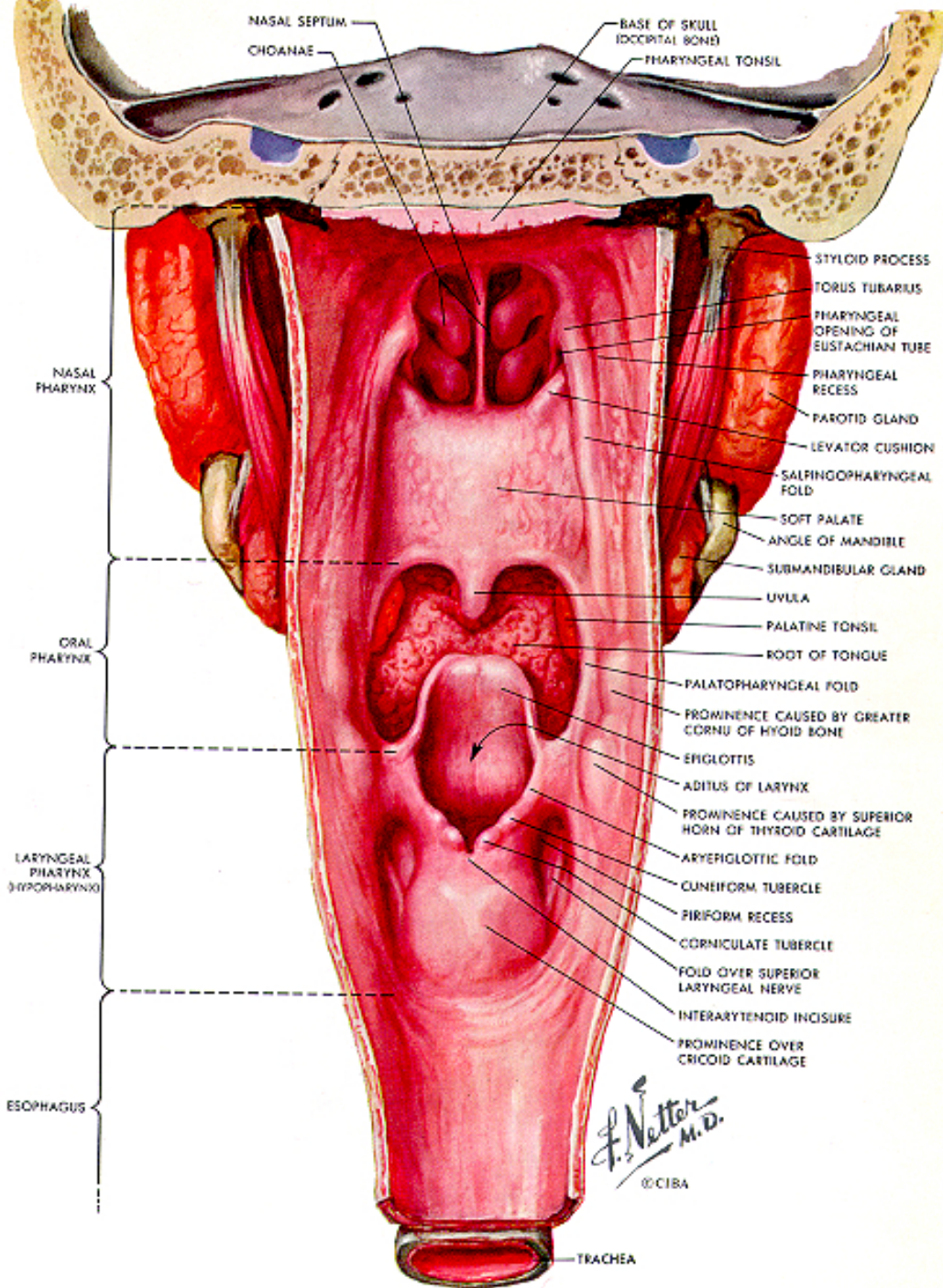
Lower gastroesophageal
sphincter

heartburn- when HCl from the stomach regurgitates back into the lower esophagus resulting in a burning sensation.



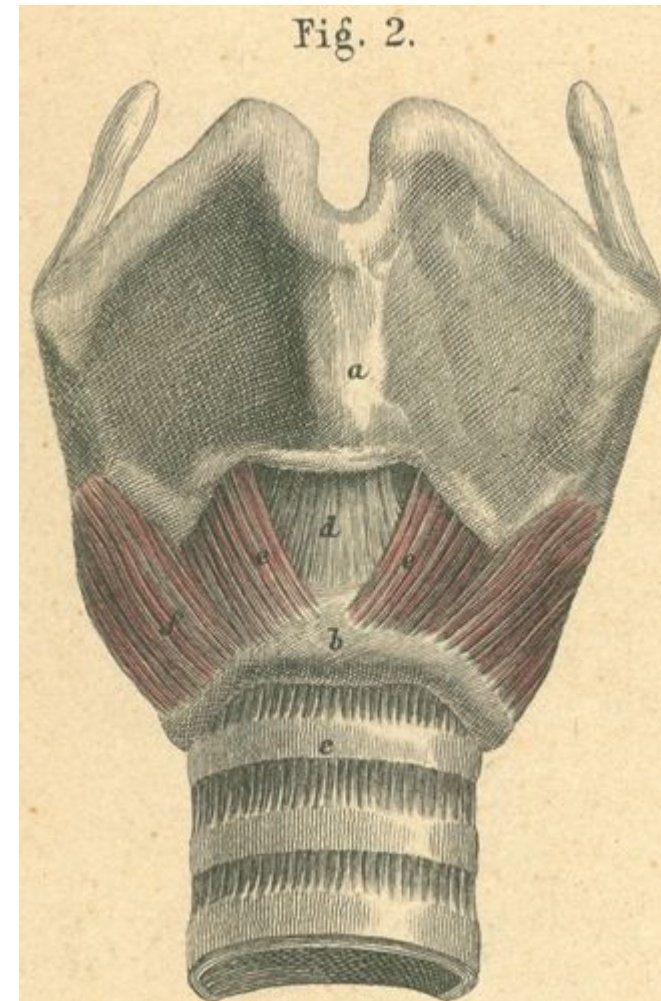




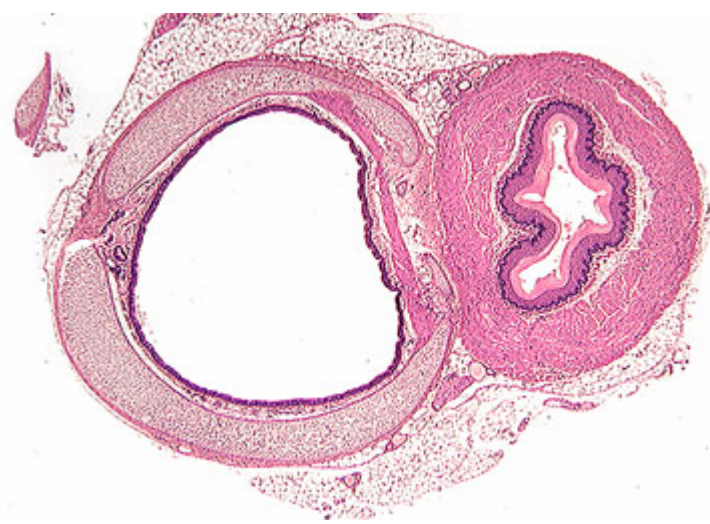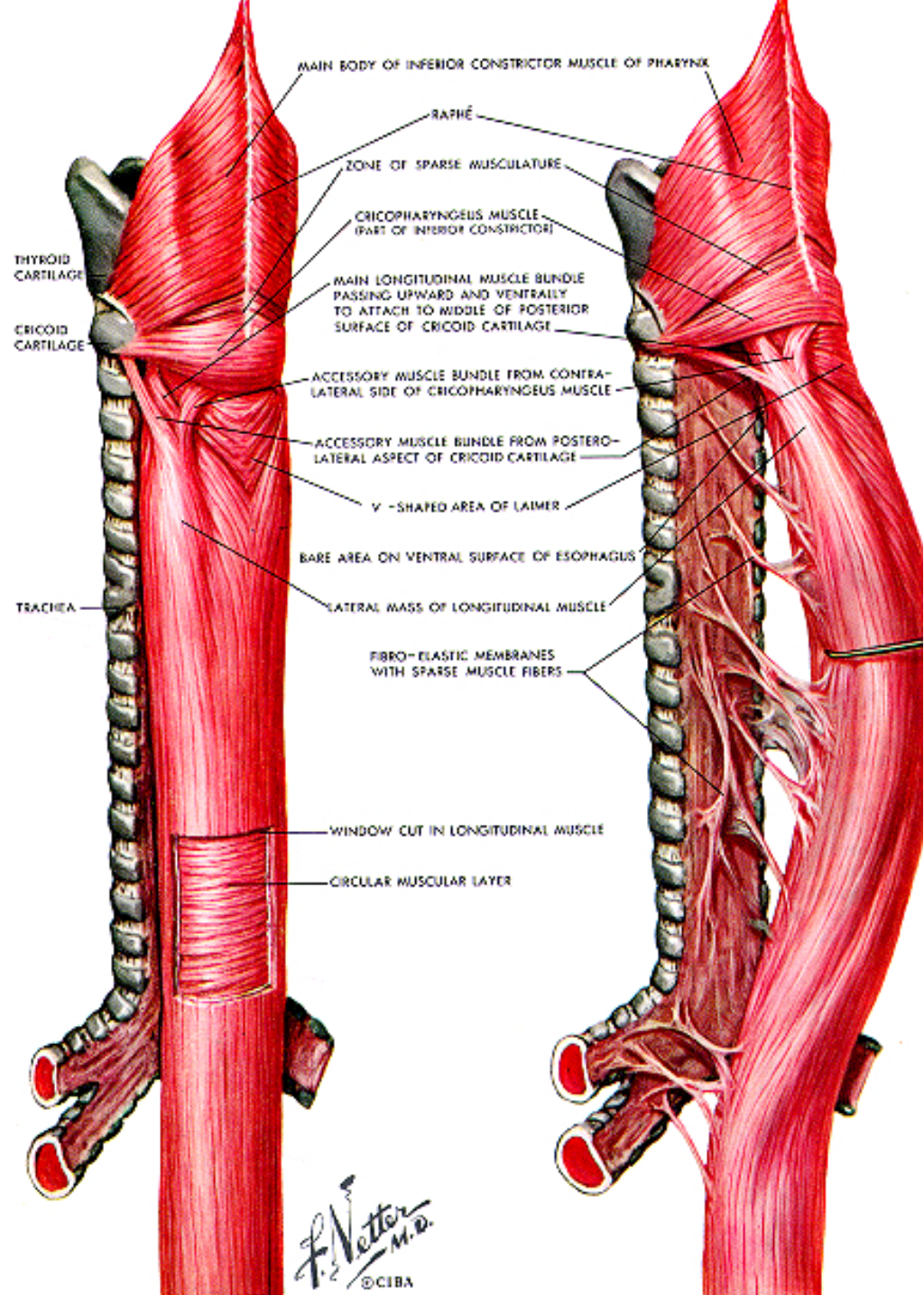


Esophagus

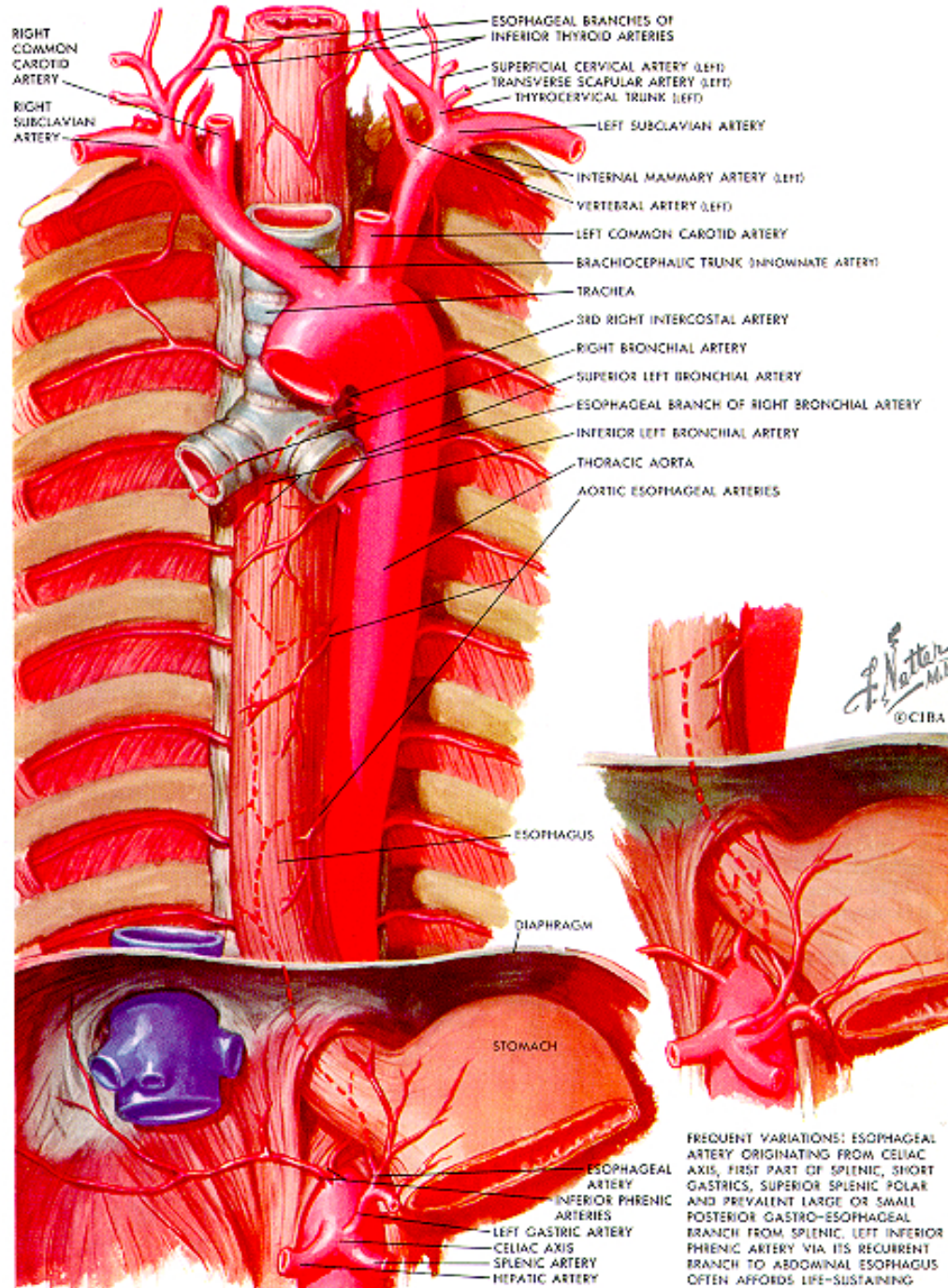
- A straight muscular tube about 25-30 cm long
- It begins at the level of the **cricoid cartilage**, inferior to the larynx behind the trachea and extends through the chest cavity, pierces the diaphragm at the **esophageal hiatus**, and meets with the stomach at an opening called the **cardiac orifice**.
- It transports food to the stomach and secretes mucus, which aids transport.



- a) Thyroid cartilage.
- b) Cricoid cartilage.
- c) Tracheal cartilage.
- d) Middle cricothyroid ligament.
- e) m. Cricothyroid, pars recta.
- f) m. Cricothyroid, pars obliqua



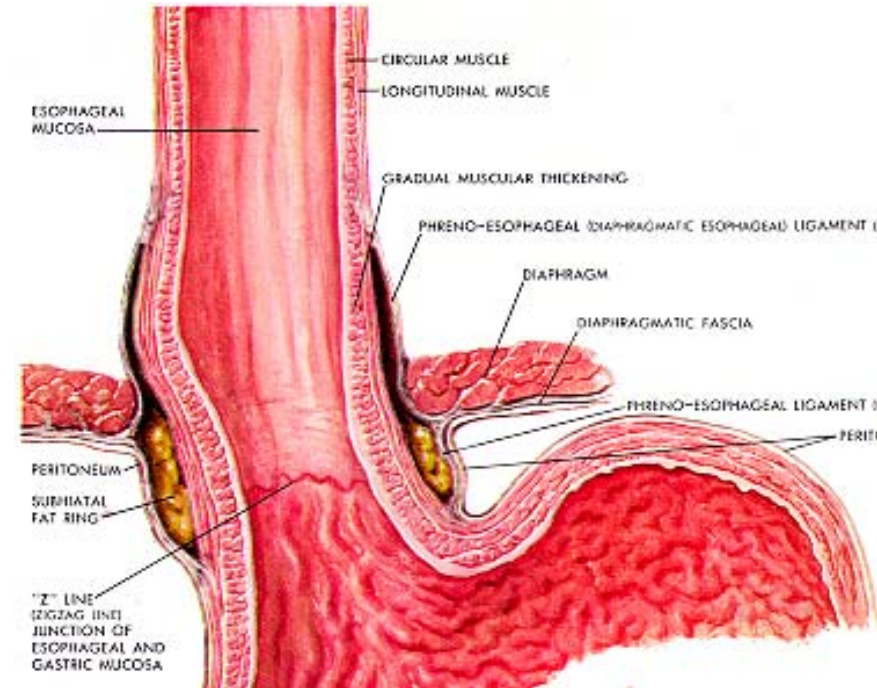
F. Netter M.D.
 ©CIBA



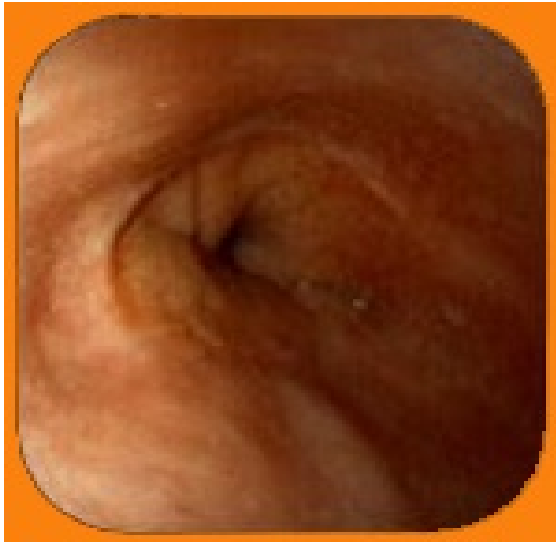FREQUENT VARIATIONS: ESOPHAGEAL ARTERY ORIGINATING FROM CELIAC AXIS, FIRST PART OF SPLENIC, SHORT GASTRICS, SUPERIOR SPLENIC POLAR AND PREVALENT LARGE OR SMALL POSTERIOR GASTRO-ESOPHAGEAL BRANCH FROM SPLENIC, LEFT INFERIOR PHRENIC ARTERY VIA ITS RECURRENT BRANCH TO ABDOMINAL ESOPHAGUS OFTEN AFFORDS LIFE-SUSTAINING BLOOD SUPPLY TO THIS ENTERIC SEGMENT

Esophagus

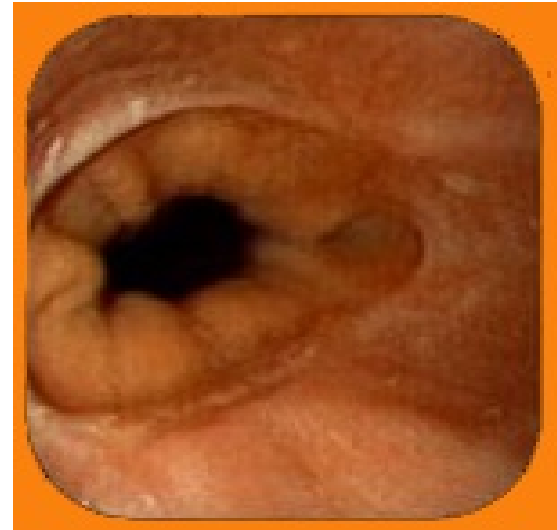- The inferior segment is constricted forming the **lower esophageal sphincter** which, along with the diaphragm, closes to prevent back flow of stomach contents
- **Heartburn-** when HCl from the stomach regurgitates back into the lower esophagus resulting in a burning sensation.



Esophagus

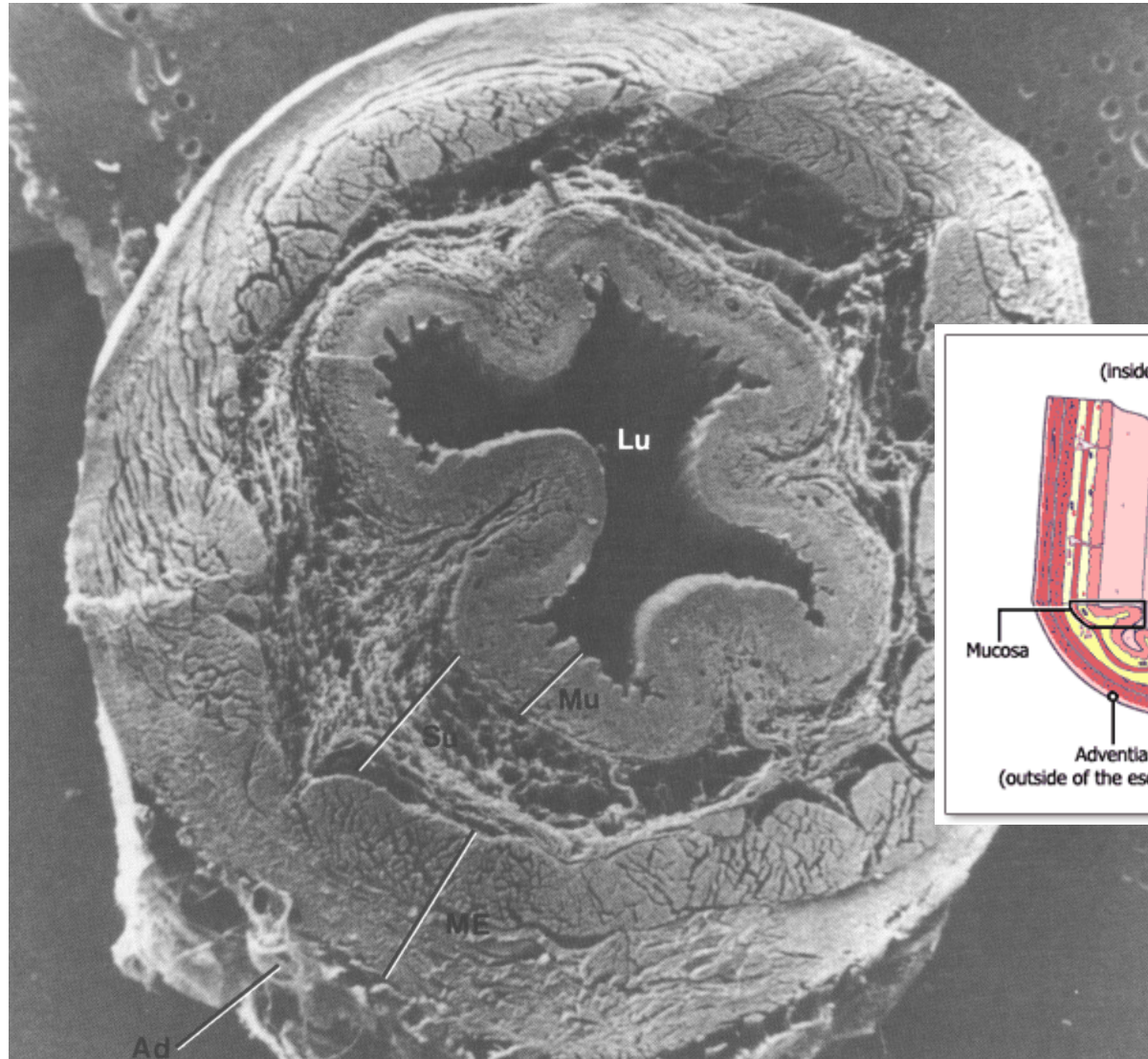


Closed esophageal
sphincter

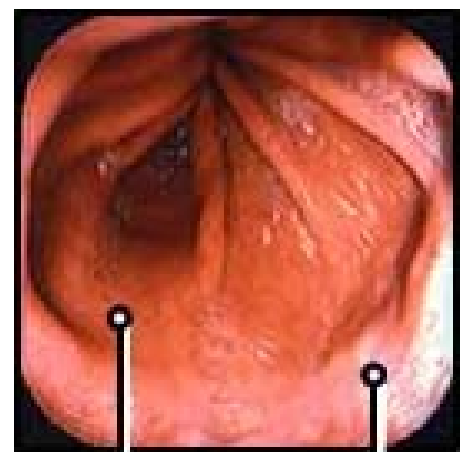
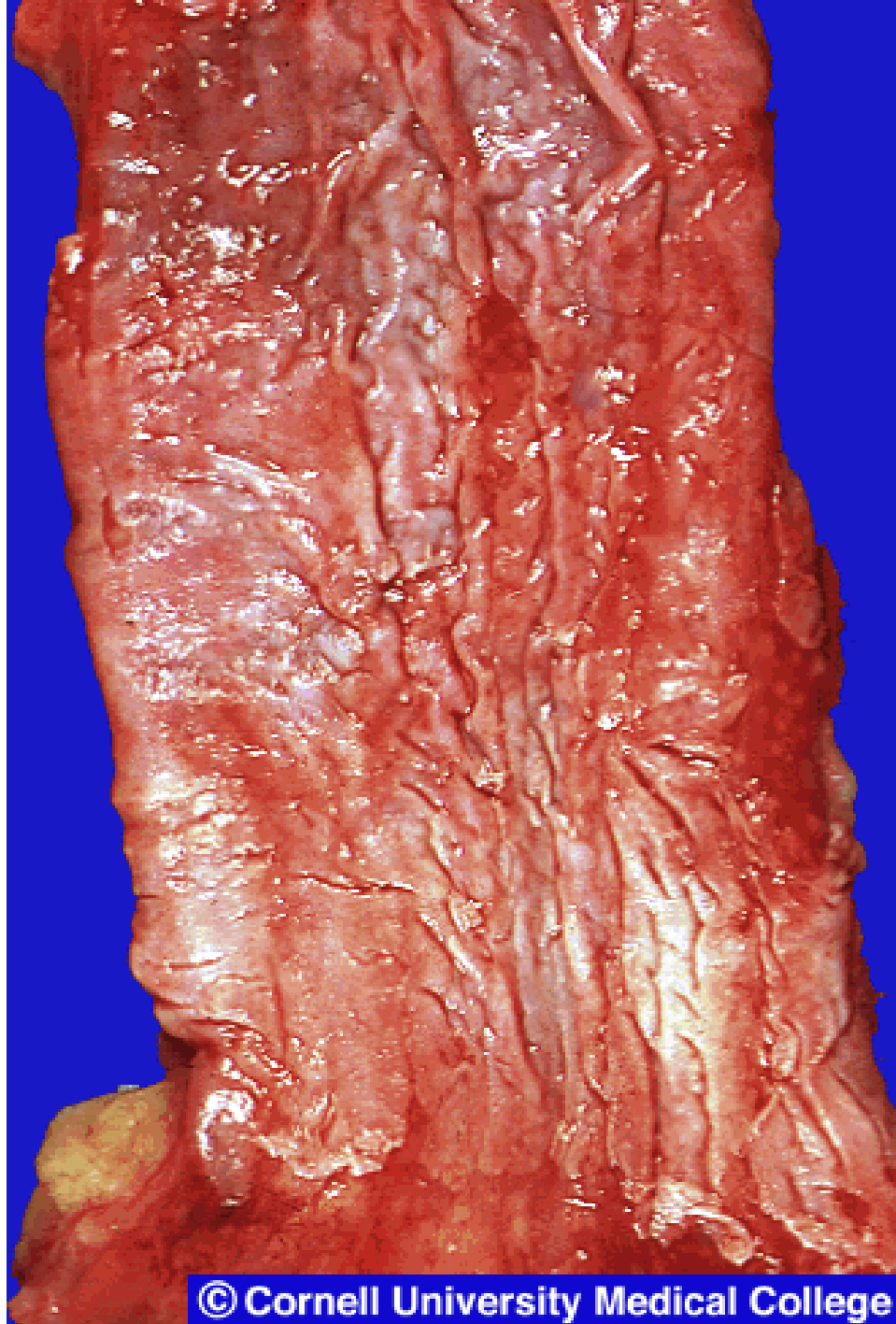


Open esophageal
sphincter

Esophagus - SEM



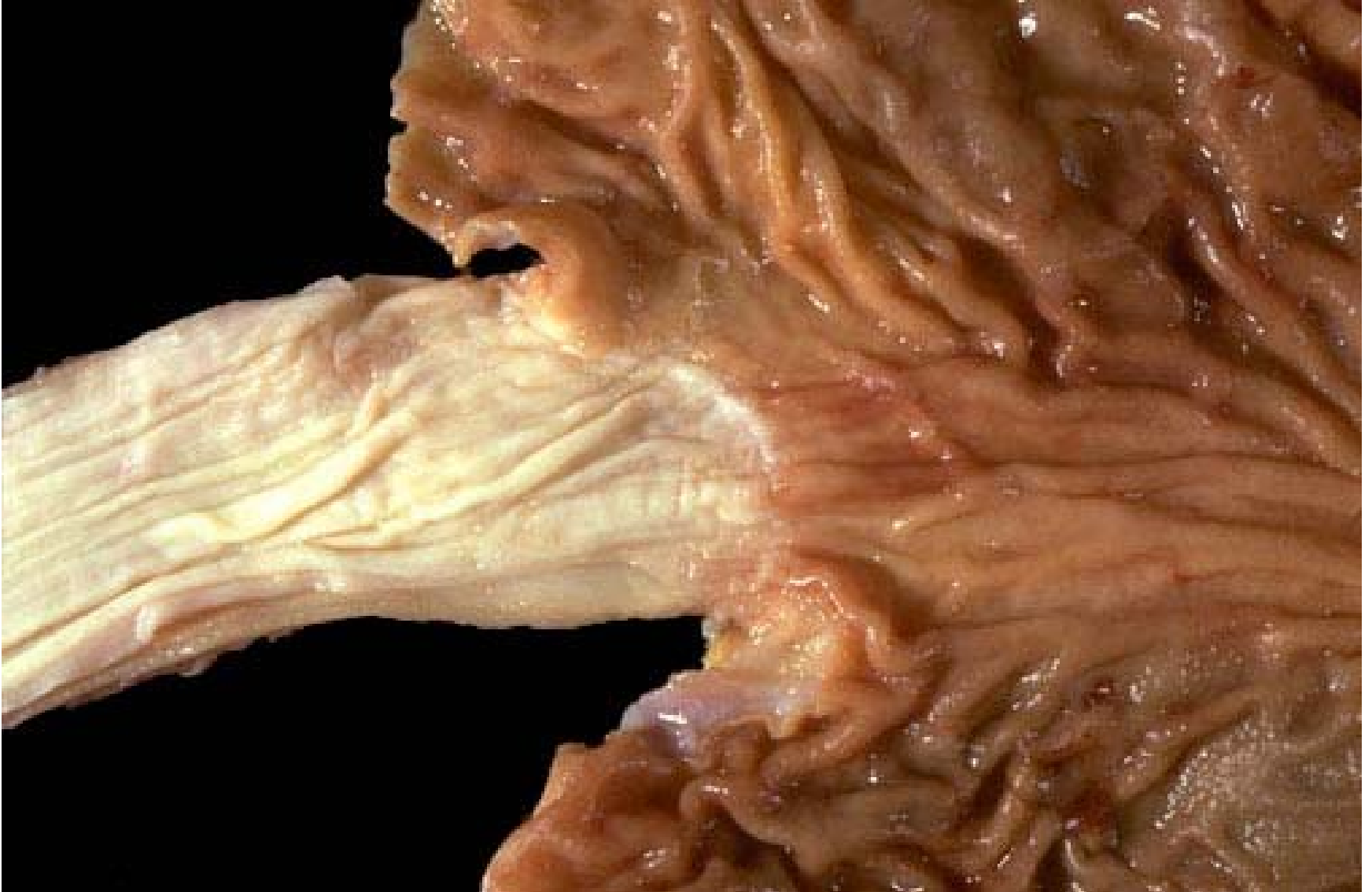The empty esophagus is collapsed and thrown into longitudinal folds.



Stomach
side

Esophageal
side

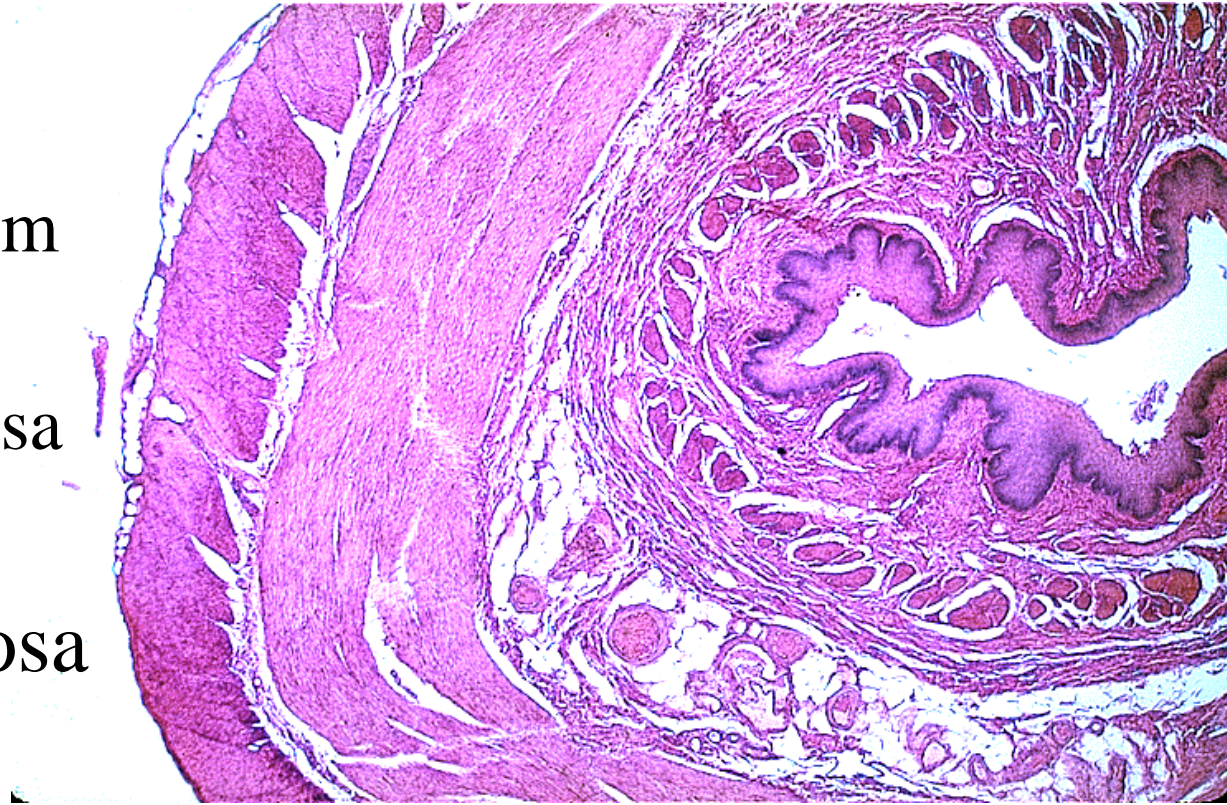
Esophageal Stomach Junction



Esophagus

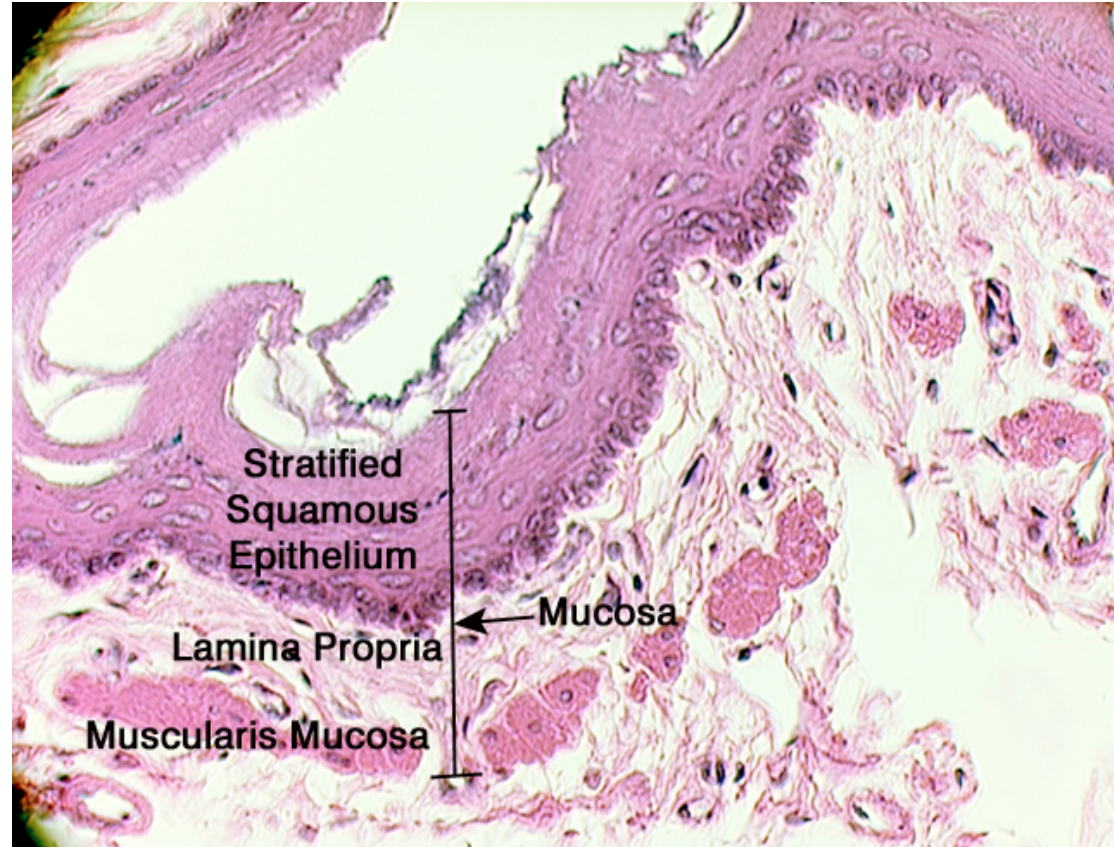
General Structure

- Mucosa
 - Lining epithelium
 - Lamina propria
 - Muscularis mucosa
- Submucosa
- Adventitia or serosa

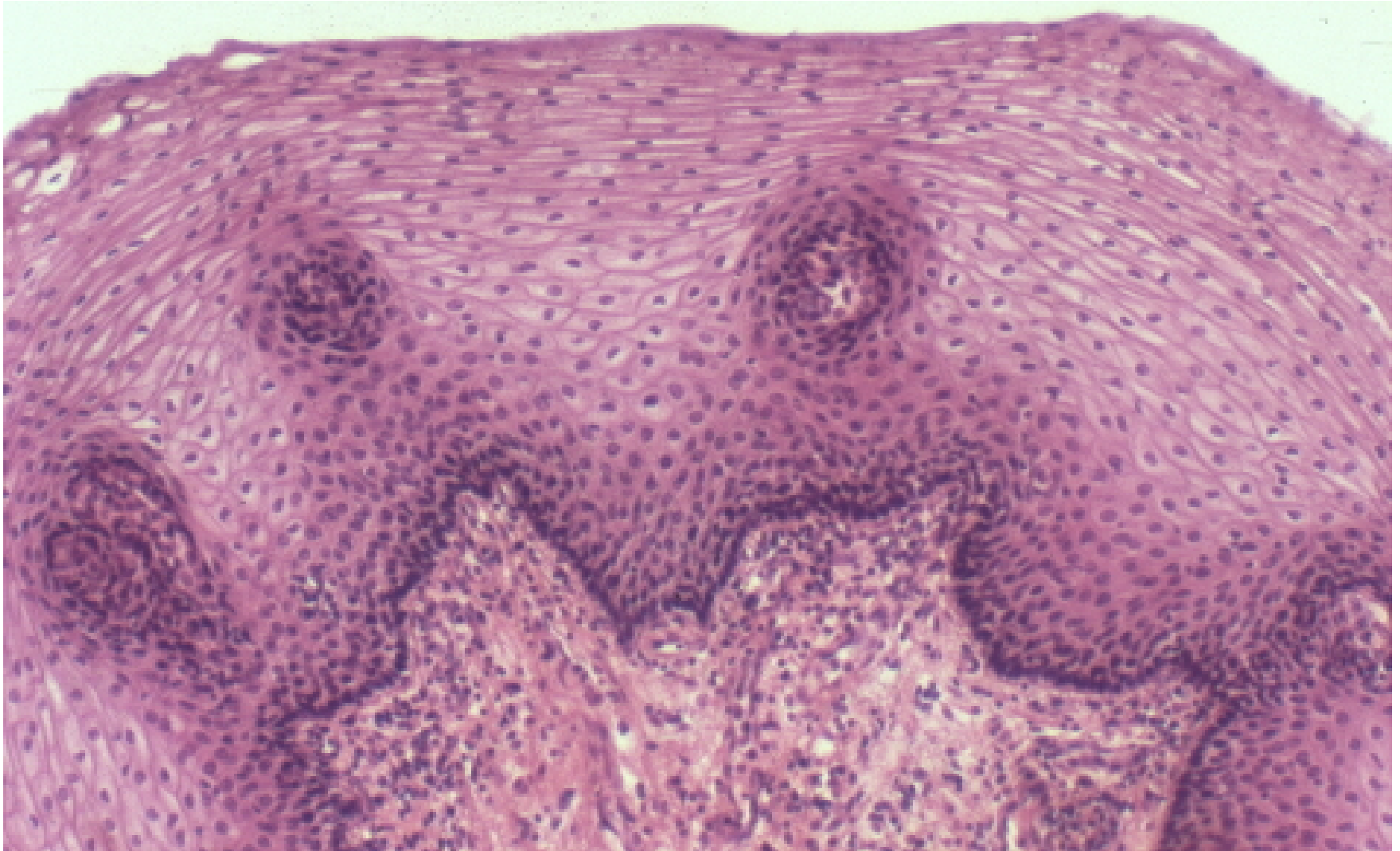


Esophagus: Mucosa

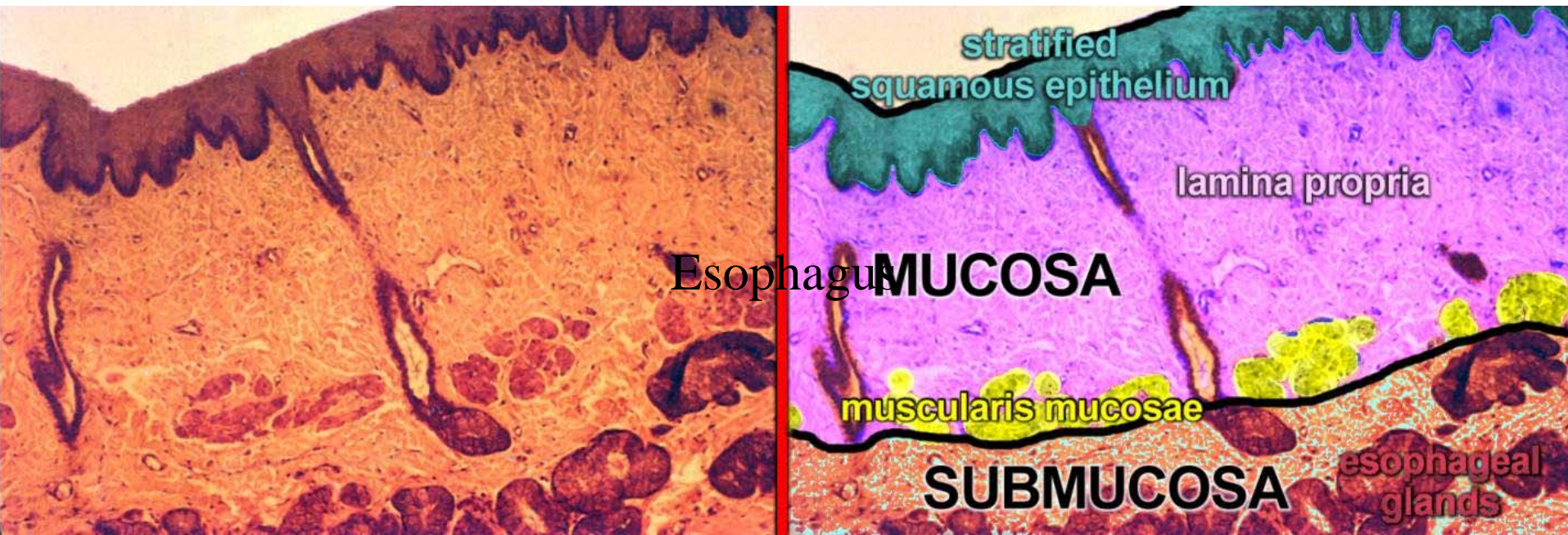
- The inner lining consist of thick stratified squamous non-keratinizing epithelium
- Thin lamina propria contains fine connective tissue
- Muscularis mucosa mostly longitudinally-oriented smooth muscle bundles.



Esophagus: Epithelium



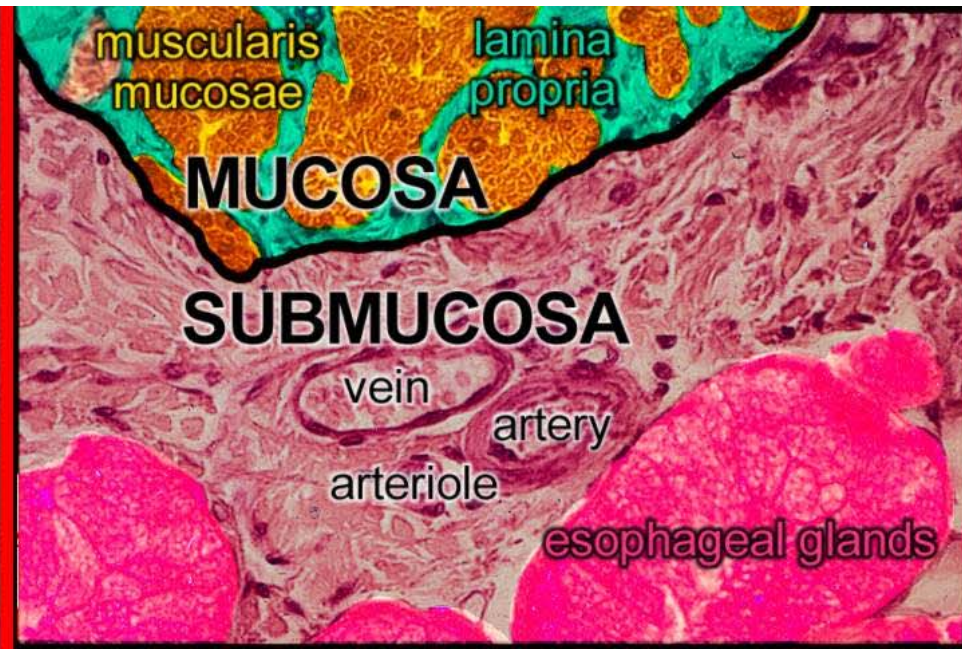
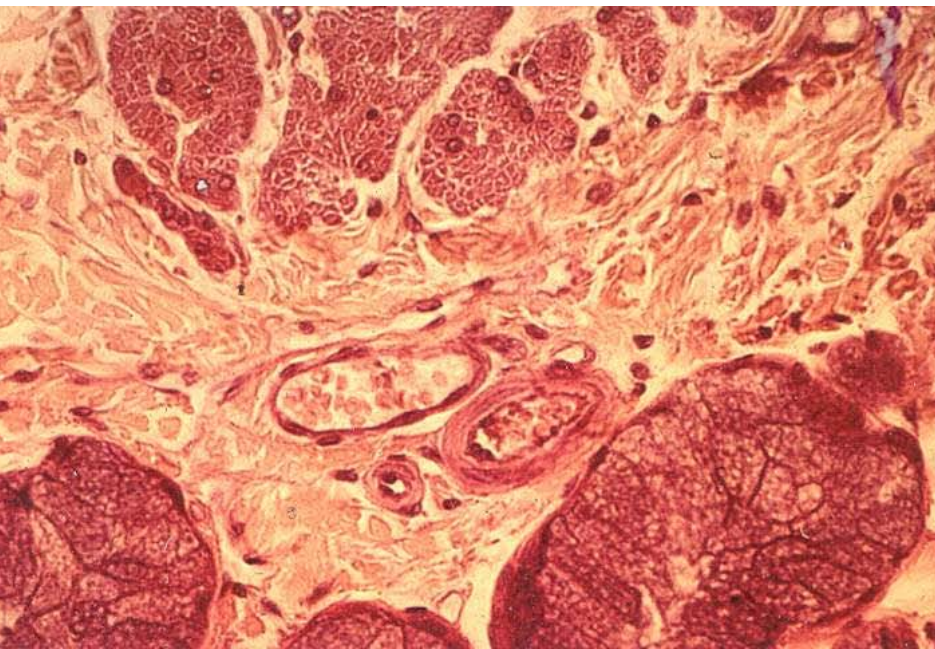
Esophagus

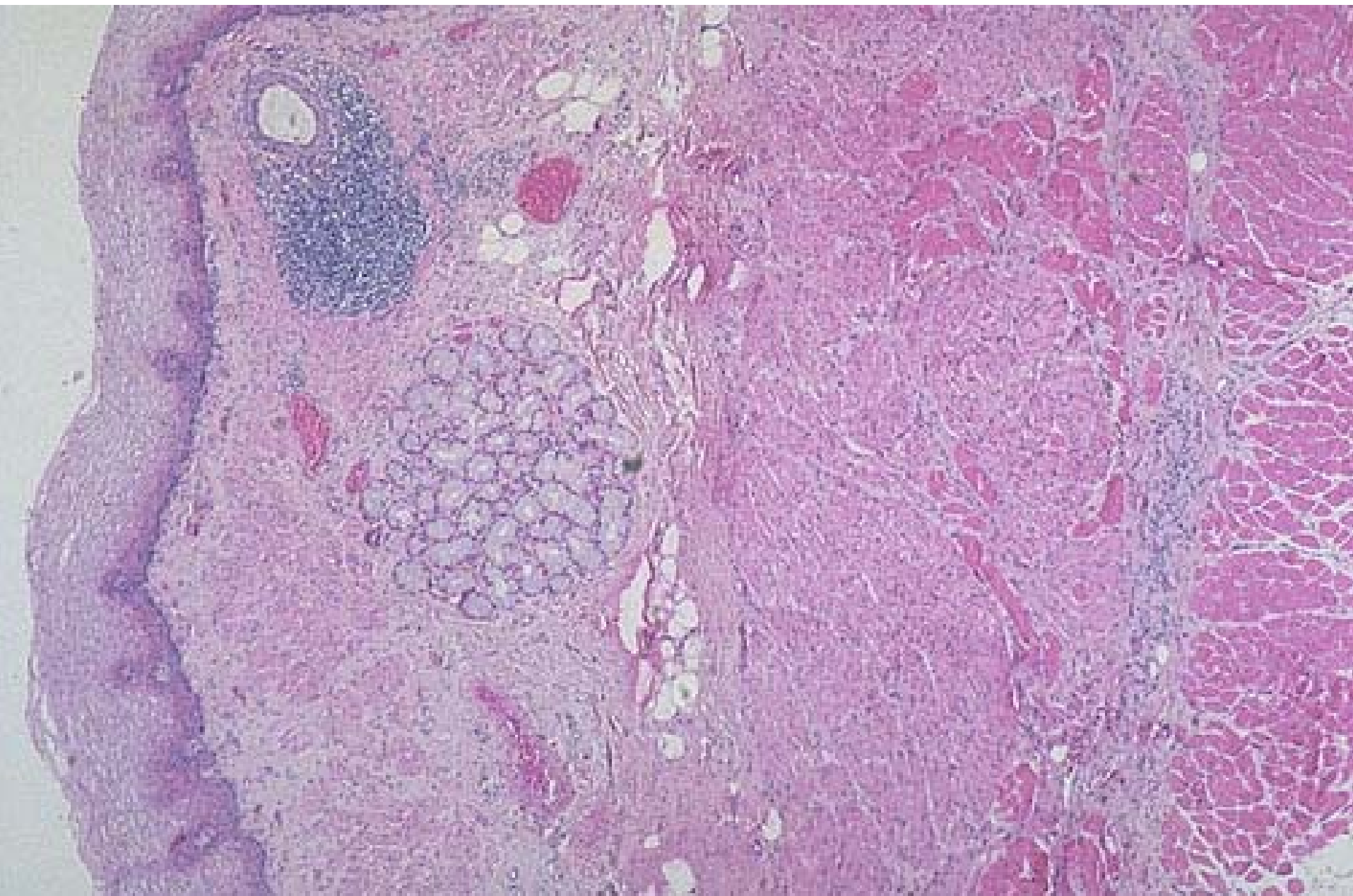


Esophagus: Submucosa

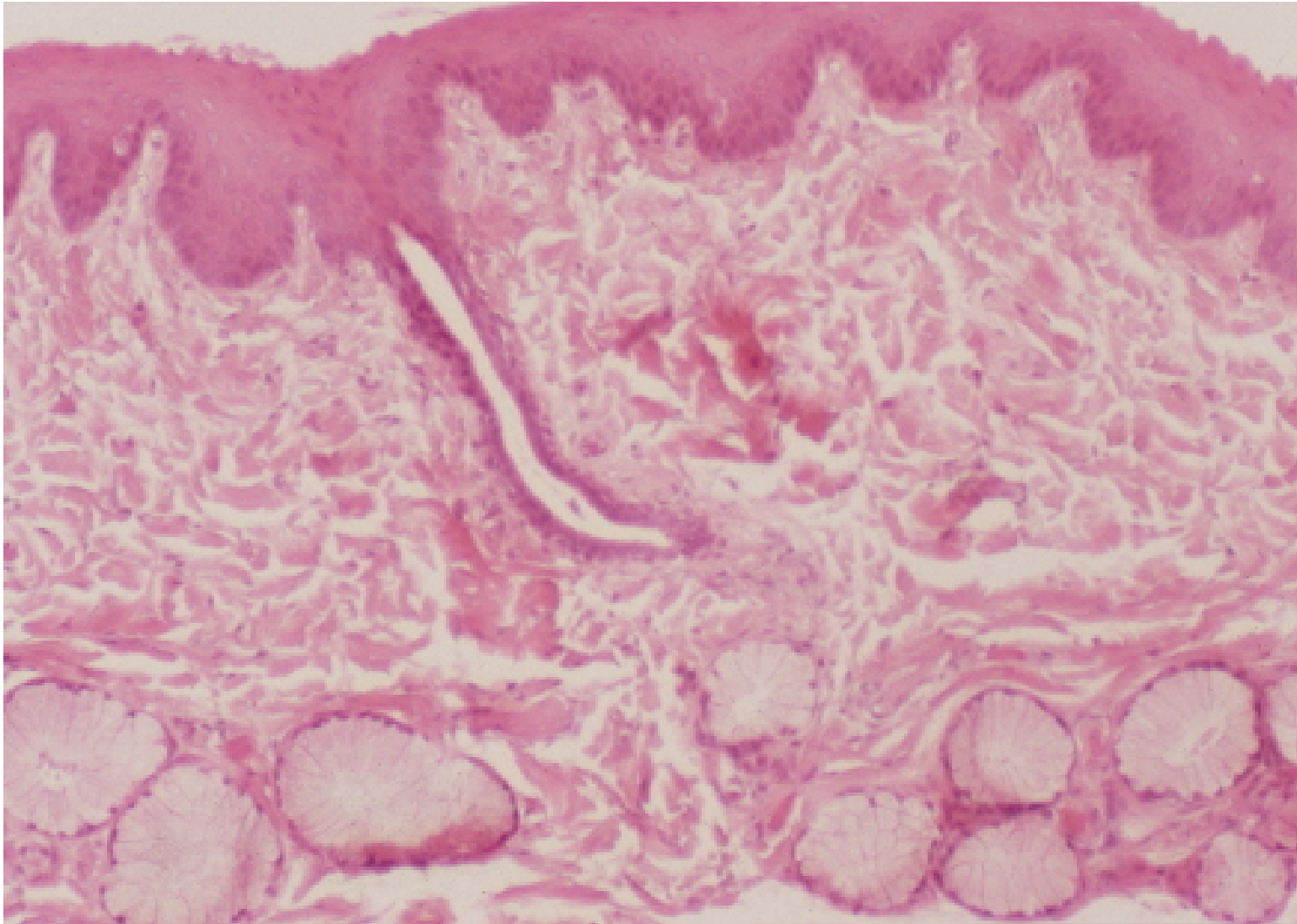
- Mucus secreting glands may be found in the submucosa.
- Due to their position, they are known as **submucosal glands** or as **esophageal glands proper**
 - Excretory ducts pass through the muscularis mucosa and lamina propria to open into the esophageal lumen

Esophagus

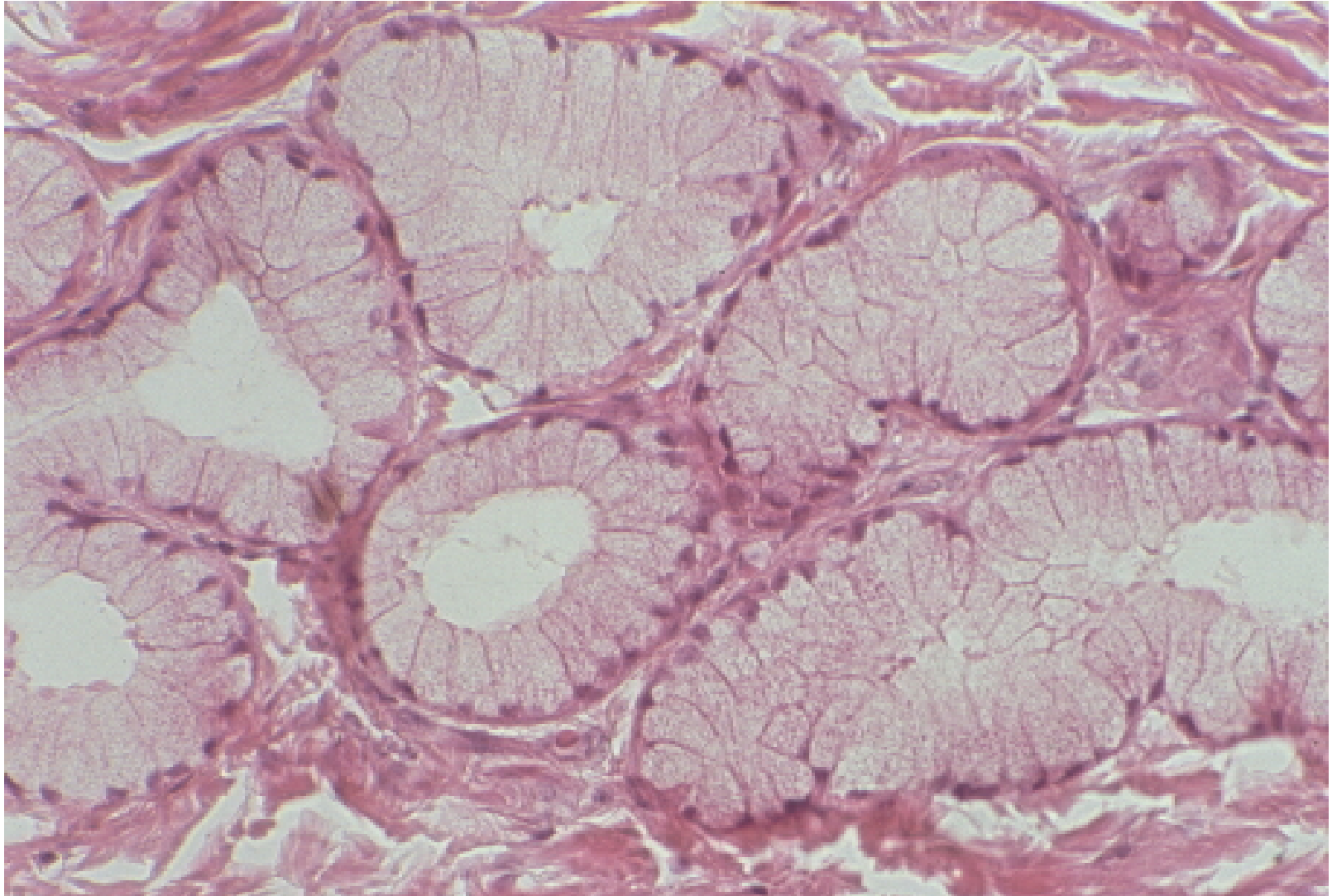




Esophagus: Submucosal Glands



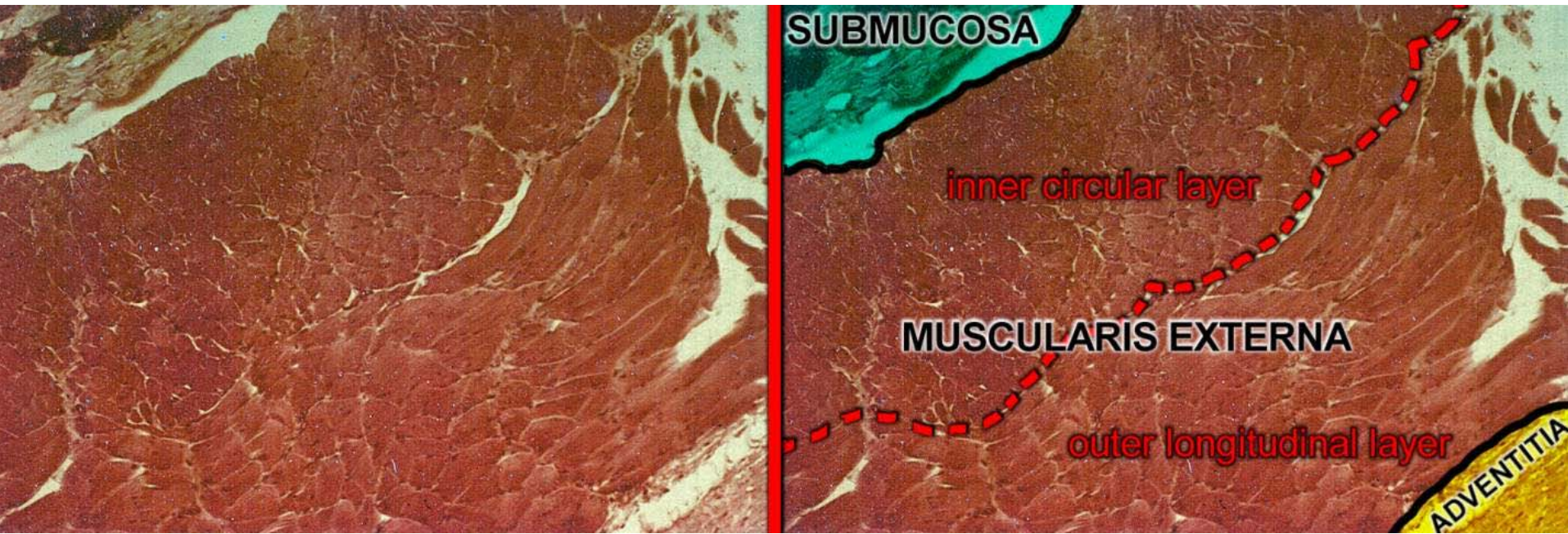
Esophagus: Submucosal Glands



Esophagus: Muscularis Externa

- Composed of skeletal muscle in the upper one-third
- A mixture of skeletal and smooth muscle in the middle one-third
- Only smooth muscle in the lower one-third

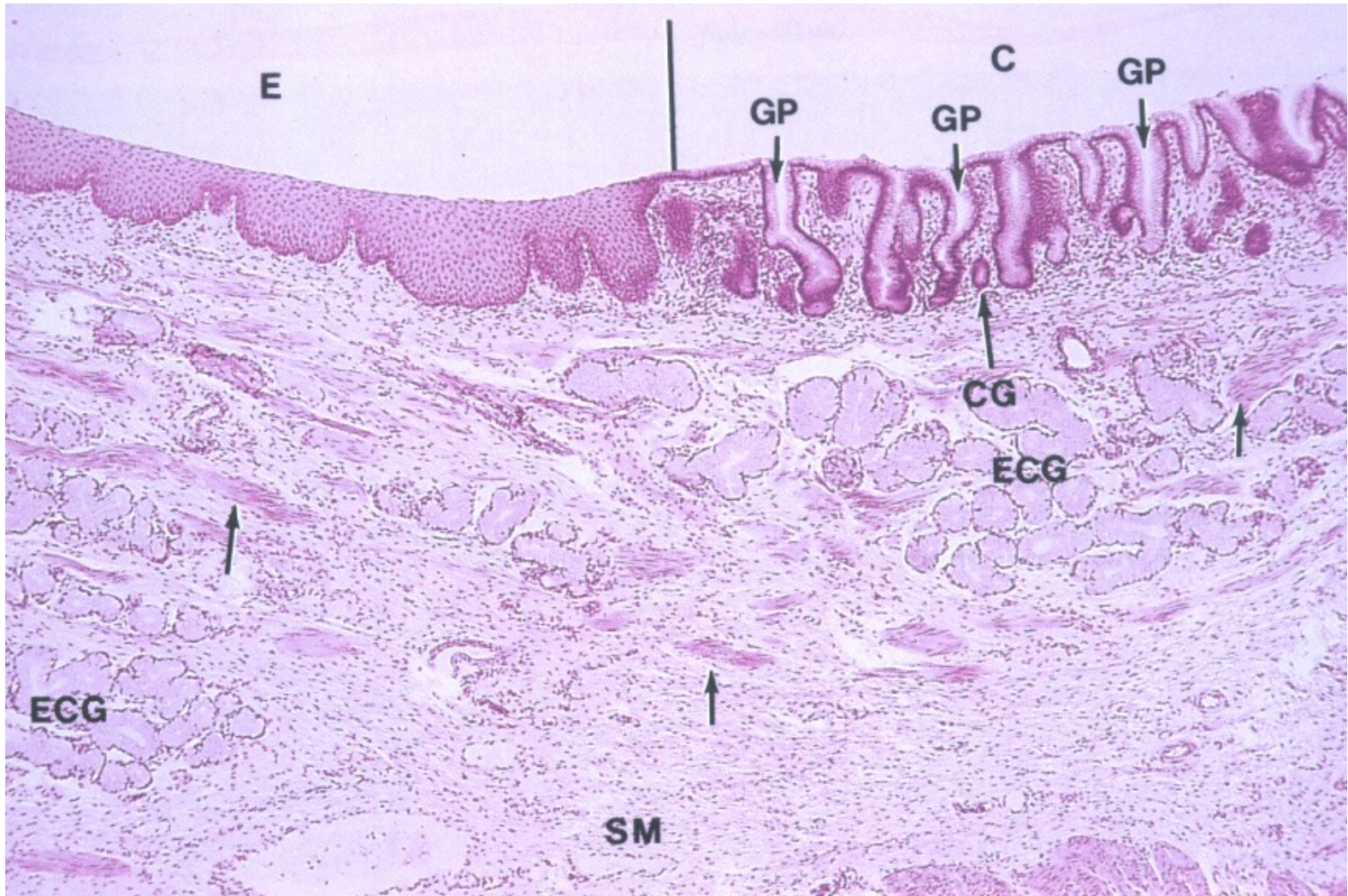
Esophagus



Esophagus: Adventitia/Serosa

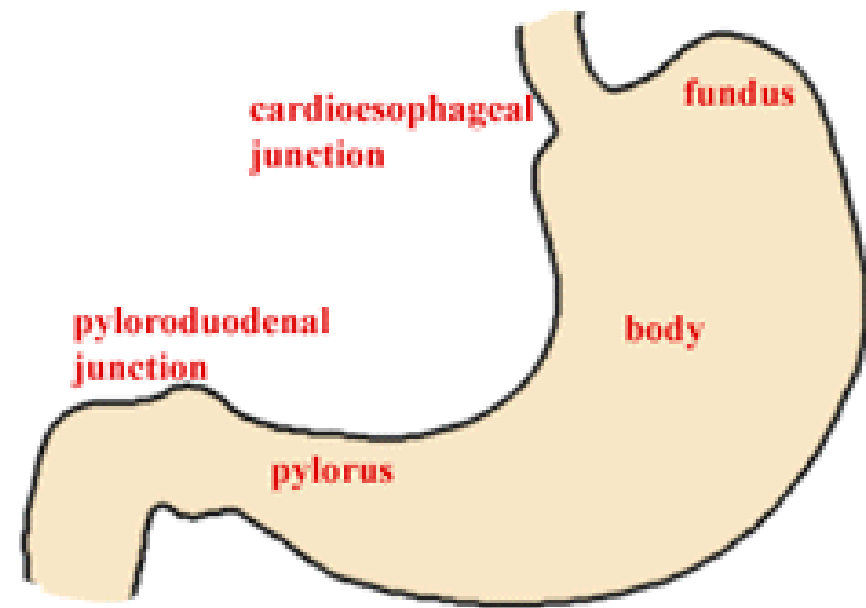
- The outermost layer of the *thoracic* esophagus is adventitia
- After passing through the diaphragm the outermost layer becomes a serosa

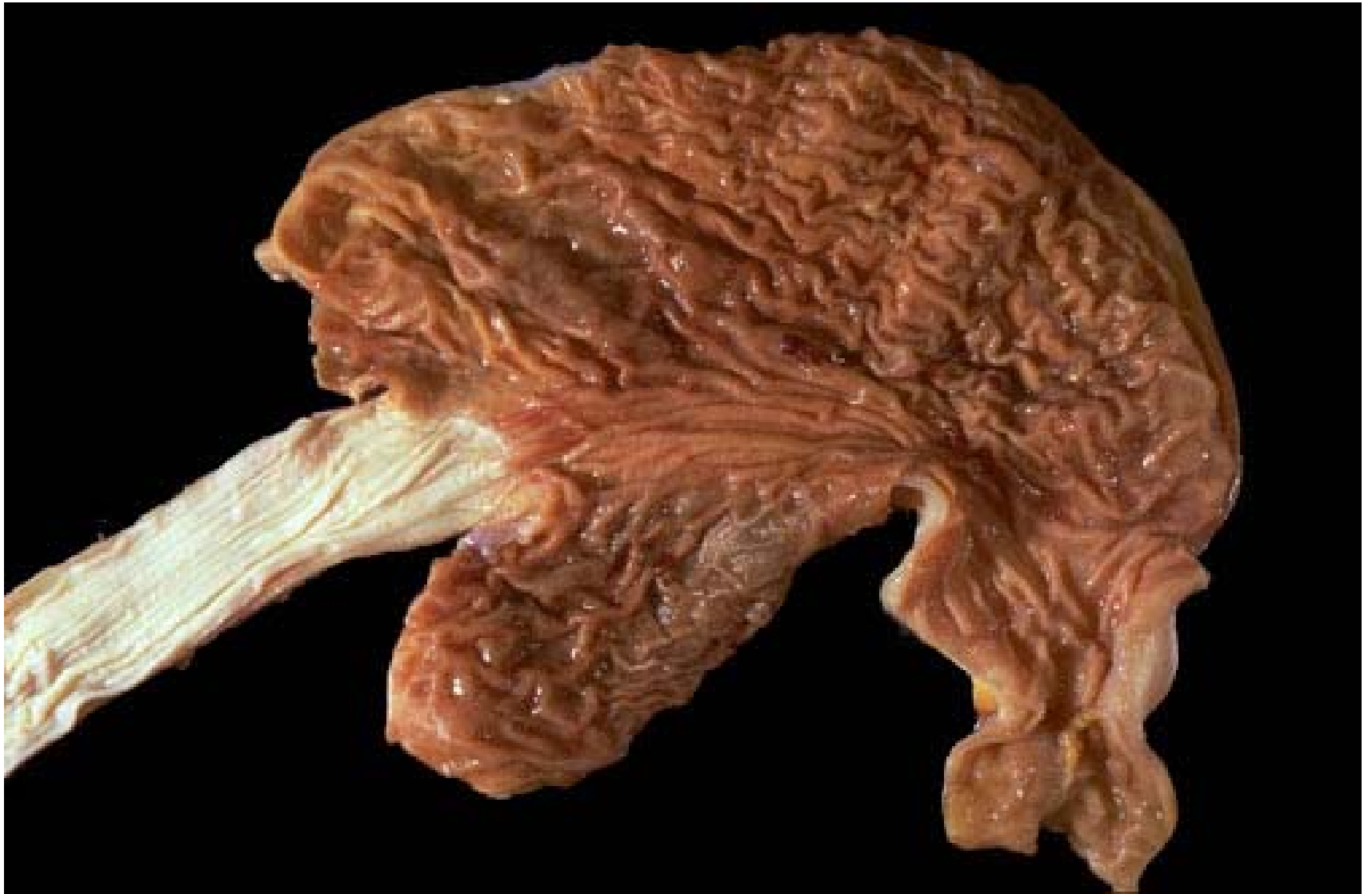Esophageal Stomach Junction

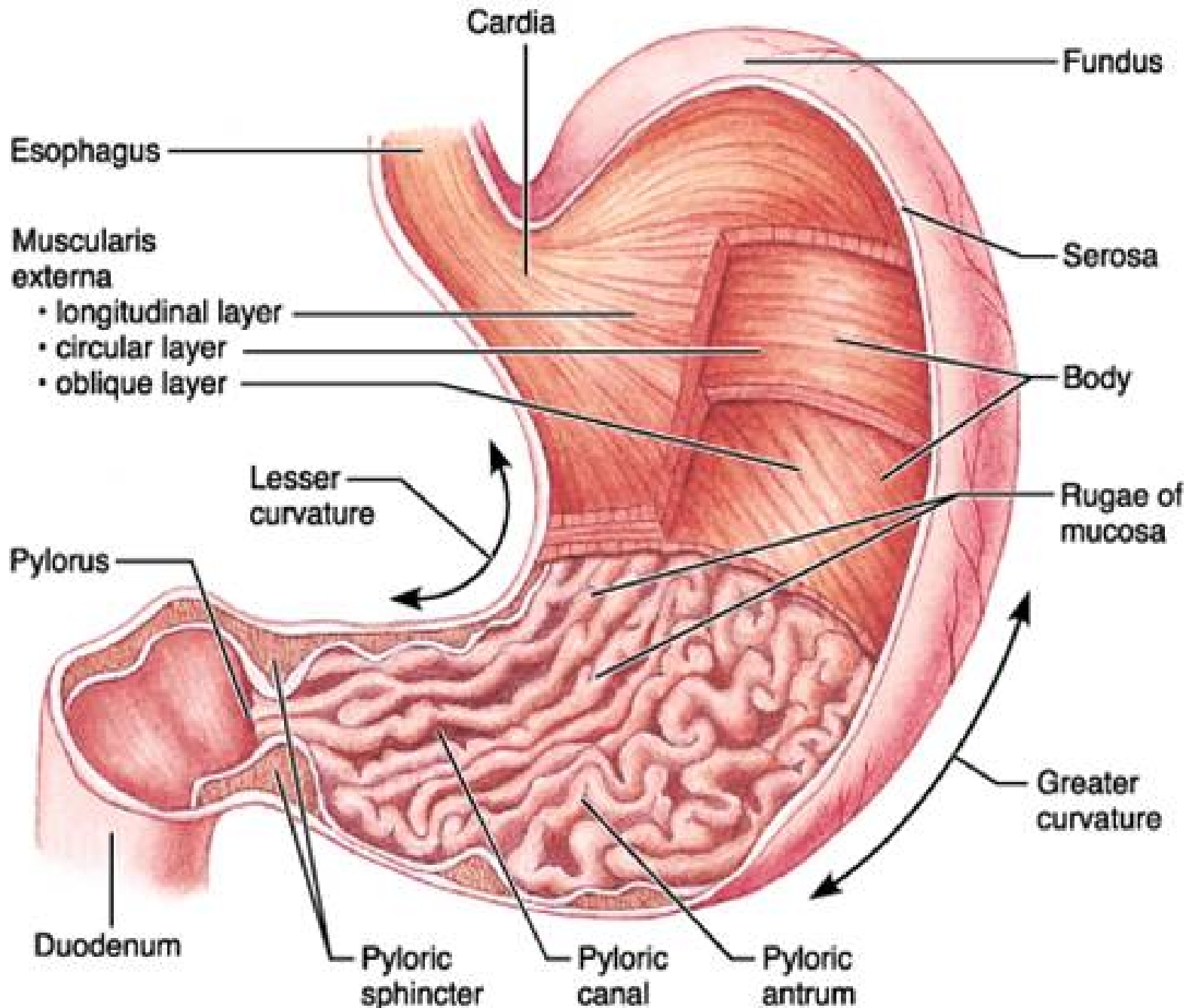


Stomach

- Food storage, mixing, and acidic breakdown for subsequent absorption in the small intestine.
- The stomach is anatomically subdivided into four zones –
 - Cardia
 - Fundus
 - Body
 - Pylorus.

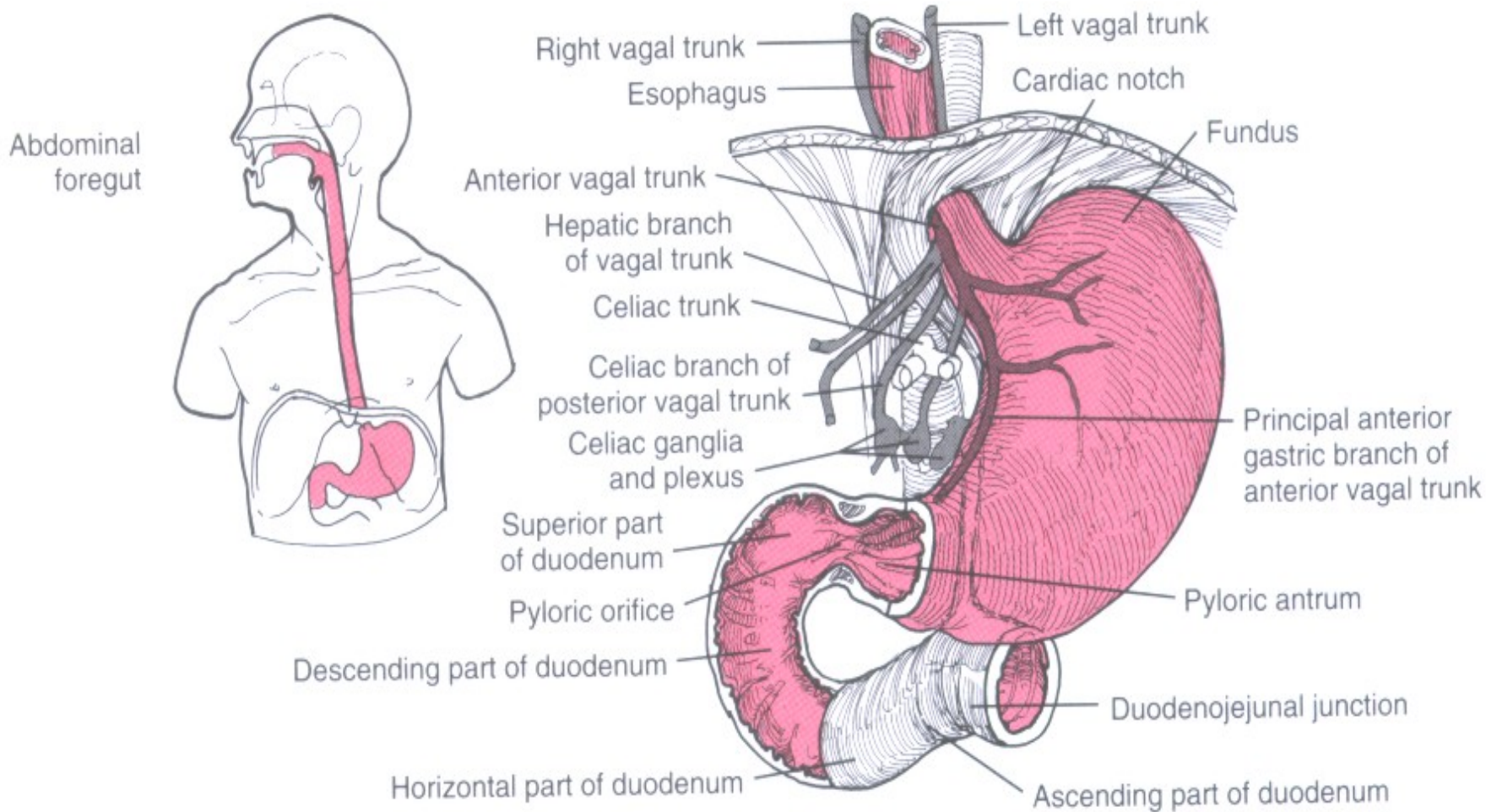






(Gastroduodenal)

Esophagus and Stomach



Stomach: Blood Supply

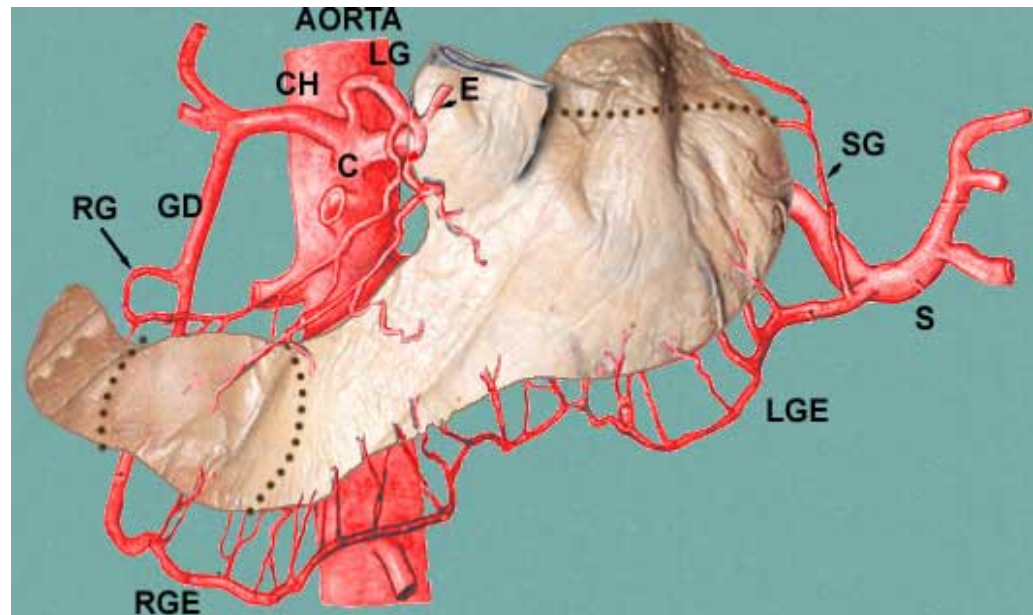
- The arteries that supply the stomach are branches of the celiac trunk or artery. This is the first unpaired branch of the abdominal aorta, arising just after the aorta passes behind the diaphragm.

The branches of the celiac artery are three:

1. left gastric
2. splenic
3. common hepatic

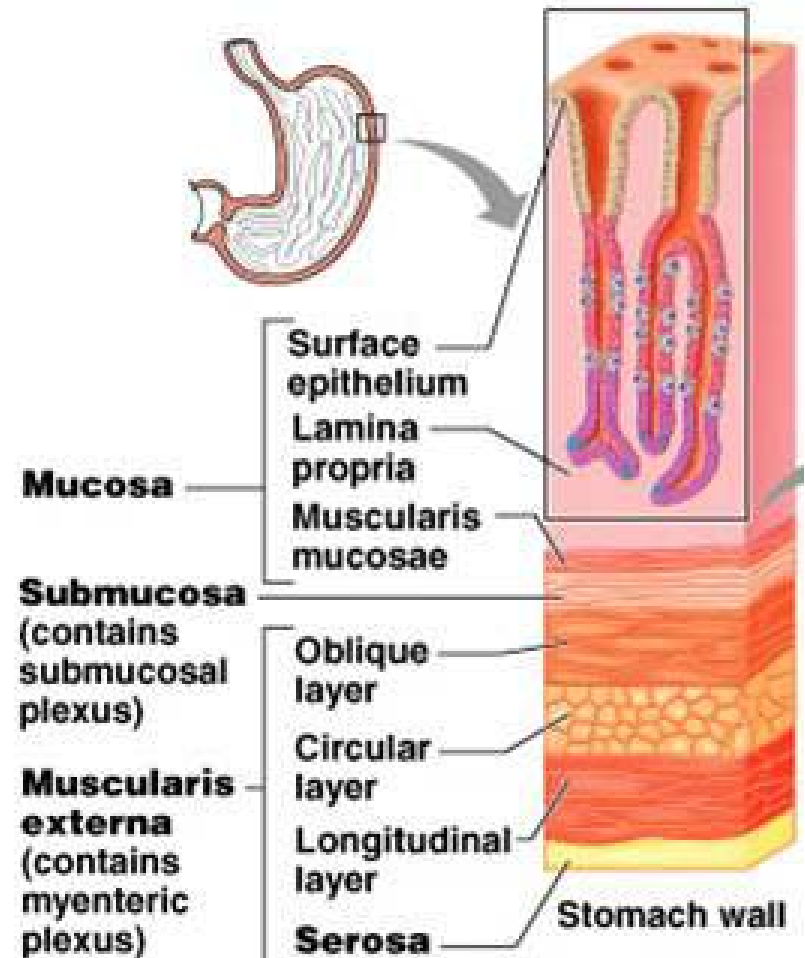
The branches to the stomach arise from the celiac (C)

- left gastric (LG) - supplies the lesser curvature of the stomach and lower esophagus
 - esophageal E
- Splenic (S) which gives rise to:
 - short gastric SG - supplies area of the fundus
 - left gastroepiploic (LGE) - supplies the left part of greater curvature of the stomach
- common hepatic (CH)
 - Gastroduodenal (GD)
 - right gastric RG - supplies right side of lesser curvature of the stomach
 - right gastroepiploic RGE - supplies the right part of the greater curvature of the stomach



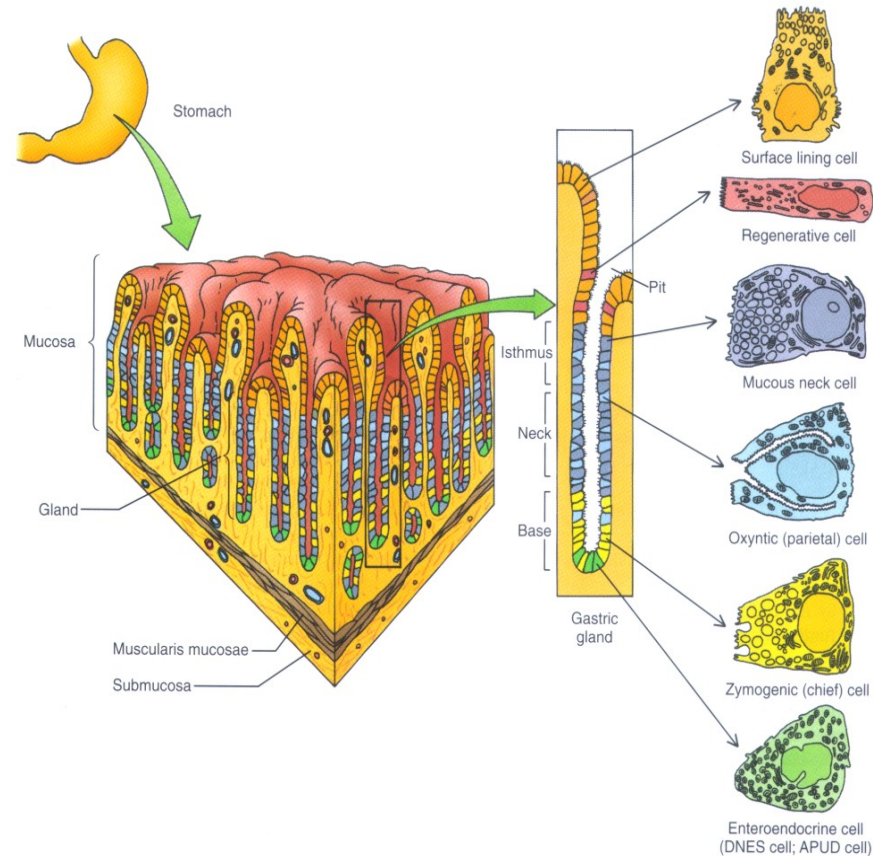
Stomach: Mucosa

- Pocked with depressions called **gastric pits**
 - Lined with simple columnar epithelium
 - Cells at bottom of pits divide and produce new cells that are sloughed off into the chyme



Stomach: Glands

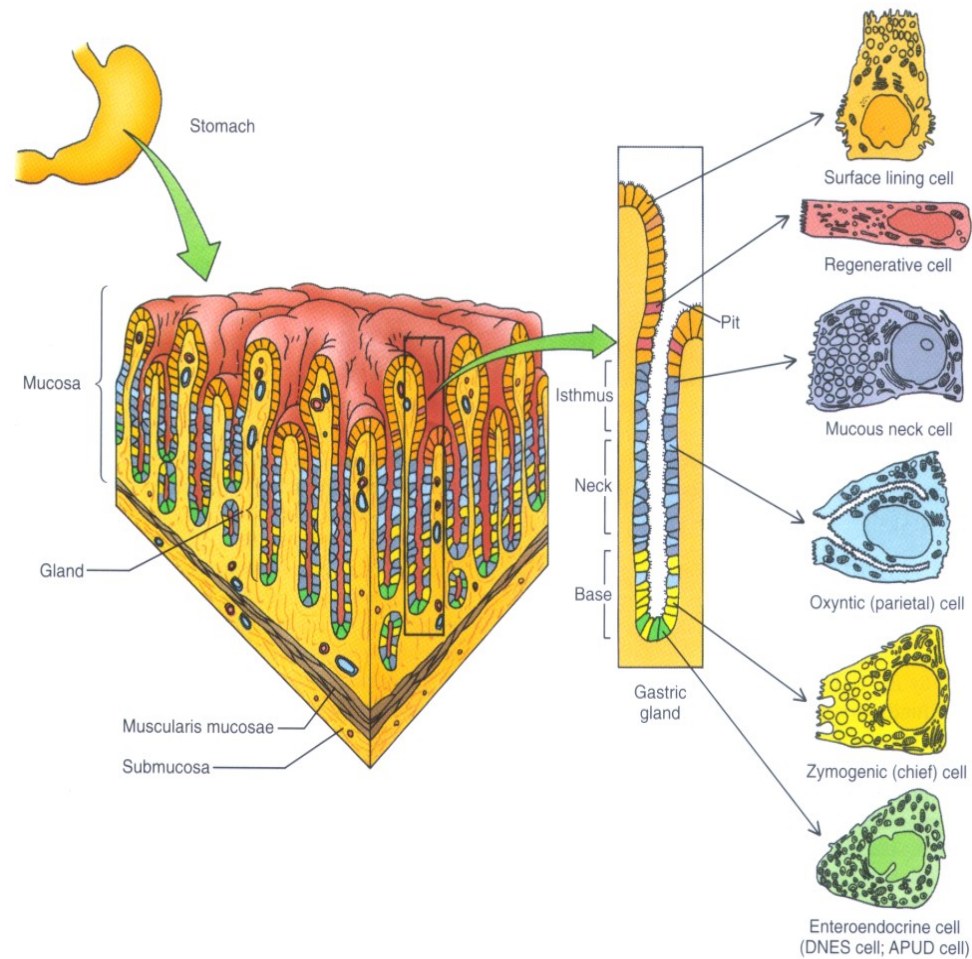
- Tubular glands open into the bottom of each gastric pit
- In the cardia and pyloric regions they are called **cardiac glands** and **pyloric glands**
- In the rest of the stomach, they are called **gastric glands**



Stomach: Glands

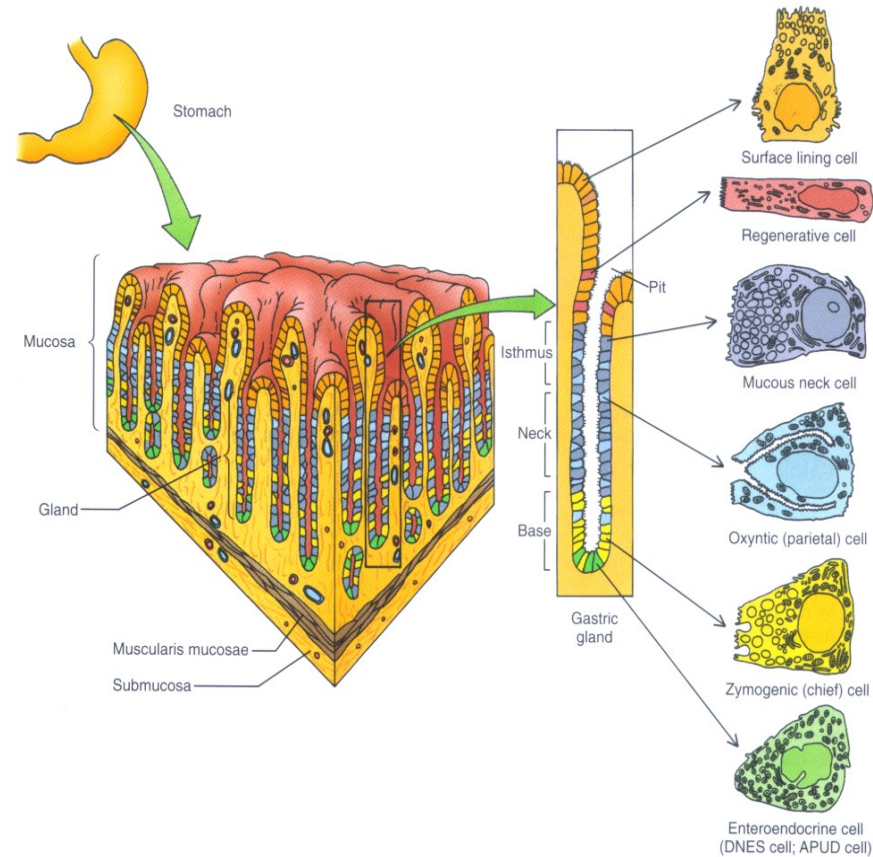
Glands differ in cellular composition but collectively they consist of the following cell types

- **Mucous cells**
 - **Secrete mucus**
 - **Predominate in the cardiac and pyloric glands**
 - In gastric glands, they are called **mucous neck cells** and are concentrated in the narrow neck of the gland where it opens into the pit



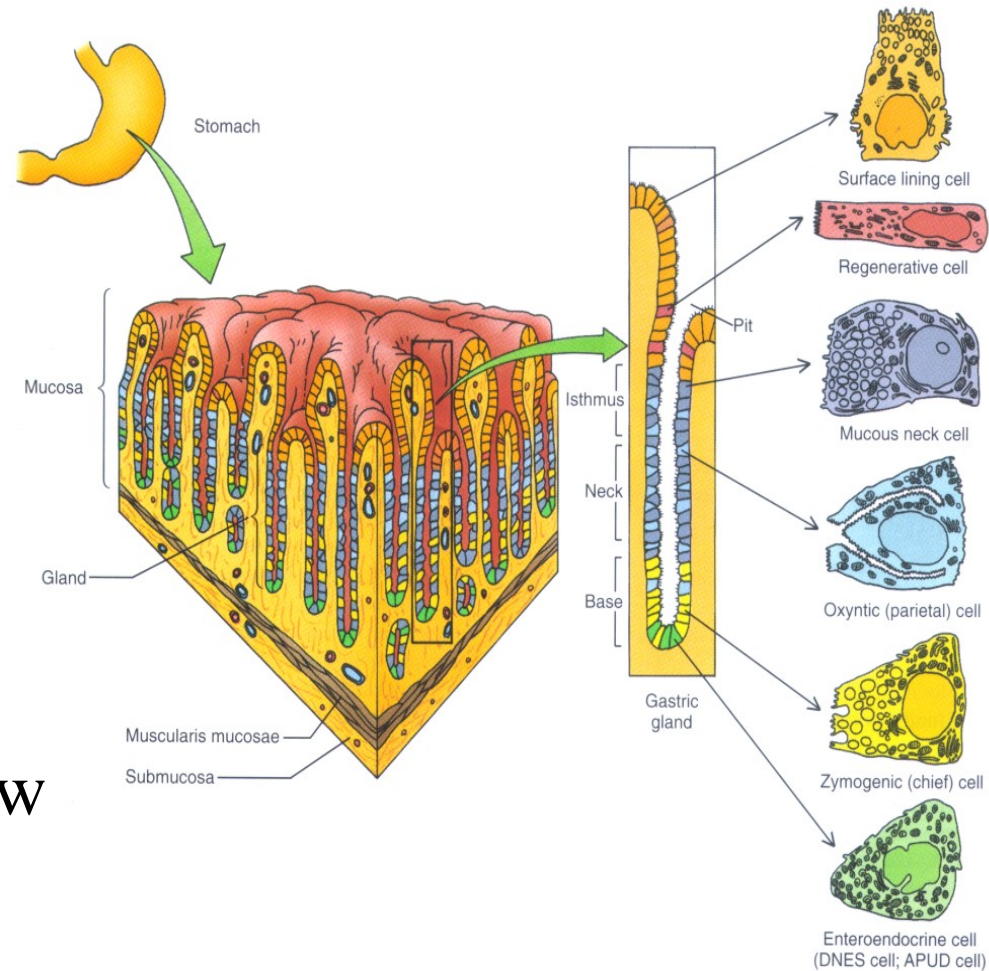
Stomach: Glands

- **Regenerative (stem) cells**
 - Found in the base of the pit and neck of gland
 - Undergo mitosis to produce new cells
 - Newly generated cells migrate up as well as downward into the glands to replace cells that die



Stomach: Glands

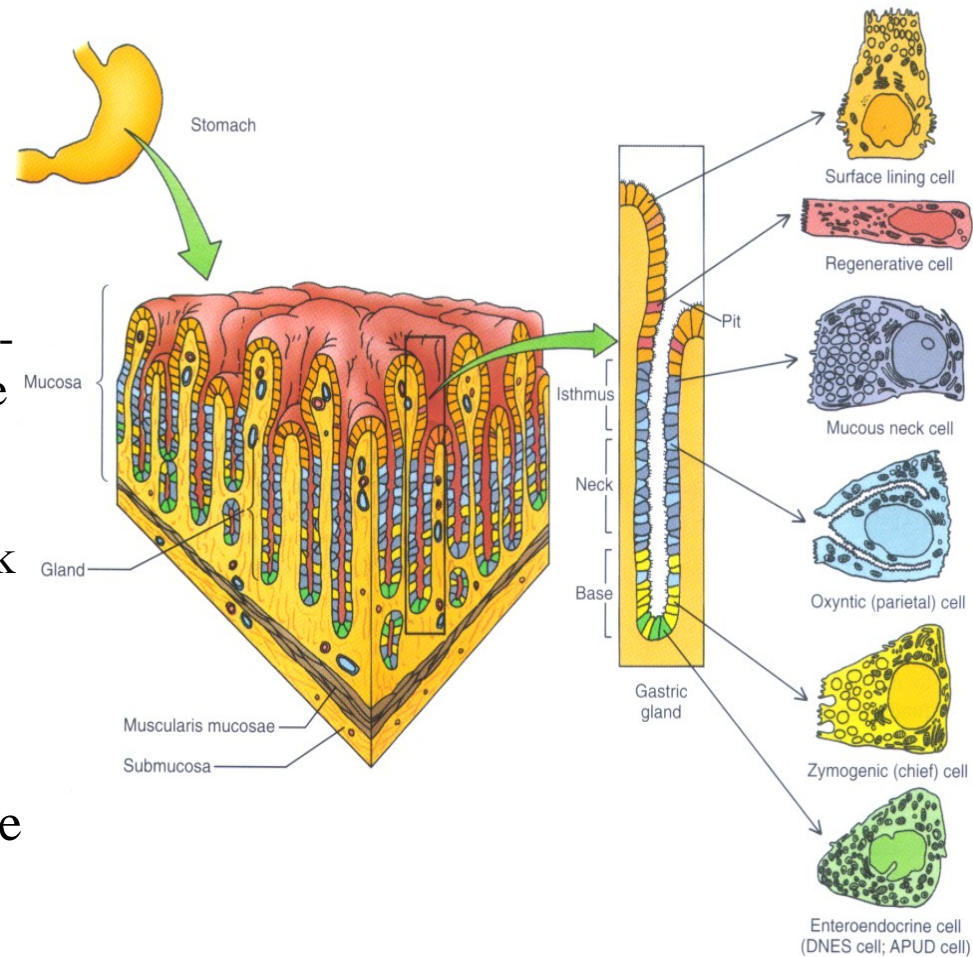
- **Parietal cell**
 - Found mostly in the upper half of the gland
 - **Secrete HCl and intrinsic factor**
 - Found mostly in the gastric glands, but a few occur in the pyloric glands



Stomach: Glands

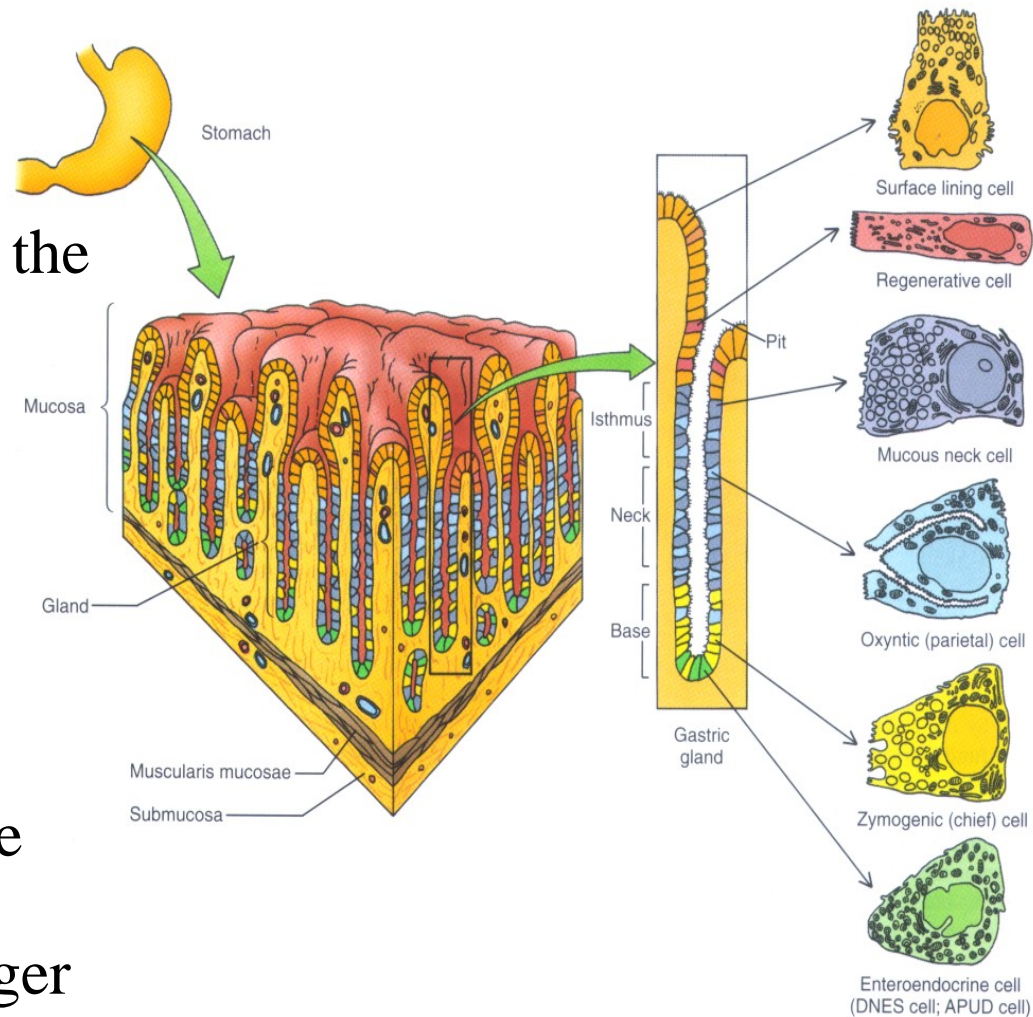
- **Chief Cells**

- Are the **most numerous**
- Secreted in infancy
 - **Chymosin** (also known as rennin)- is a proteolytic enzyme whose role in digestion is to curdle or coagulate milk in the stomach
 - **Lipase**- digest the butterfat of milk
- **pepsinogen**
 - secretes throughout life
 - Activated to pepsin by HCl
- They dominate the lower half of the gastric glands but are absent from cardiac and pyloric glands



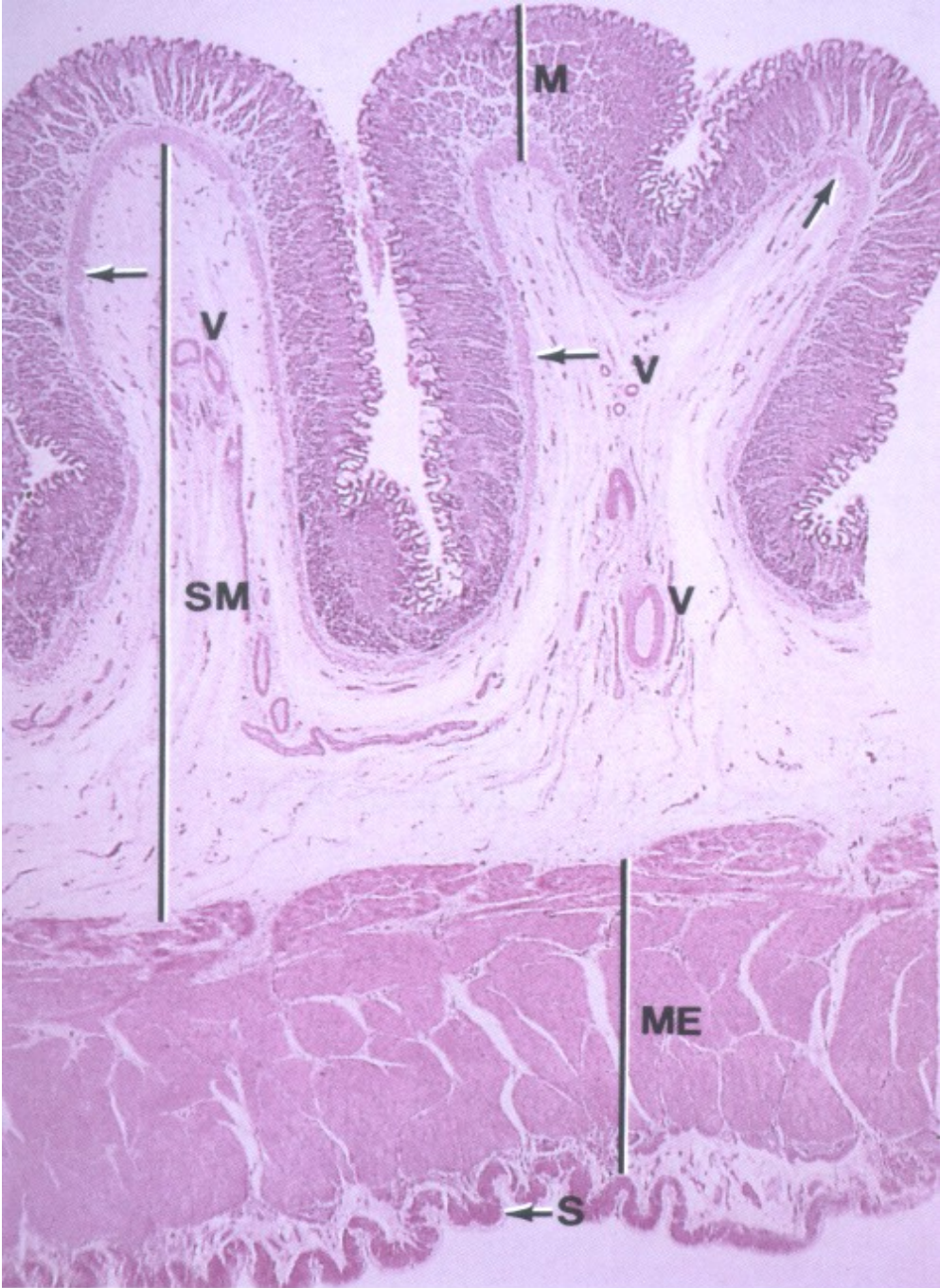
Stomach: Glands

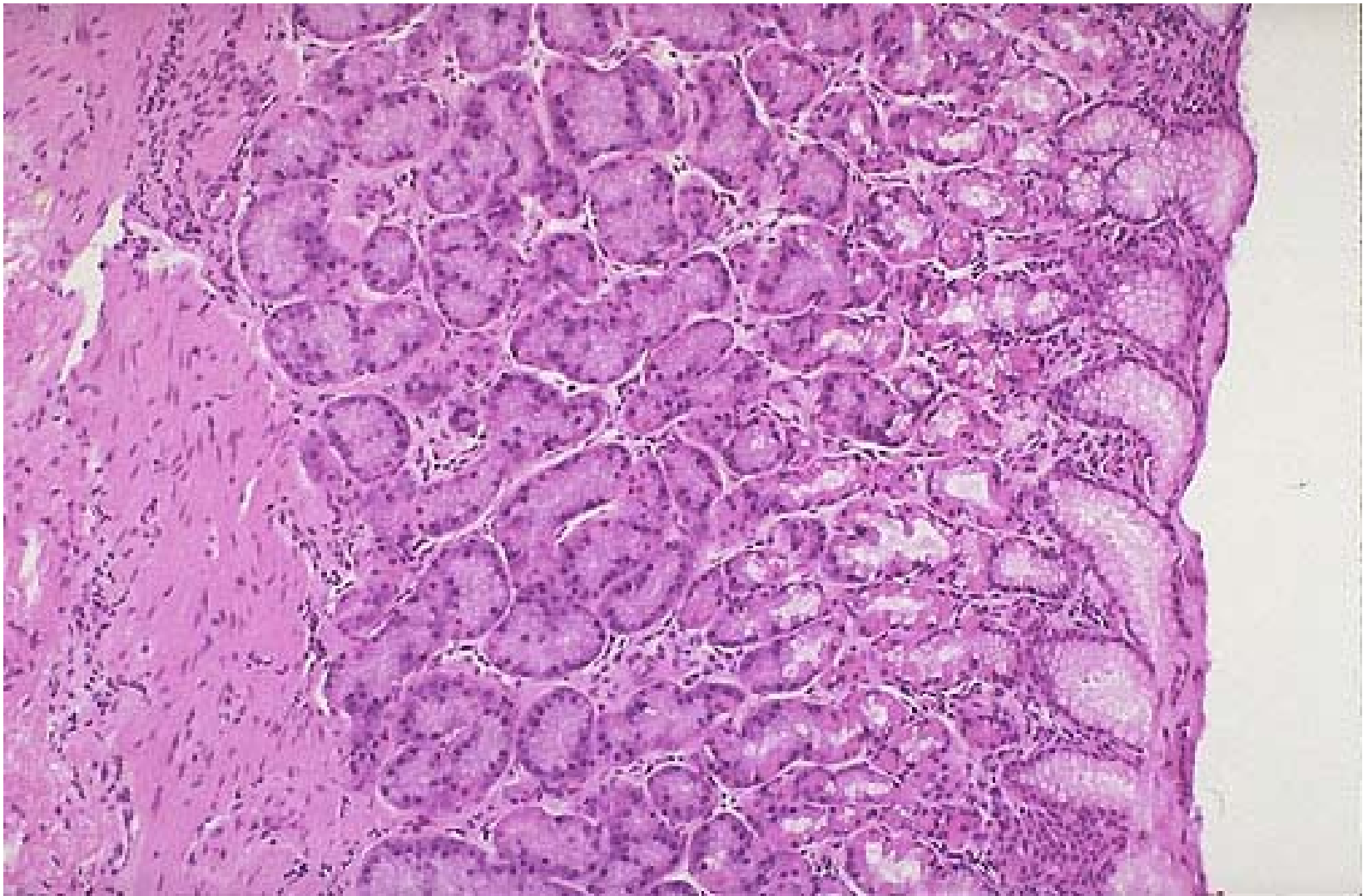
- **Enteroendocrine cells**
 - Concentrated especially in the lower half of glands throughout the stomach
 - Secrete hormones and paracrine messengers that regulate digestion
 - There are at least eight different kinds of enteroendocrine cells in the stomach, each producing a different chemical messenger



Stomach

Rugae- gastric folds





This is the normal appearance of the gastric fundal mucosa, with short pits lined by pale columnar mucus cells leading into long glands which contain bright pink parietal cells that secrete hydrochloric acid.

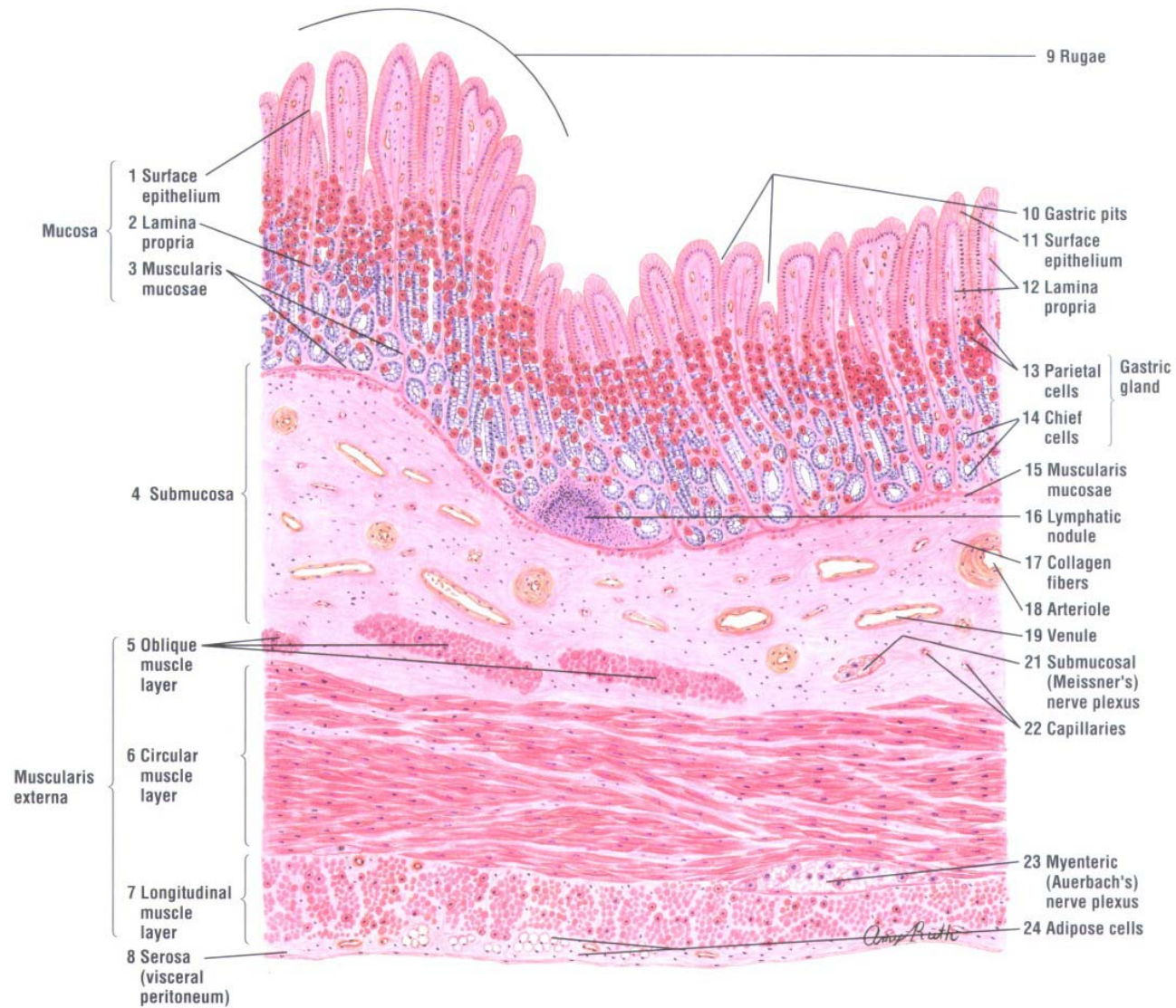
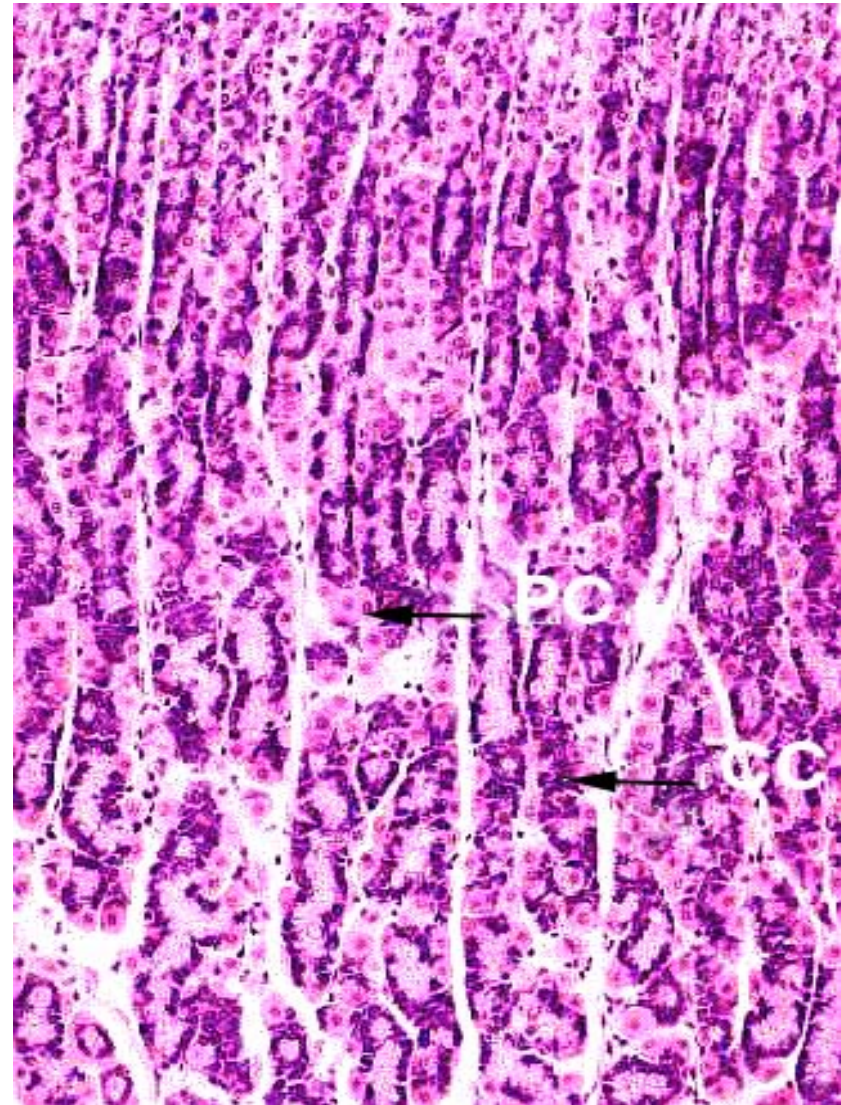


Fig. 11-6 Stomach: Fundus and Body Regions (transverse section). Stain: hematoxylin-eosin. Low magnification.

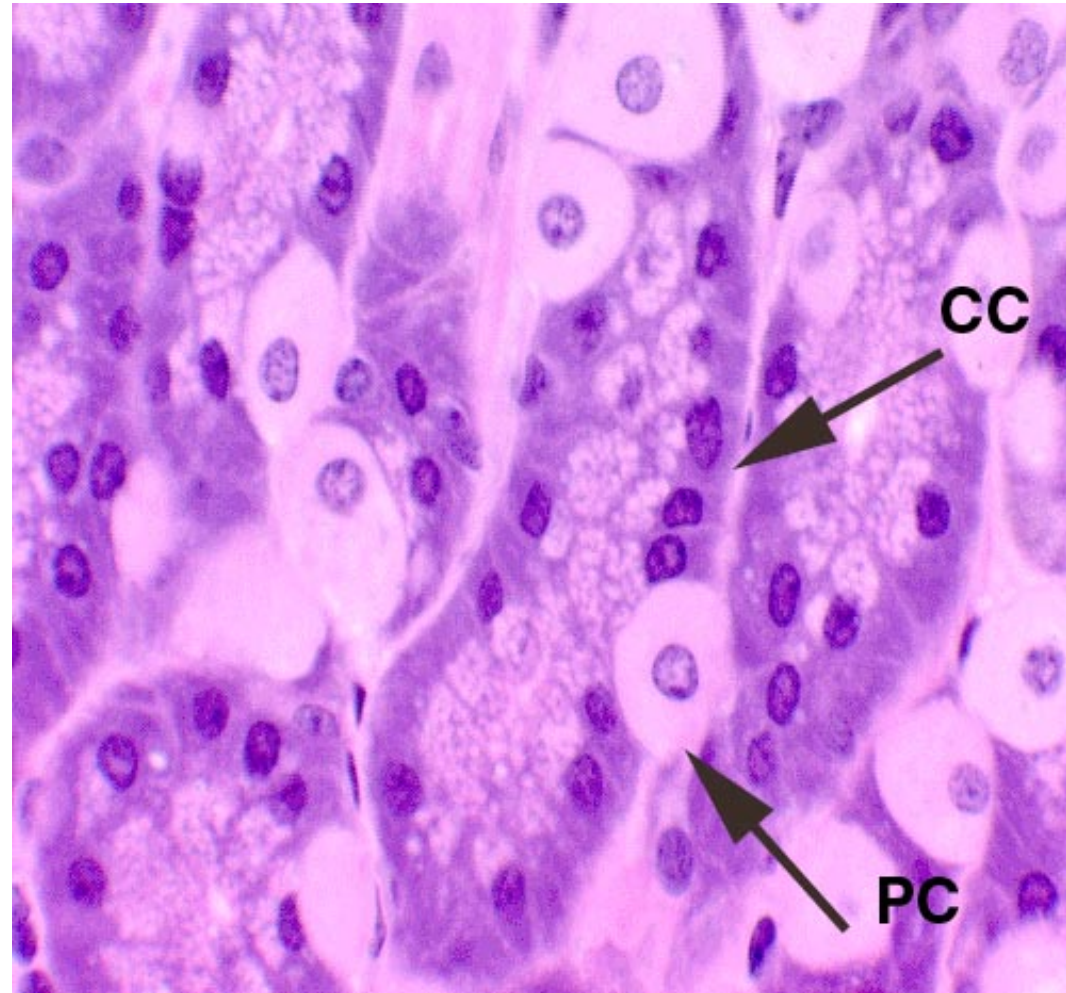
Histology: Stomach

- The **parietal cells** (Oxyntic Cells) are easily seen as large, eosinophilic cells scattered in a background of more basophilic chief cells.
- These are very easy to identify because they look like "fried eggs",
- the other type of cells are **Chief Cells,**

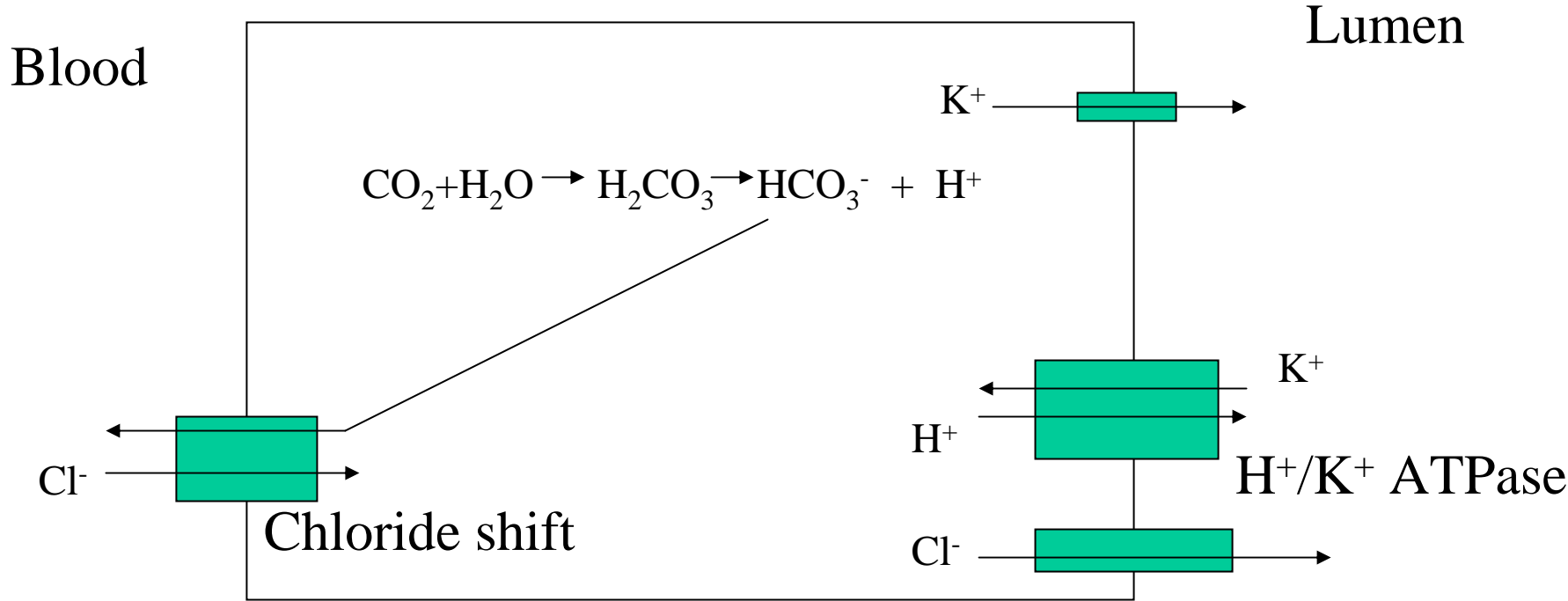


Histology: Stomach

- **The parietal cell (PC)** is large, round, and eosinophilic, thanks to its cytoplasmic complement of mitochondria. Since these cells have a high demand for ATP to drive the pumps that push sodium out of the cytoplasm into the lumen of the stomach, mitochondria are abundant.
- The chief cell (**CC**) has deeply basophilic basal regions, indicative of the presence of large amounts of RER. At its apical end, the chief cell has granular inclusions; these are the packets of enzymes waiting to be released.



Hydrochloric Acid Production



Summary of Stomach Secretions

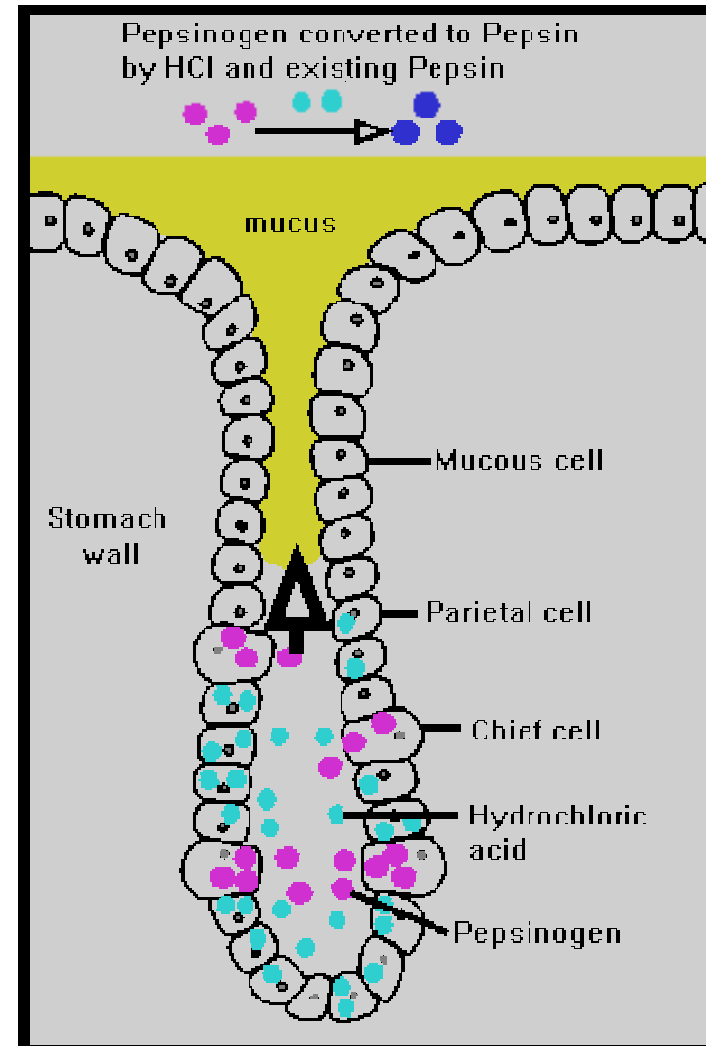
- Mucous neck cells- Mucous
- Parietal cells- HCl & intrinsic factor
- Chief cells- Pepsinogen
- Enteroendocrine cells- histamine, gastrin, somatostatin

Functions of Stomach Acid (HCl)

- Activates pepsin and lingual lipase
- Breaks up connective tissues and plant cell walls , helping to liquefy food and form chyme
- Converts ingested ferric ions (Fe^{3+}) to ferrous ions (Fe^{2+}), a form of iron that can be absorbed and used for hemoglobin synthesis
- Destroys ingested bacteria and other pathogens

Pepsin

- A digestive enzyme secreted as the inactive enzyme, **pepsinogen** (called a **zymogen**- an inactive enzyme) that is activated by the presence of HCl
- Its function is to digest dietary proteins to a shorter peptide chain which then can pass to the small intestine, where their digestion is completed

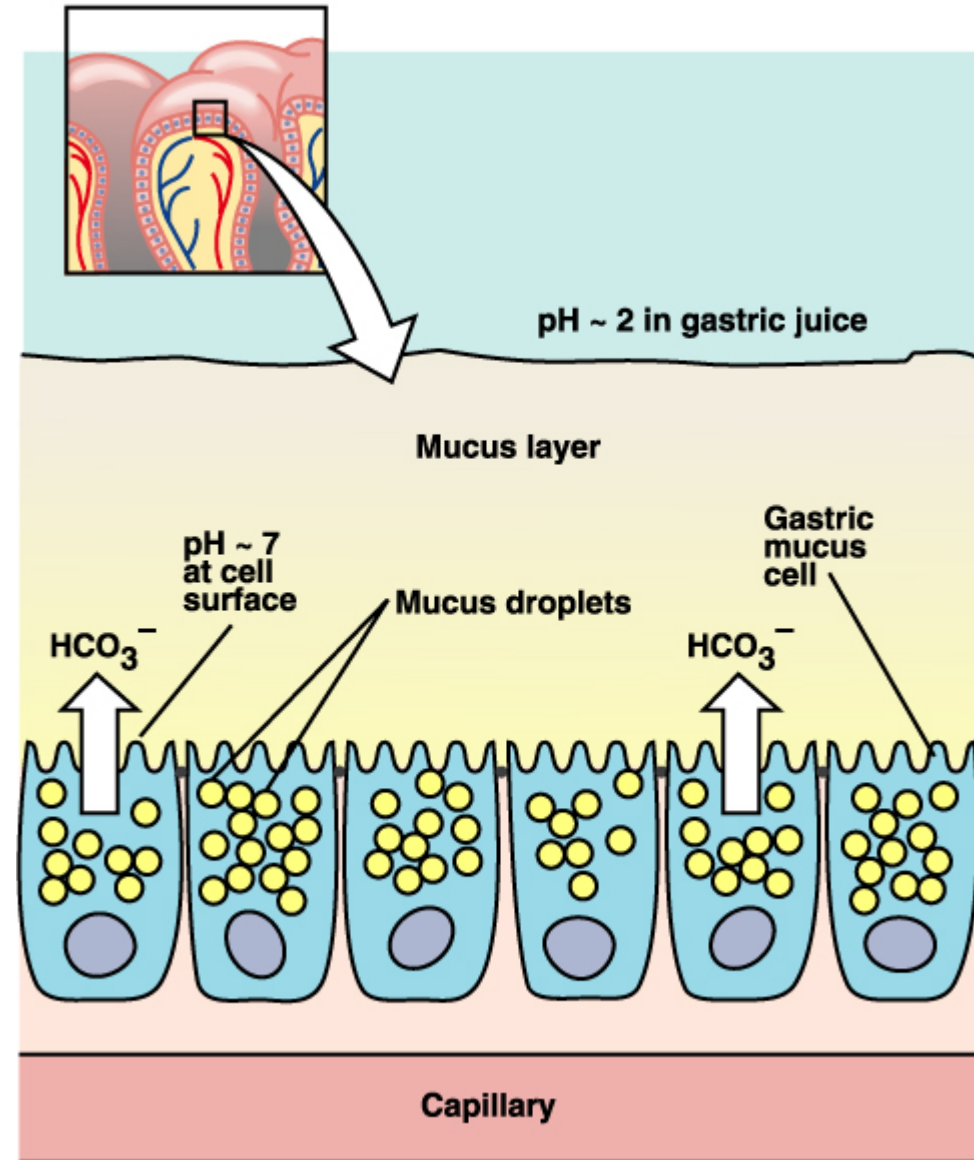


Hydrochloric Acid

- HCl accumulates in the stomach while bicarbonate ions accumulate in the blood
 - Causing the blood leaving the stomach to be more basic while digestion is occurring. This high blood pH is called **alkaline tide**.

Protection of the Stomach

- The stomach is protected in three ways from the harsh acidic and enzymatic environment
 - **Mucous coat**- thick highly alkaline mucus resists the action of acid and enzymes
 - **Epithelial cell replacement**- cells live only 3-6 days and are replaced
 - **Tight junctions**- that prevent gastric secretions from seeping between the cells

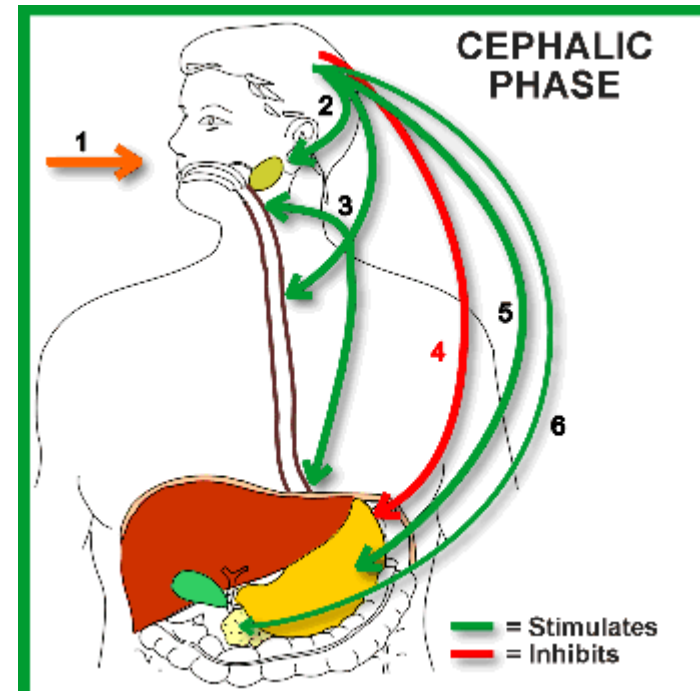
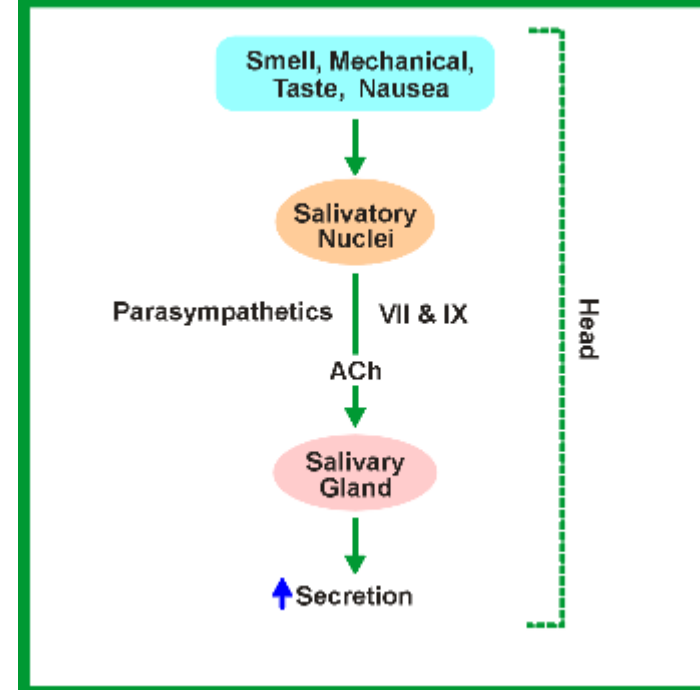


Regulation of Gastric Function

- Gastric activity is divided into three stages called:
 - Cephalic phase
 - Gastric phase
 - Intestinal phase
- Stages are based on whether the stomach is being controlled by the brain, by itself, or by the small intestine

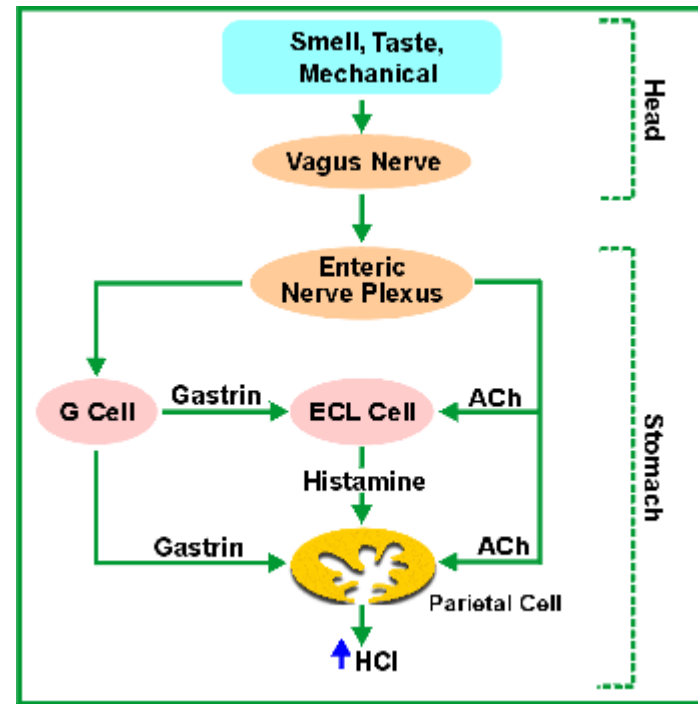
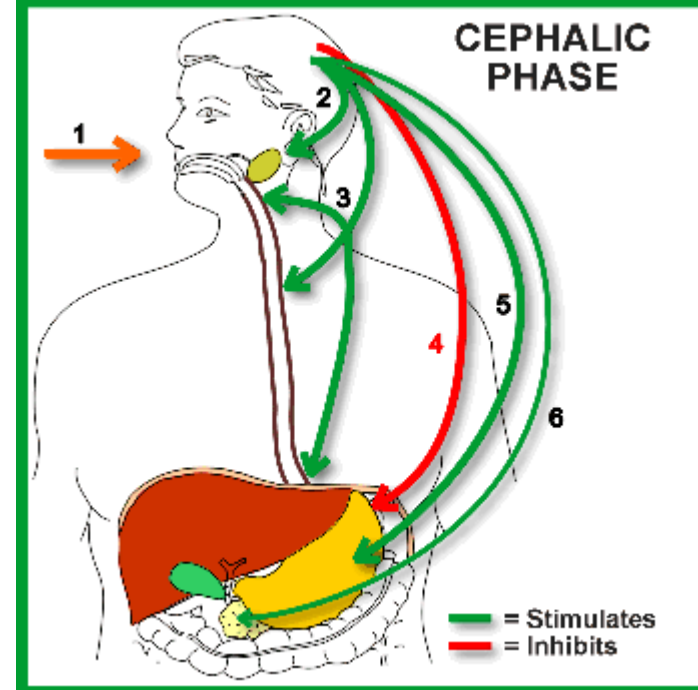
Cephalic Phase

- Begins with presentation and ingestion of a meal
- The **(1) sight, smell and taste** of food as well as **mechanical stimulation** of the oral cavity and swallowing **initiate a number of "long" reflexes (2-6)** which alter GI activities .
- During this phase **(2) salivation is stimulated** by cholinergic reflexes mediated by **parasympathetic nerves**.
- Reflexes initiated during **swallowing (3) stimulate** primary **peristalsis** in the esophagus and **cause relaxation** of the **upper and lower esophageal sphincters**.
- Vagal reflexes **(4) inhibit** contractile activity in the proximal stomach [receptive relaxation].



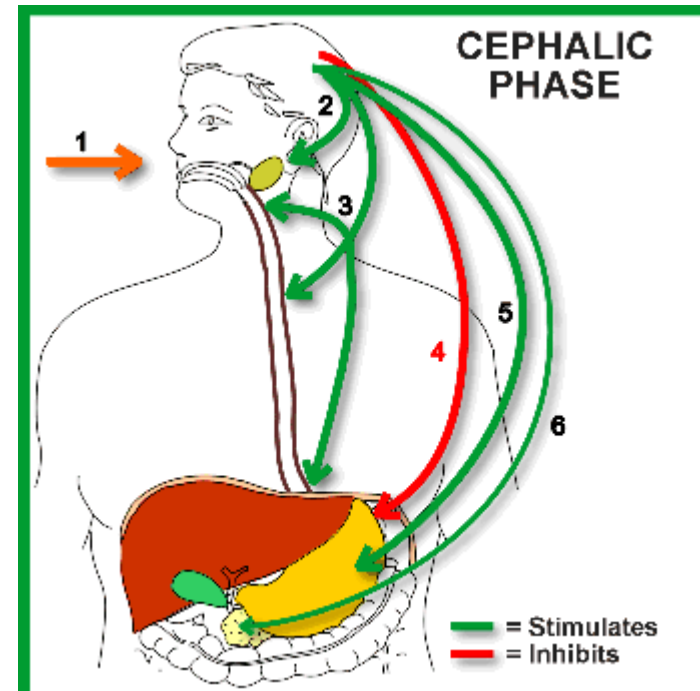
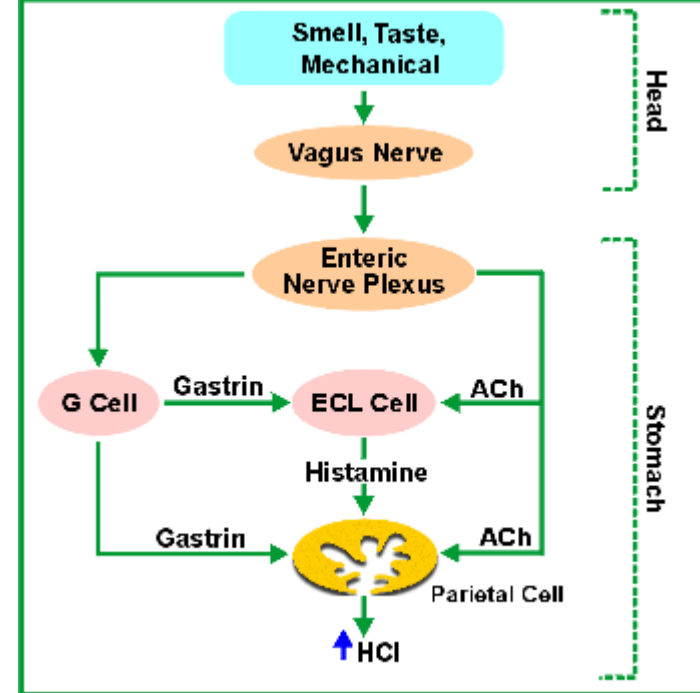
Cephalic Phase

- Vagal reflexes initiated during the cephalic phase also (5) stimulate acid secretion by parietal cells in the stomach.
- These "long" reflexes, acting through cholinergic neurons of the enteric nerve plexus stimulate,
 - secretion of **HCl** by parietal cells
 - secretion of **histamine** by the enteroendocrine (enterochromaffin-like, ECL) cells.



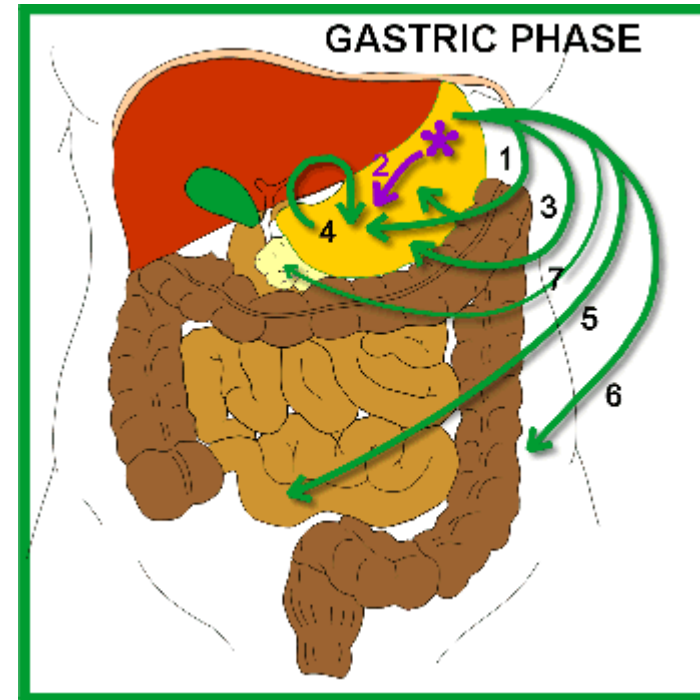
Cephalic Phase

- **Histamine** in turn stimulates **parietal cell secretion of acid**.
- In addition, **vagal reflexes** to the **antrum** stimulate secretion of the hormone **gastrin** from **G cells**.
- Elevated levels of circulating **gastrin** increase **acid secretion** by
 - direct stimulation of parietal cells and
 - by stimulating histamine secretion from ECL cells.
- Vagal reflexes also induce a relatively small (**6**) stimulation of enzyme secretion by the exocrine pancreas.



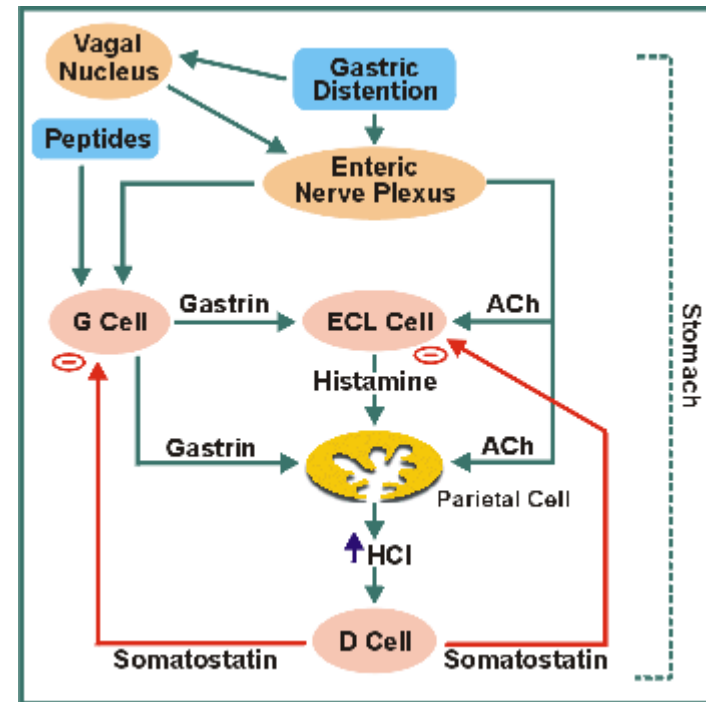
Gastric Phase

- Begins when food enters the stomach.
- Distention (✳) of the stomach activates stretch receptors initiating a number of reflexes (1-7) which alter gastric, intestinal, colonic and pancreatic activities.
- Gastric acid secretion is stimulated by
 - (1) "long" vago-vagal reflexes and
 - (2) "short" reflexes mediated by the enteric nerve plexus .



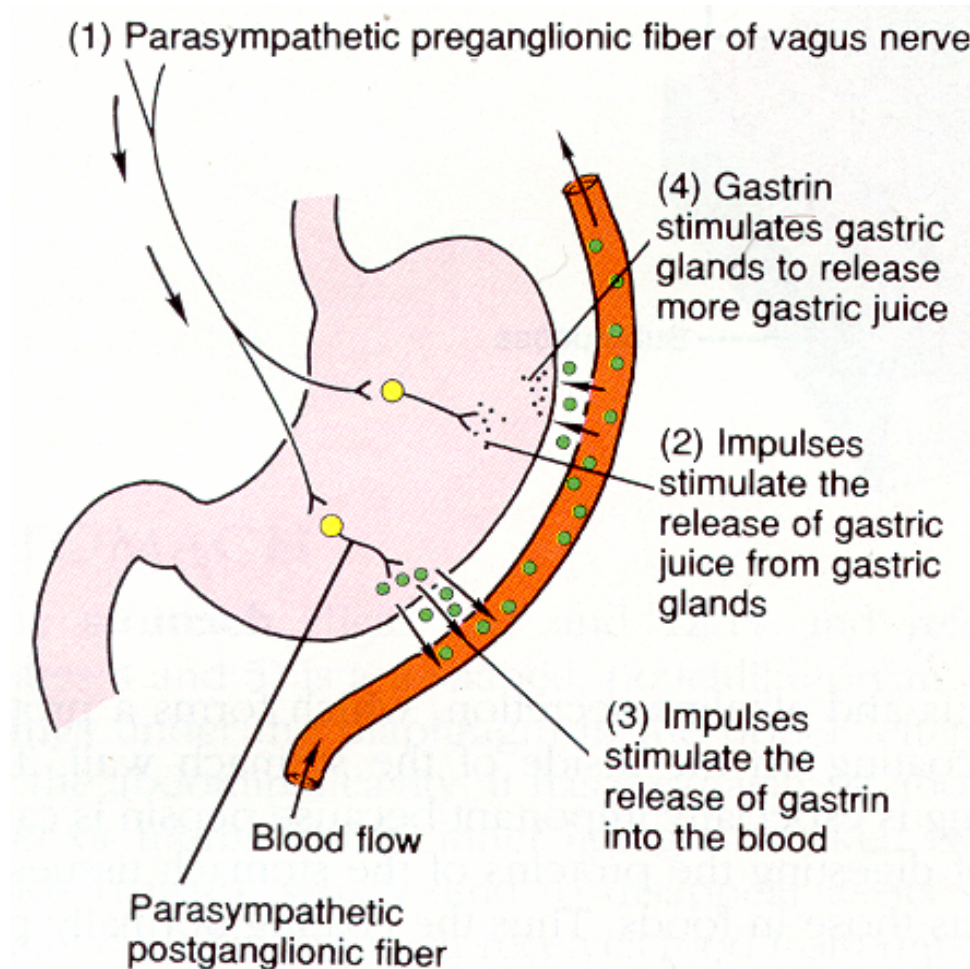
Gastric Phase

- These reflexes enhance acid secretion by:
 - 1) **cholinergic stimulation of parietal cells**
 - 2) stimulation of **histamine** secretion by **enterochromaffin-like (ECL) cells and**
 - 3) stimulation of **gastrin** secretion by **G cells.**
 - stimulates acid secretion
 - by direct stimulation of parietal cells
 - and by stimulating histamine secretion by ECL cells.



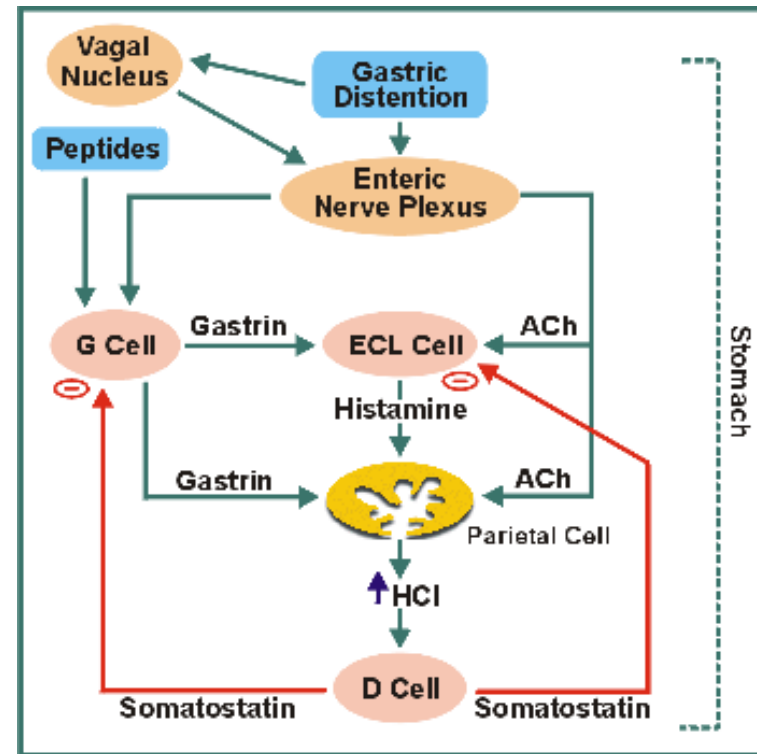
Regulation of Gastric Secretions

- Partially digested protein, caffeine, and a high pH of the chyme stimulates the release of **gastrin** (a hormone that stimulates the secretion of gastric juices, increases parastalsis, and relaxes the pyloric sphincter).



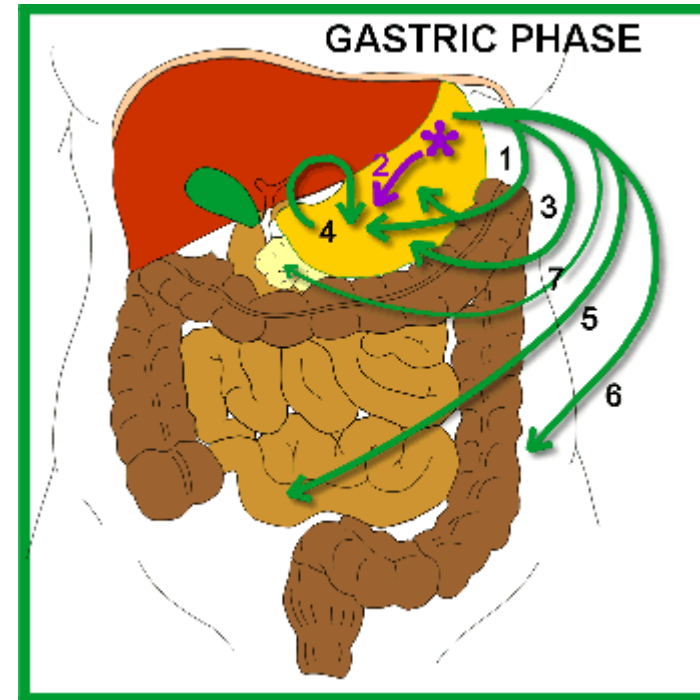
Gastric Phase

- Protein digestion products (eg. peptides) produced by the activity of acid and pepsin will stimulate G cell secretion of gastrin further enhancing acid secretion.
- As acid is secreted, the pH of the luminal contents decreases.
 - Reduction of the pH will stimulate secretion of **somatostatin from D cells** in the stomach.
 - **Somatostatin** acts to prevent excessive production of acid by **inhibiting secretion of gastrin from G cells and histamine from ECL cells**.



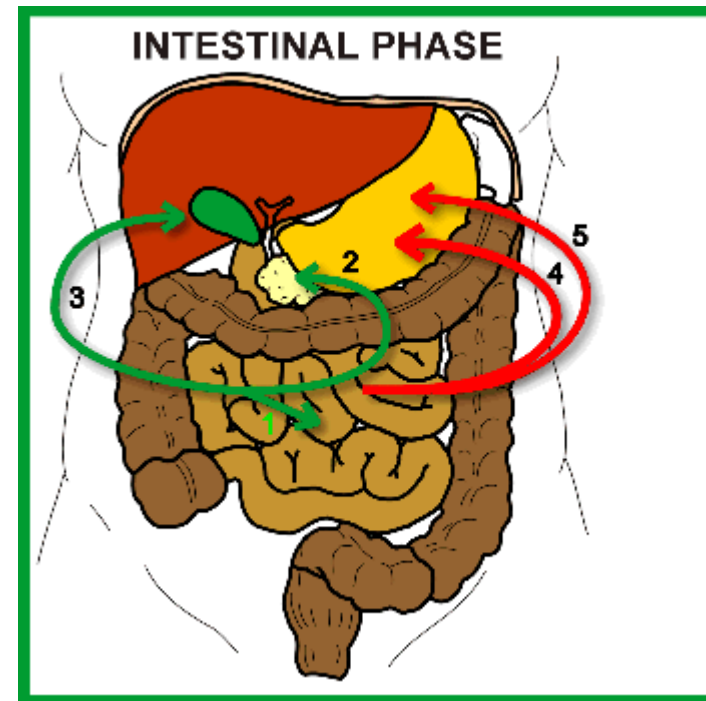
Gastric Phase

- In addition to stimulating gastric acid secretion, long and short reflexes (1, 2) and elevated circulating gastrin **stimulate gastric motility**.
- Long and short (3, 4) cholinergic reflexes stimulate secretion of **pepsinogen** from chief cells.
- Gastrin released during the gastric phase causes
 - an (5) increase in the contractile activity of the ileum and
 - relaxation of the **ileocecal sphincter** [gastroileal reflex]
 - long reflexes to induce (6) mass movement in the distal colon [gastrocolic reflex].



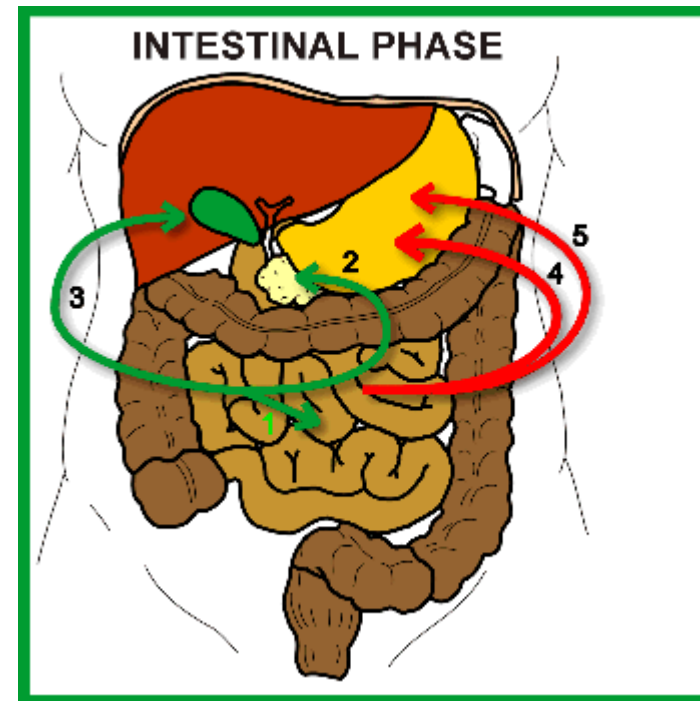
Intestinal Phase

- Stage in which the duodenum responds to arriving chyme and moderates gastric activity through hormones and nervous reflexes.
- Begins when chyme enters the small intestine
- Chyme entering the small intestine initiates reflexes and hormonal mechanisms (1-5) which alter the activities of the small intestine, pancreas, gallbladder and stomach.



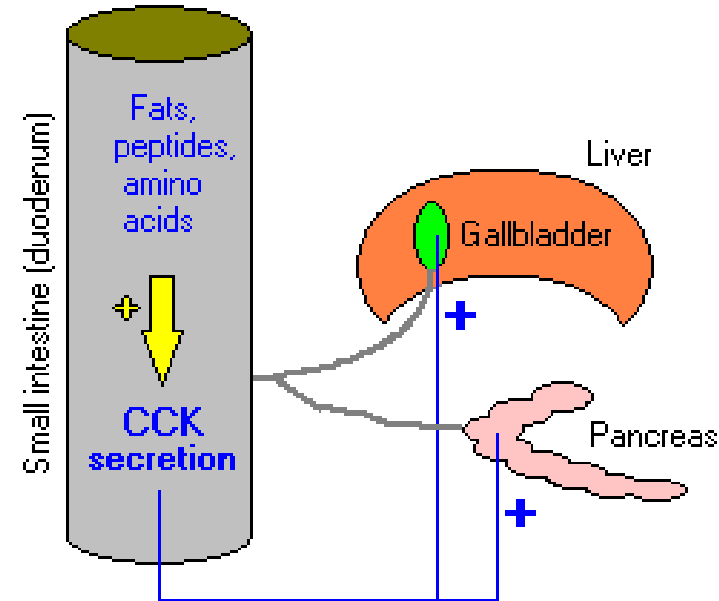
Intestinal Phase

- As chyme empties from the stomach into the small intestine it initially enhances gastric secretion, but soon inhibits it.
- the resulting distention, fat, peptides, and amino acids in the chyme activates vagovagal reflexes that **(1)** stimulates
 - intestinal contractile activity
 - G cells of the duodenum to secrete more **gastrin**
 - stimulate enteroendocrine cells in the mucosa of the **duodenum** to secrete the hormone **secretin, cholecystinin CCK), and gastric inhibitory peptide (GIP).**



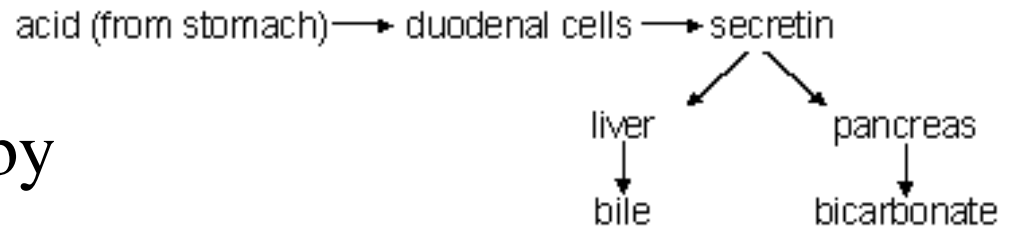
CCK (cholecystokinin)

- This hormone production is stimulated by the presence of food in the duodenum.
 - stimulates secretion of enzymes by pancreatic acinar cells.
 - induces contraction of the gallbladder and relaxation of the sphincter of Oddi.

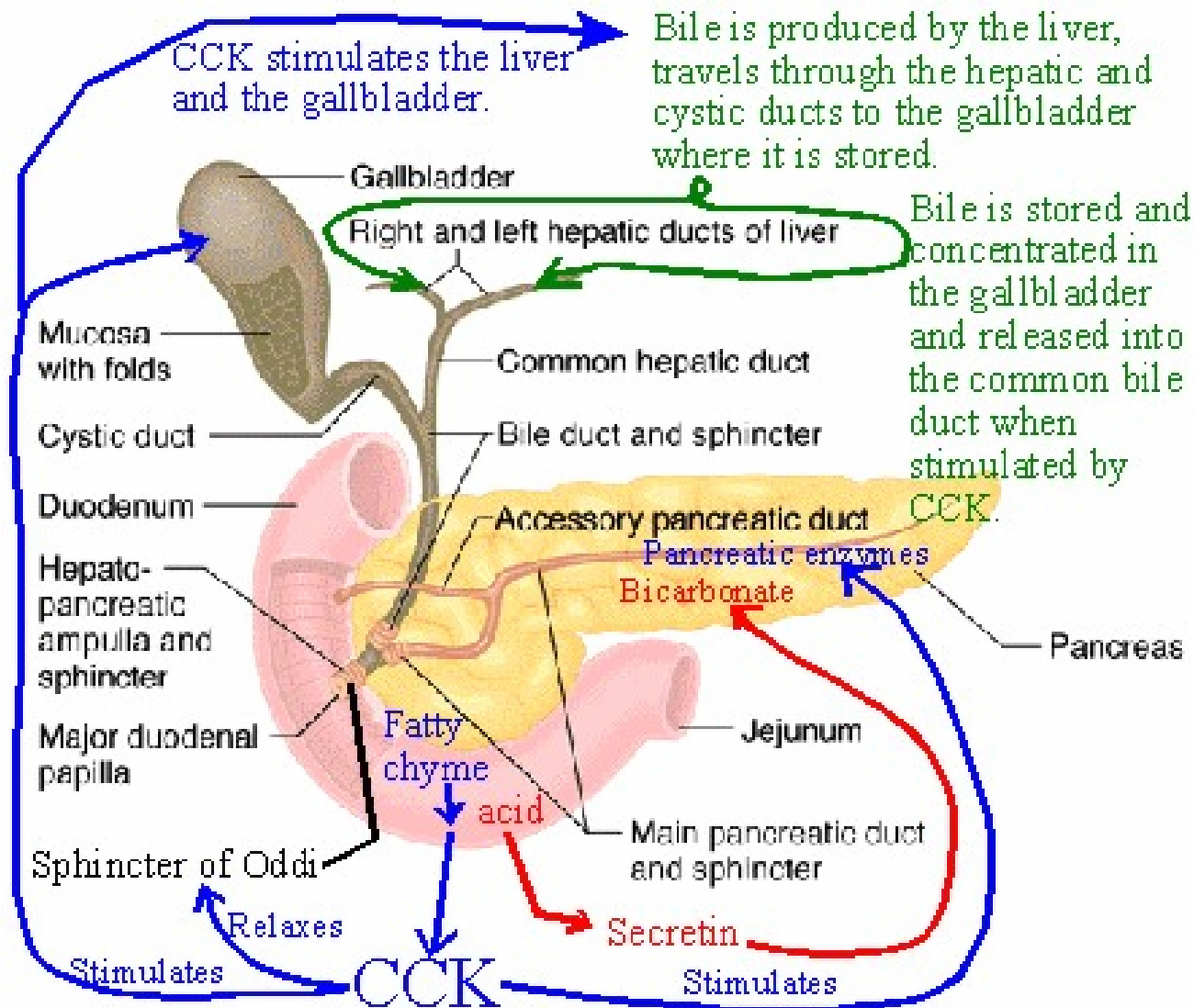


Secretin

- Elevated circulating **secretin** stimulates **bicarbonate** secretion by **pancreatic ductal cells** that neutralizes the acidity from the stomach which is necessary for a number of enzymes to function in the breakdown and absorption of food.
- It also stimulates the liver to secrete bile.

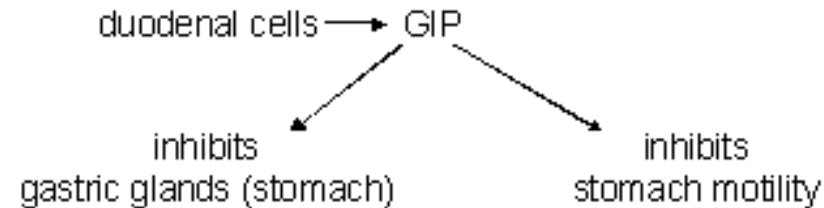


Hepato-pancreatic Junction

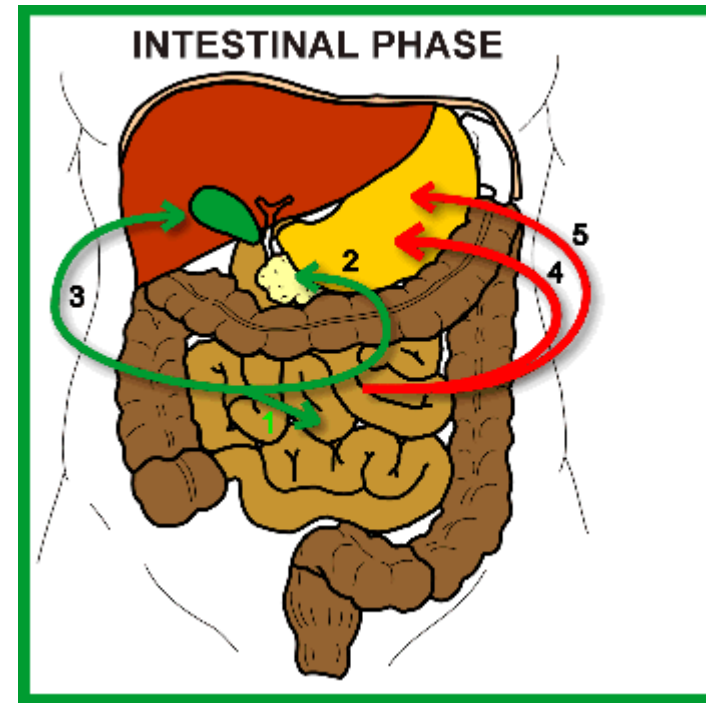
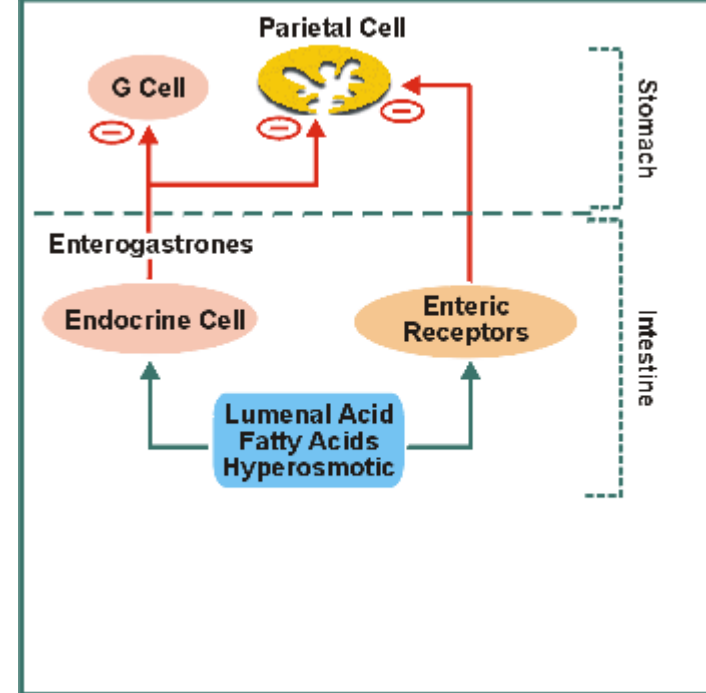


GIP (Gastric Inhibitory Peptide)

- Food in the duodenum stimulates certain endocrine cells to produce GIP.
 - It has the opposite effects of gastrin;
 - it **inhibits gastric glands** in the stomach and it **inhibits the mixing and churning movement of stomach muscles** (stomach motility).
 - This **slows the rate of stomach emptying** when the duodenum contains food.
 - enhance the release of insulin in response to infusions of glucose.



- Acidic chyme and chyme that contains fat will
 - activate duodenal receptors which act to (4) reduce the rate of gastric emptying.
 - causes a reduction in gastric secretion of acid.



Stomach Regions

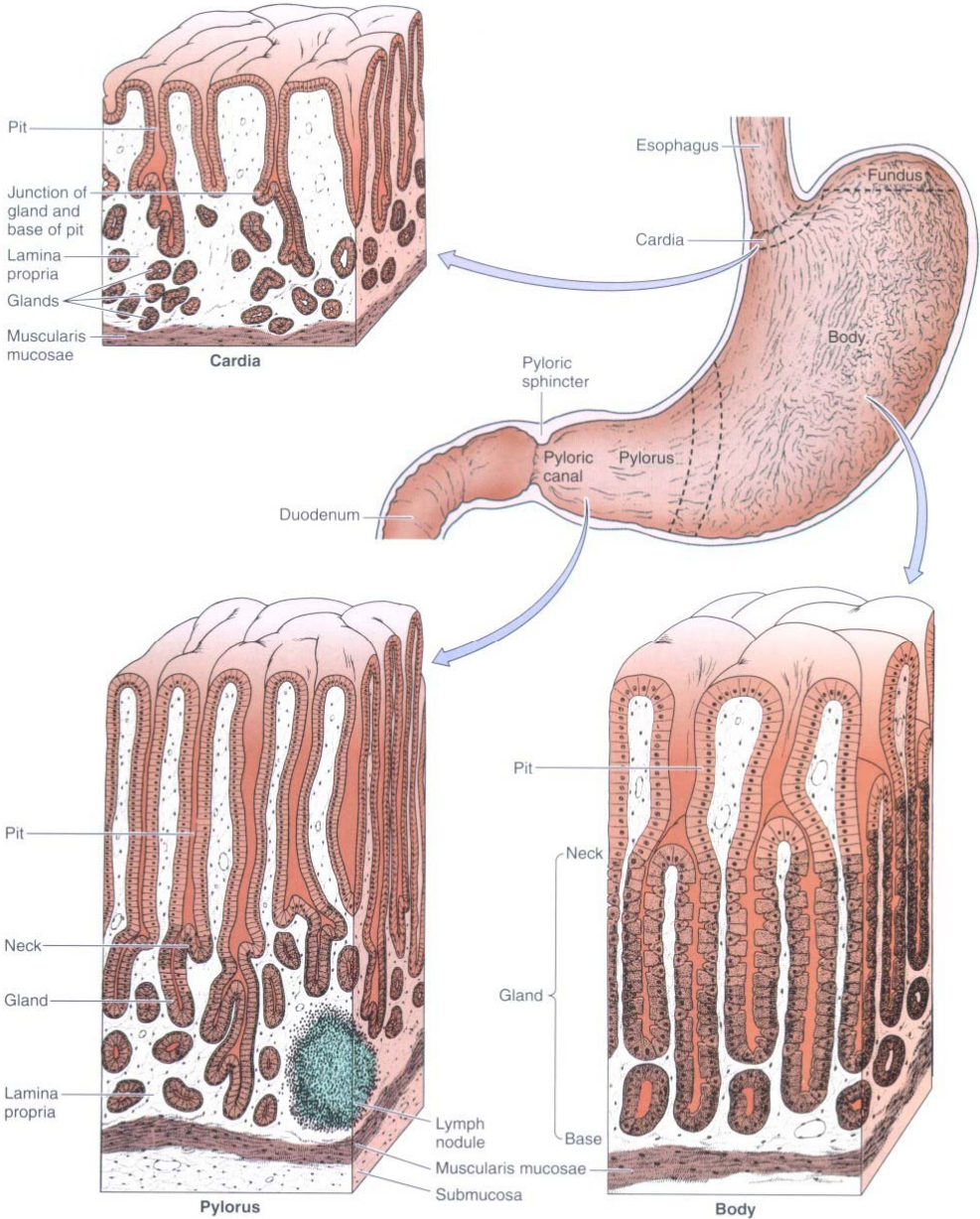


Figure 15-10. Regions of the stomach and their histologic structure.

Stomach

- Mucosa
- Submucosa
- Muscularis – 3 layers
- Serosa – on all portions of stomach

Tunica Mucosa.

- A very complex histologic diversity seen in different zones that is dependent on the functions
- Numerous folds or rugae
- The lamina propria is difficult to delineate

Submucosa

- Thick layer of loose CT
- Bulging of the submucosa is largely responsible for formation of the rugae

Tunica Muscularis

- The stomach has three layers of muscle
 - **Inner oblique layer**
 - **Middle circumferential or circular layer**
 - **Outer longitudinal layer.**
- Auerbach's plexus lies between the outer two layers

General Structure

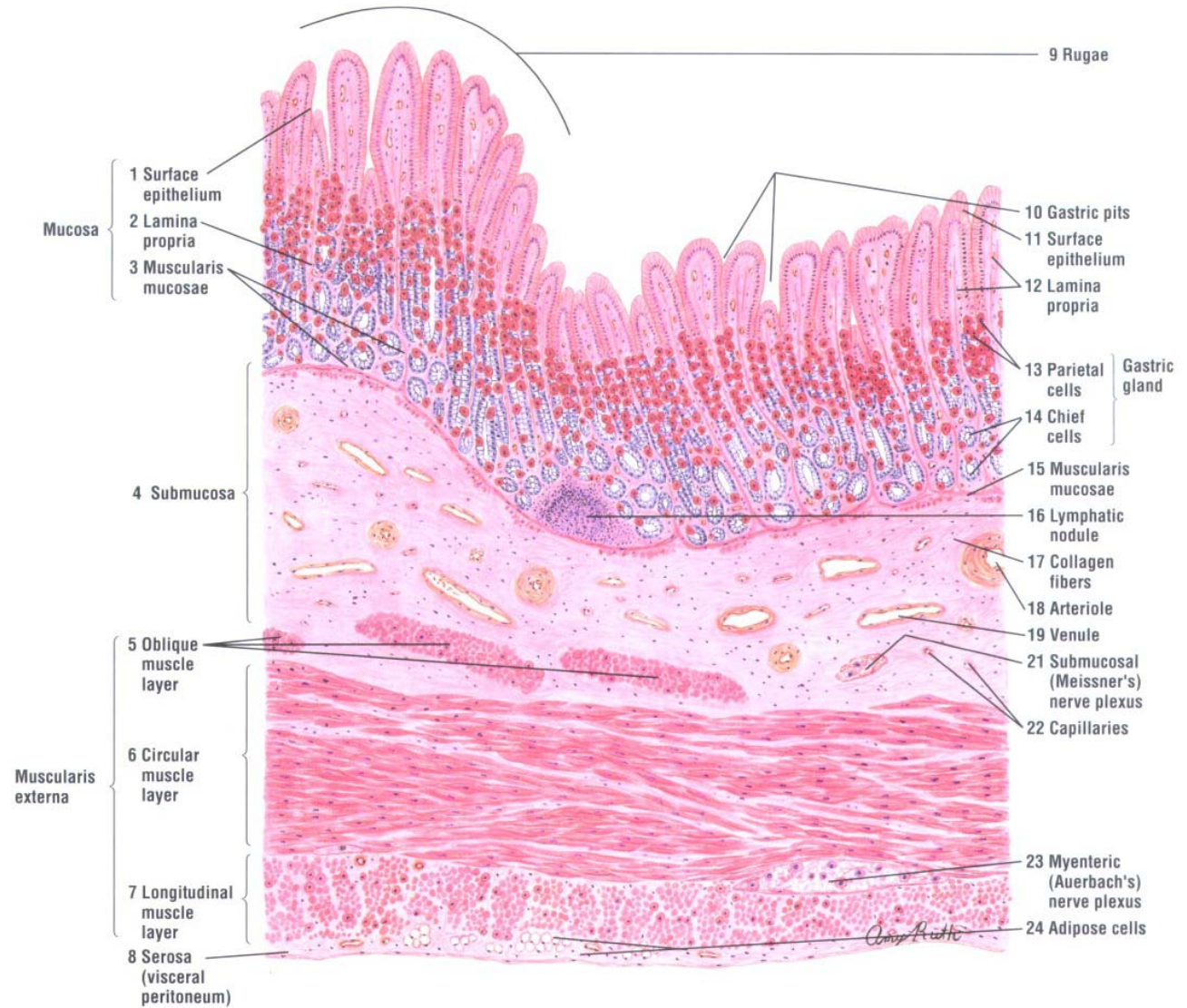


Fig. 11-6 Stomach: Fundus and Body Regions (transverse section). Stain: hematoxylin-eosin. Low magnification.

Glands in the Stomach

- Cardiac glands - mucus **
- Gastric glands - enzyme + acid
- Pyloric glands - mucus ** (differs from mucus of cardiac glands)
- **Mucus differs from mucus of neck cells

Stomach Regions

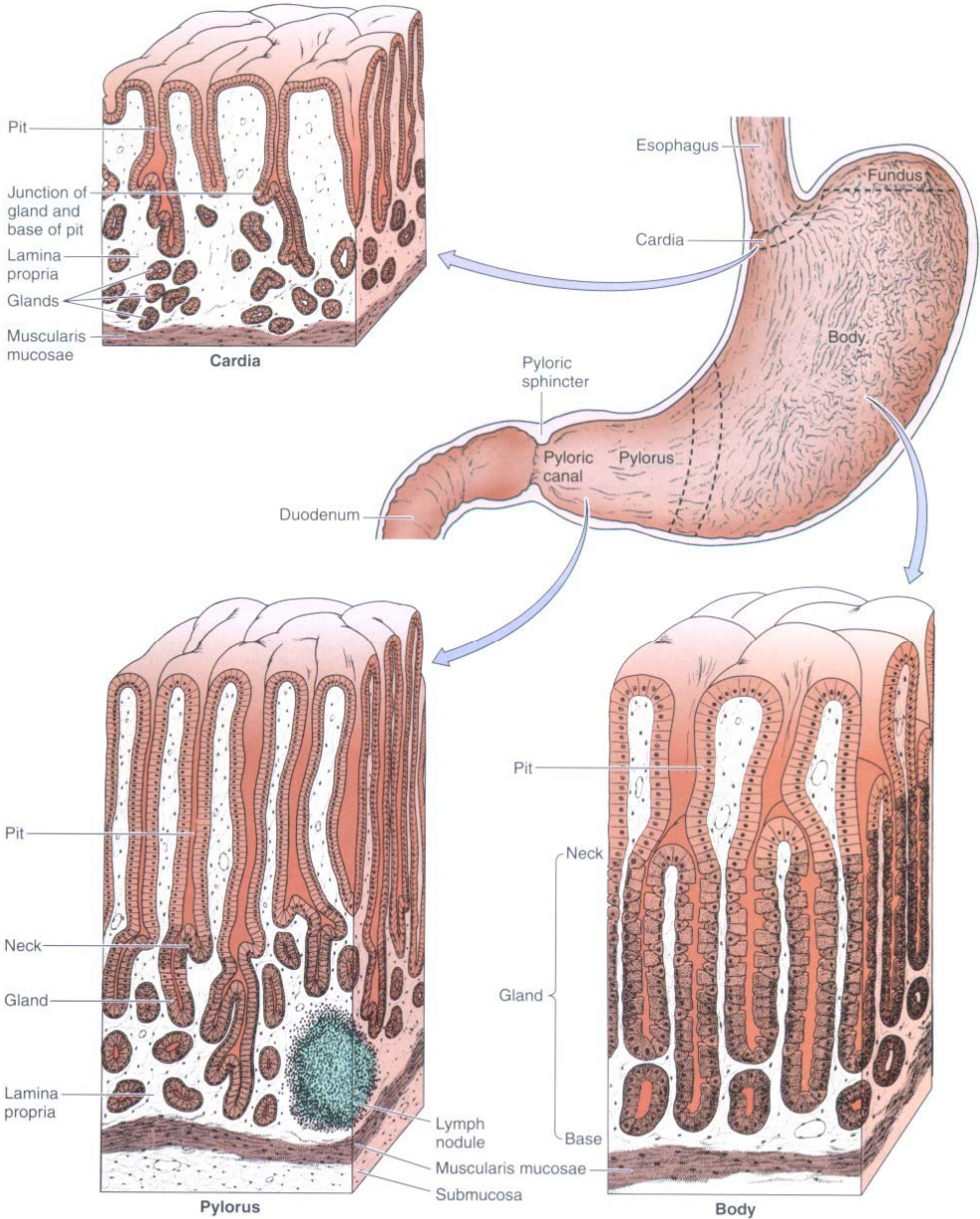
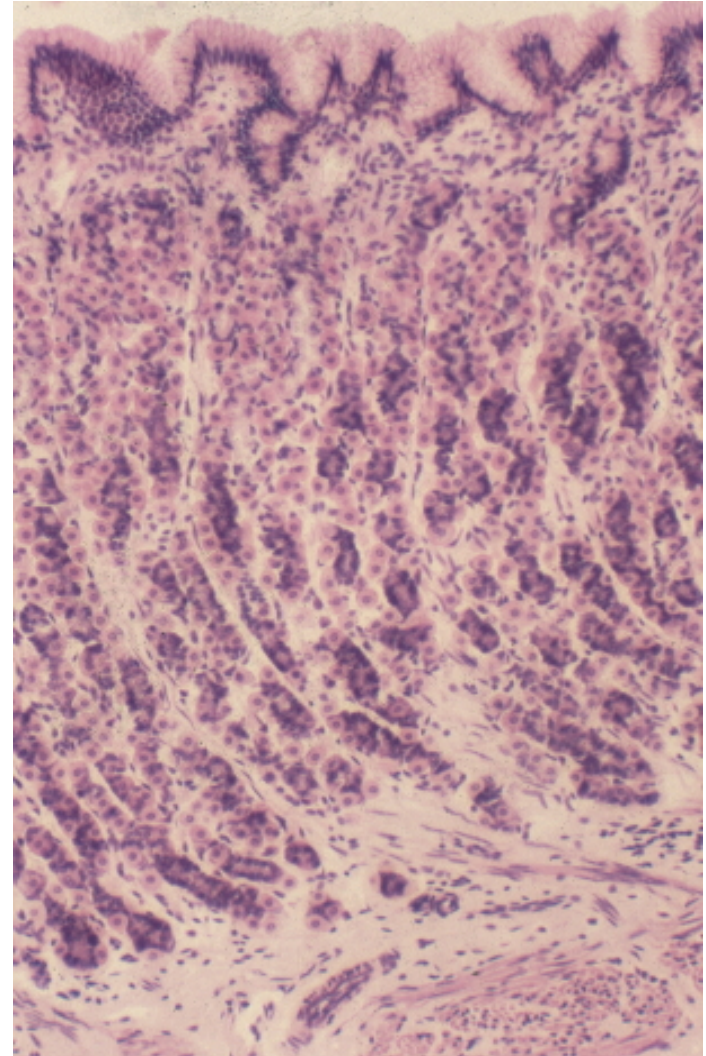
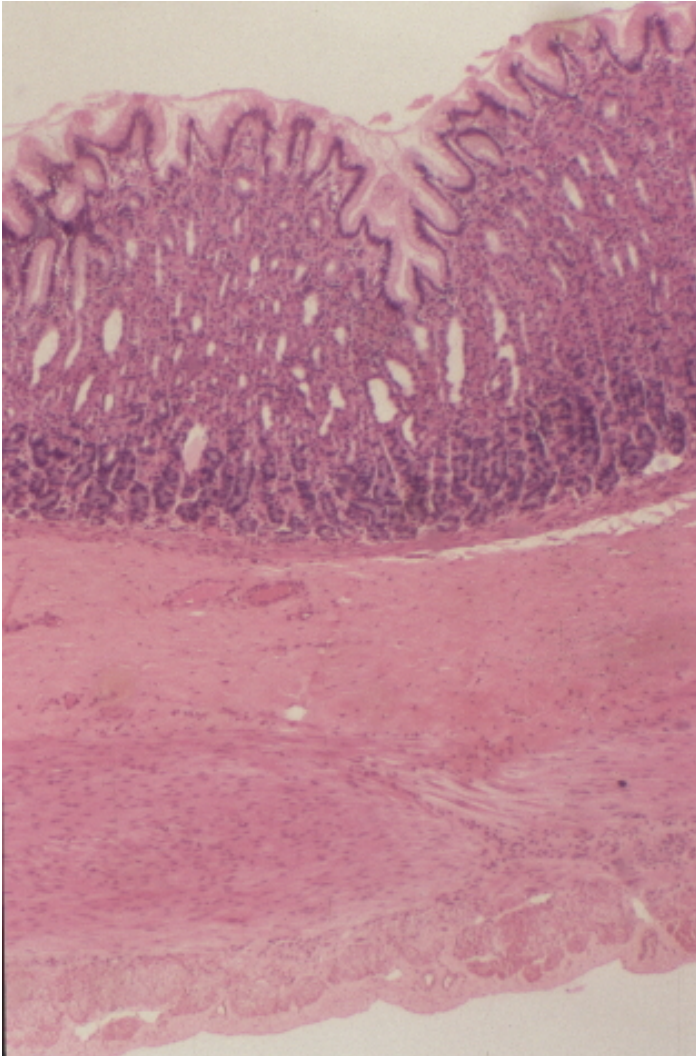


Figure 15-10. Regions of the stomach and their histologic structure.

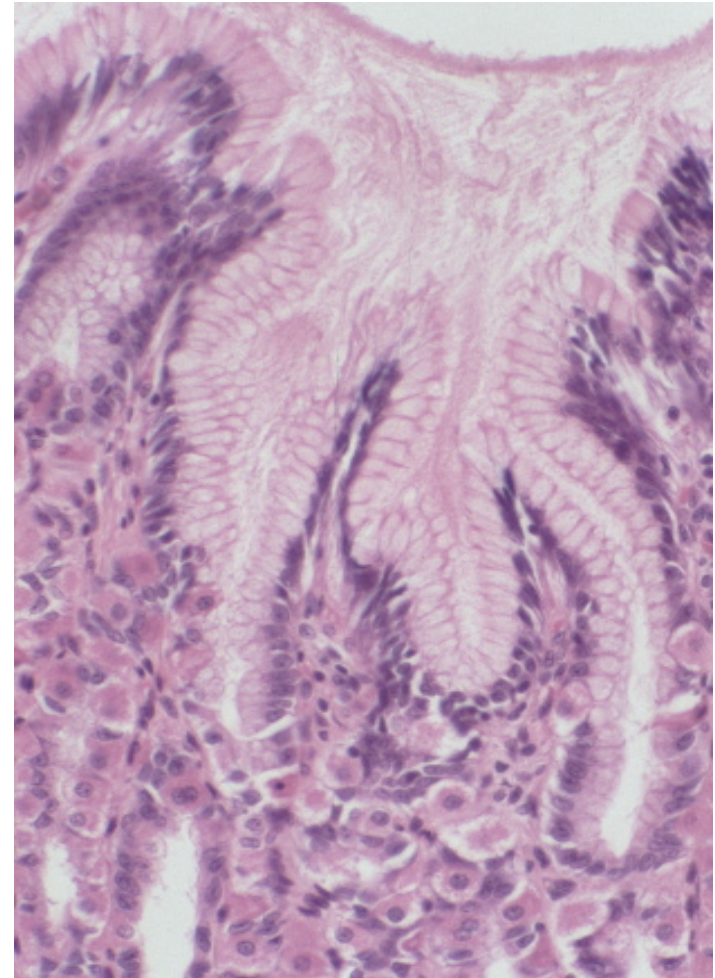
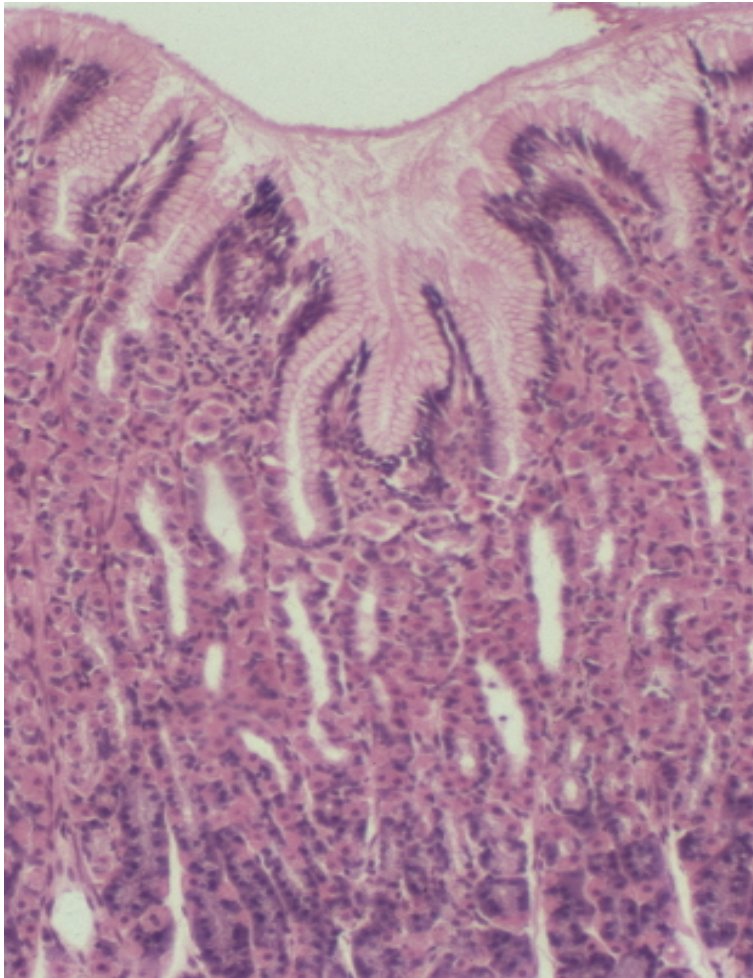
Gastric Mucosa



Gastric Glands –Neck region

- The luminal portion of every gland opens into a gastric pit. This junction is known as the neck of the gland.
- Columnar mucous neck cells
- Stem cells – turnover time approximately 7 days

Mucous Neck cells and Gastric Glands



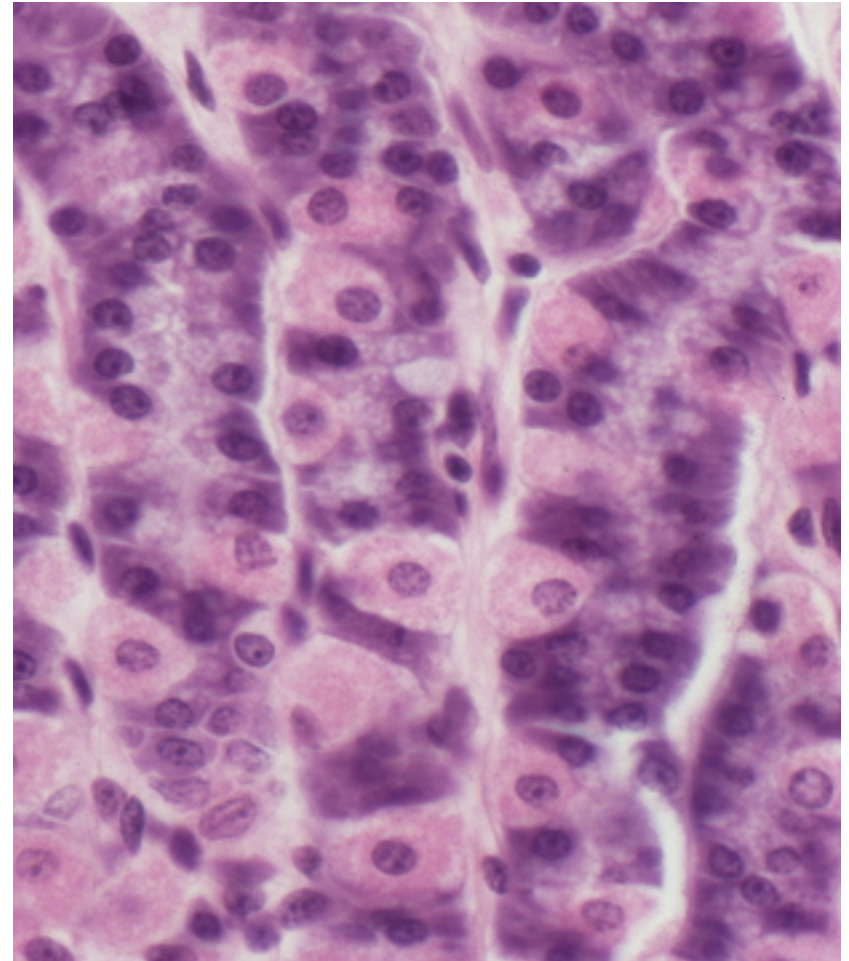
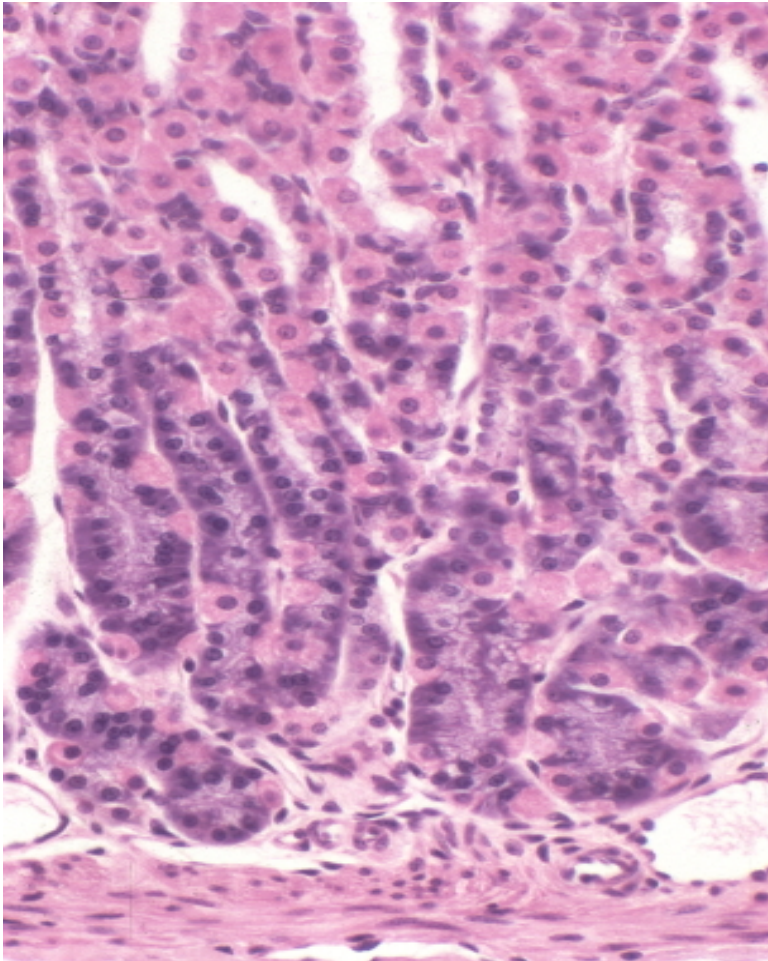
Gastric Gland Cells

- Parietal (Oxyntic) Cells
 - Large, eosinophilic cells
 - Main function is the secretion of hydrochloric acid.
- Chief Cell
 - Produce pepsinogen
- Neuroendocrine cells

Parietal Cells

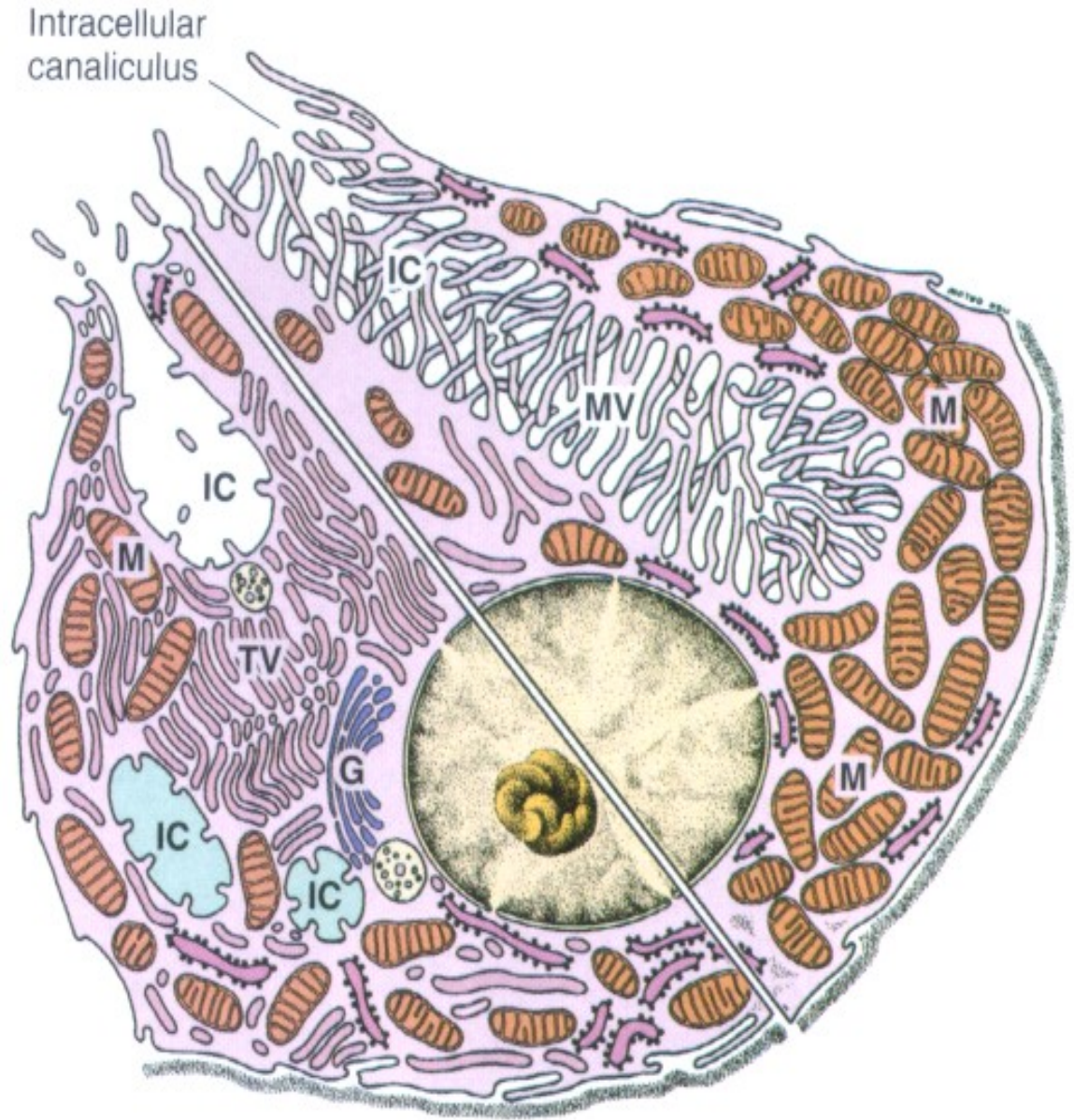
- Predominate but are not confined to the body of the glands
- Produce hydrochloric acid and gastric intrinsic factor
- Cells are eosinophilic due to the large number of mitochondria

Parietal Cells

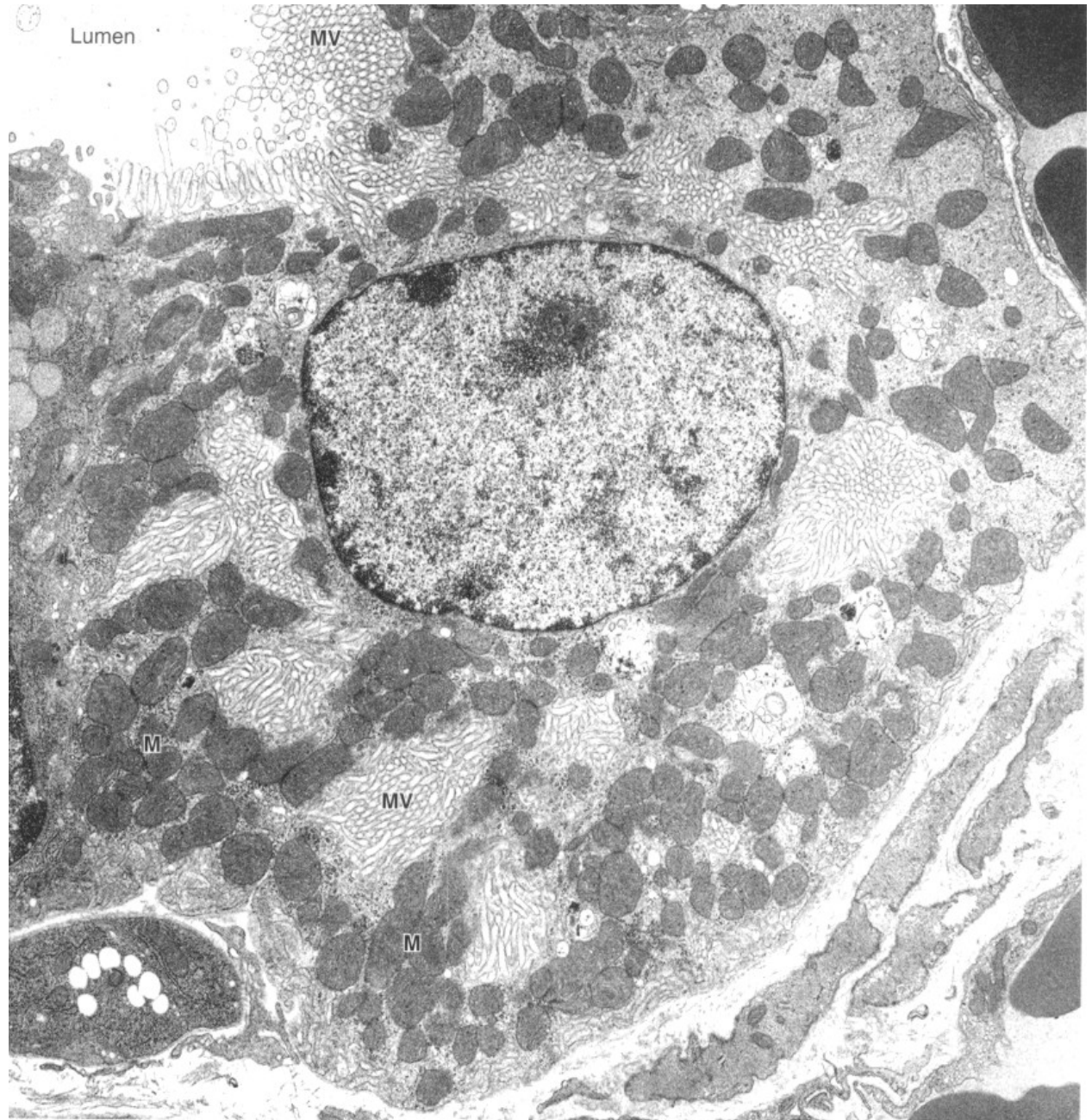

Parietal Cells

Complex system of vesicles & intracellular canaliculi



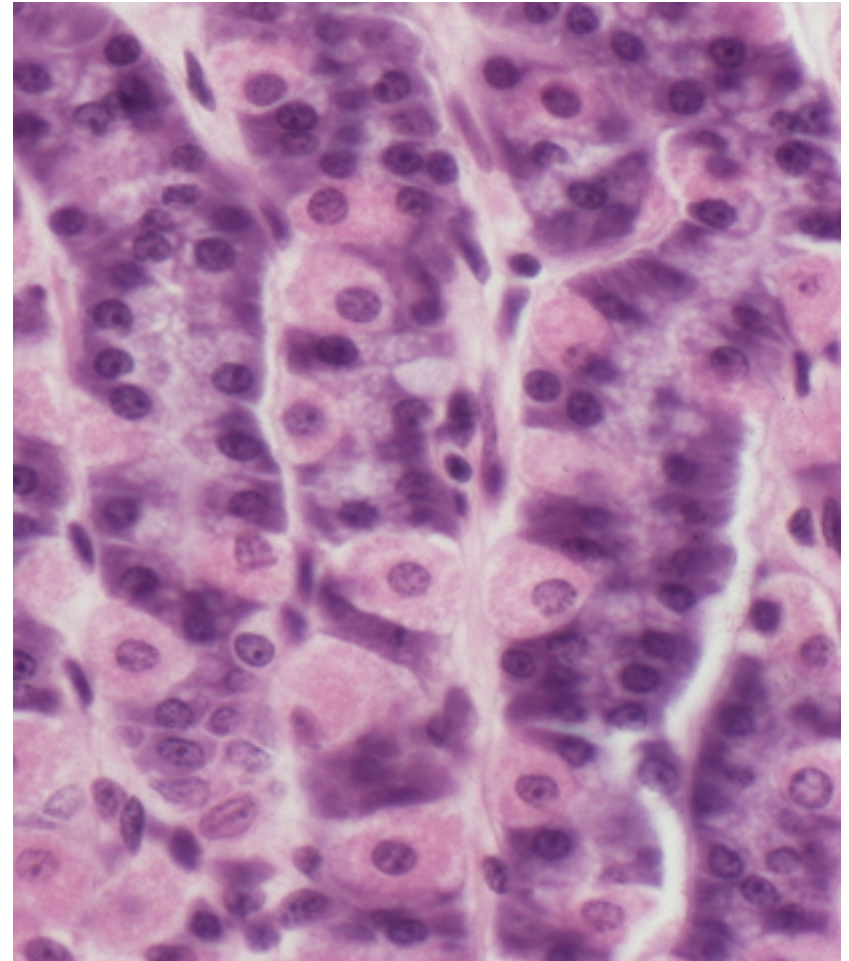
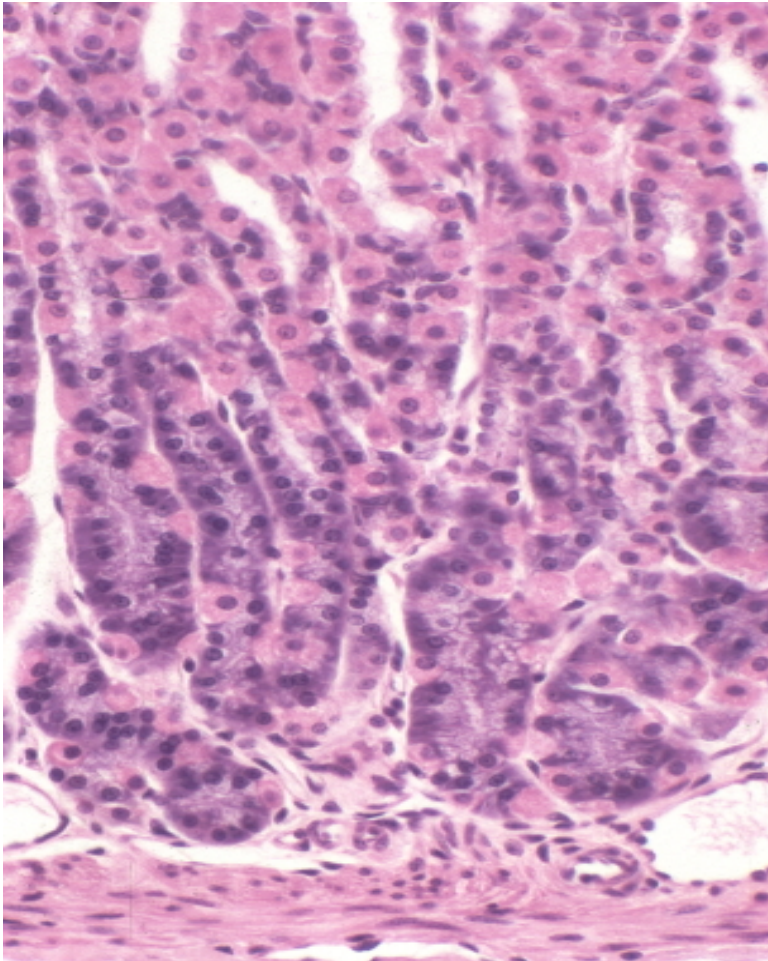
Parietal Cells – EM



Chief Cells

- Generally located towards the base of the gland but are not confined to this location.
- Pepsinogen is converted to pepsin in the acidic environment of the stomach lumen

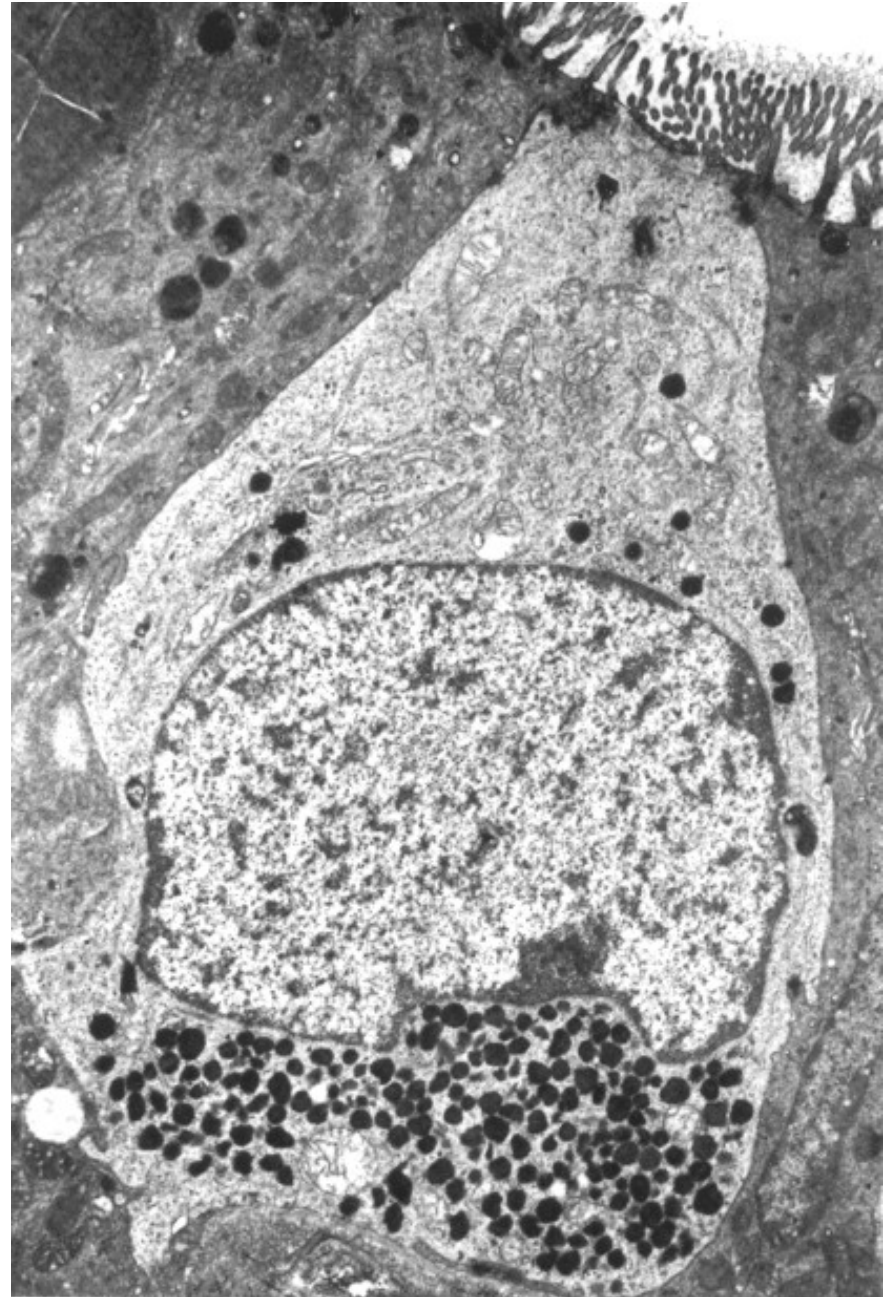
Chief Cells



Enteroendocrine Cells

- Cells of the APUD system are found in the bases of the glands secreting serotonin.
- They are found mainly in the gastric glands.

Entero - endocrine Cell



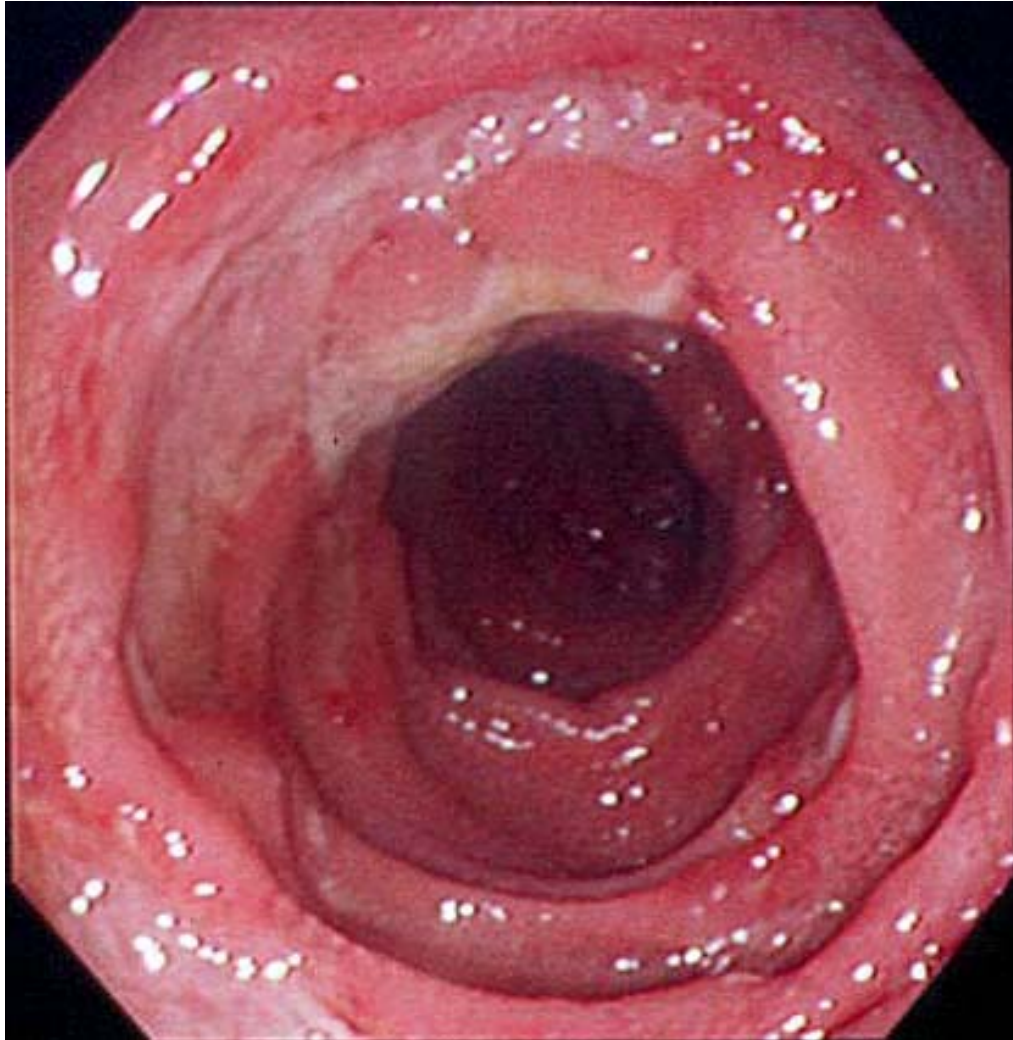
Small Intestine

- **The small intestine is the longest section of the digestive tube and consists of three segments forming a passage from the pylorus to the large intestine:**
 - **Duodenum:** a short section that receives secretions from the pancreas and liver via the **pancreatic and common bile ducts**.
 - **Jejunum:** considered to be roughly 40% of the small gut in man,
 - **Ileum** empties into the large intestine; considered to be about 60% of the intestine in man,

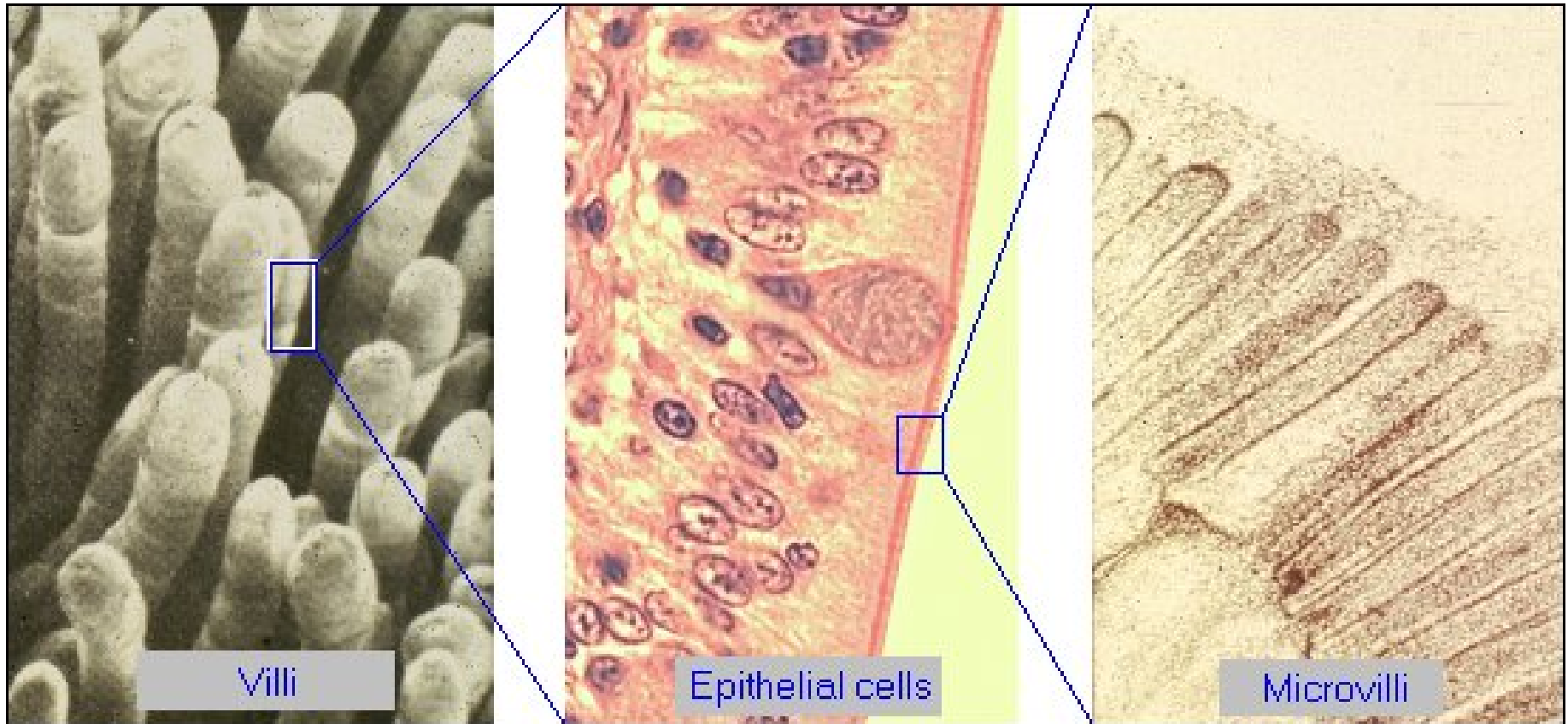
Small Intestine

- The absorptive surface area of the small intestine is roughly 250 square meters - the size of a tennis court
- **The small intestine incorporates three features which account for its huge absorptive surface area:**
 - **Mucosal folds:** the inner surface of the small intestine is not flat, but thrown into circular folds, which not only increase surface area, but aid in mixing the ingesta by acting as baffles.
 - **Villi:** the mucosa forms multitudes of projections which protrude into the lumen and are covered with epithelial cells.
 - **Microvilli:** the luminal plasma membrane of absorptive epithelial cells is studded with densely-packed microvilli.

Mucosal Fold



Intestinal Villi & Microvilli



Intestinal Cells

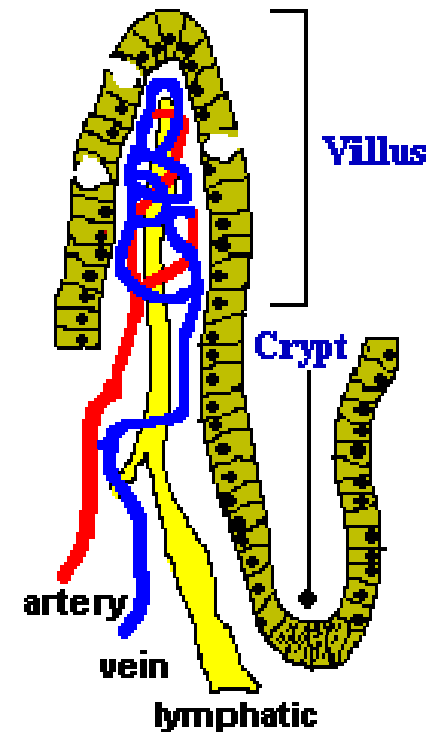
Three major types of cells in the small intestine

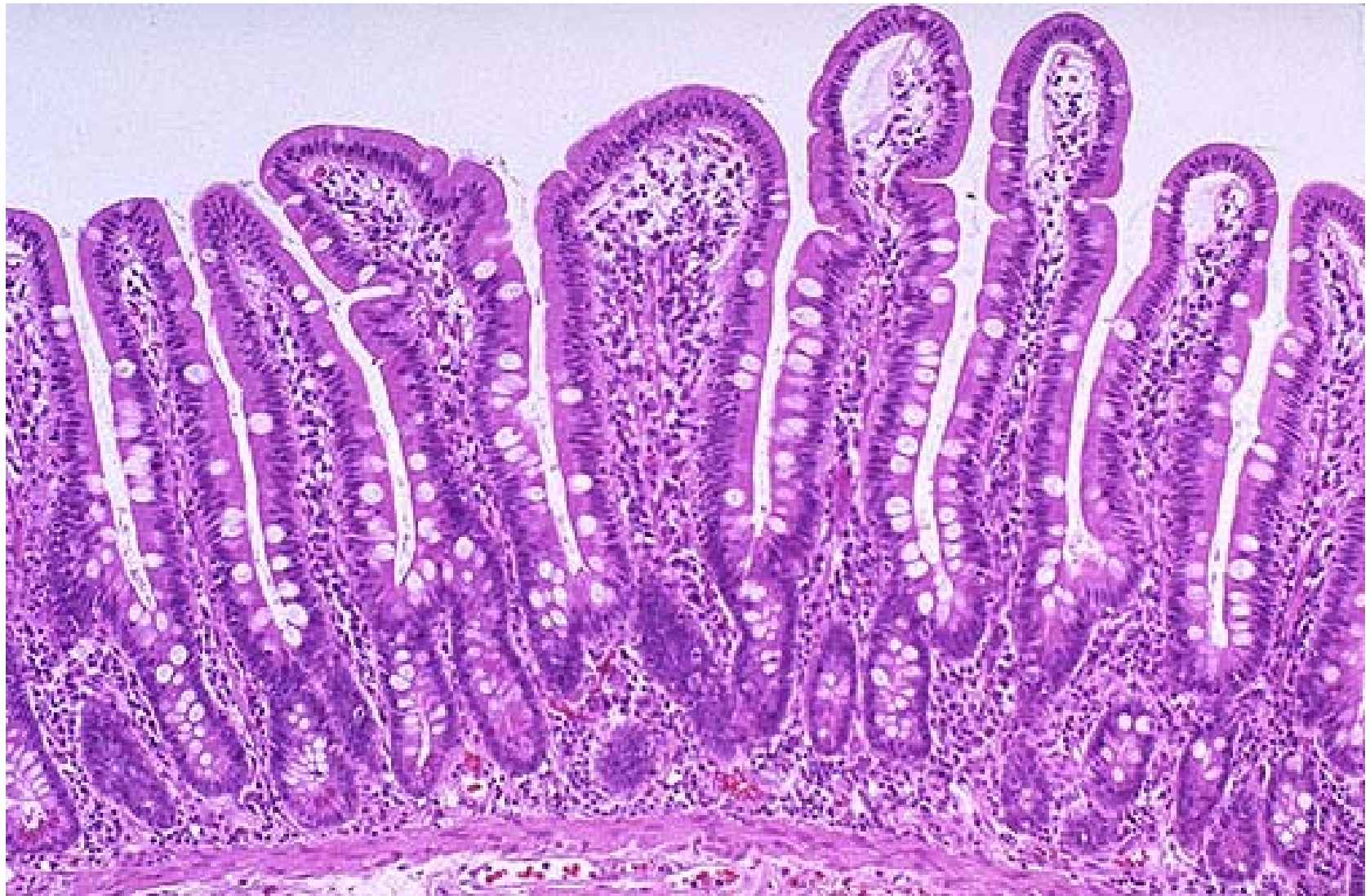- **enterocytes**, the epithelial cells which mature into absorptive epithelial cells that cover the villi.
- **Enteroendocrine cells** which, as part of the enteric endocrine system sense the luminal environment and secrete hormones such as cholecystokinin and gastrin into blood.
- **Goblet cells**, which secrete a lubricating mucus into the intestinal lumen.

Small Intestine Mucosa

The mucosa of small intestinal mucosa is arranged into two fundamental structures:

- **Villi** are projections into the lumen covered predominantly with
 - **mature, absorptive enterocytes,**
 - along with occasional mucus-secreting **goblet cells.**
 - These cells live only for a few days, die and are shed into the lumen to become part of the ingesta to be digested and absorbed.
- **Crypts (of Lieberkuhn)** are moat-like invaginations of the epithelium around the villi, and
 - are lined largely with younger epithelial cells which are involved primarily in secretion.
 - Toward the base of the crypts are stem cells, which continually divide and provide the source of all the epithelial cells in the crypts and on the villi.
 - enterocyte,
 - enteroendocrine cell
 - goblet cell
 - Paneth cell- secrete lysozyme, phospholipase, and defensins, all of which protect against bacterial infection

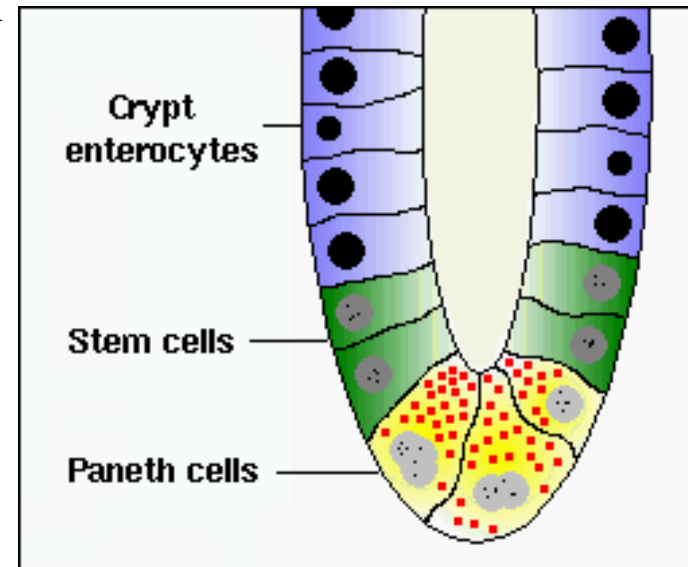




This is the normal appearance of small intestinal mucosa with long villi that have occasional goblet cells. The villi provide a large area for digestion and absorption.

Paneth Cells

- Provide host defense against microbes in the small intestine.
- They are functionally similar to neutrophils.
- When exposed to bacteria or bacterial antigens, they secrete a number of antimicrobial molecules into the lumen of the crypt
- The principal defense molecules secreted by Paneth cells are **alpha-defensins**
 - These peptides have hydrophobic and positively-charged domains that can interact with phospholipids in cell membranes.
 - This structure allows defensins to insert into membranes, where they interact with one another to form pores that disrupt membrane function, leading to cell killing.
 - Due to the higher concentration of negatively-charged phospholipids in bacterial membranes than vertebrate membranes, defensins preferentially bind to and disrupt bacterial cells, sparing the cells they are functioning to protect.
 - In addition to defensins, Paneth cells secrete **lysozyme** and **phospholipase A2**, both of which have clear antimicrobial activity.



Secretion in the Small Intestine

- Large quantities of water are secreted into the lumen of the small intestine during the digestive process.
- Almost all of this water is also reabsorbed in the small intestine.
- Regardless of whether it is being secreted or absorbed, water flows across the mucosa in response to osmotic gradients.
- In the case of secretion, two distinct processes establish an osmotic gradient that pulls water into the lumen of the intestine:
 1. **Increases in luminal osmotic pressure resulting from influx and digestion of foodstuffs:**
 2. **Crypt cells actively secrete electrolytes, leading to water secretion**

Secretion in the Small Intestine

1. **Increases in luminal osmotic pressure resulting from influx and digestion of foodstuffs**
 - The chyme that floods into the intestine from the stomach typically is not terribly hyperosmotic, but as its macromolecular components are digested, osmolarity of that solution increases dramatically.
 - Starch, for example, is a huge molecule that contributes only a small amount to osmotic pressure, but as it is digested, thousands of molecules of maltose are generated, each of which is as osmotically active as the original starch molecule.
 - Thus, as digestion proceeds luminal osmolarity increases dramatically and water is pulled into the lumen.
 - Then, as the osmotically active molecules (maltose, glucose, amino acids) are absorbed, osmolarity of the intestinal contents decreases and water can be absorbed.

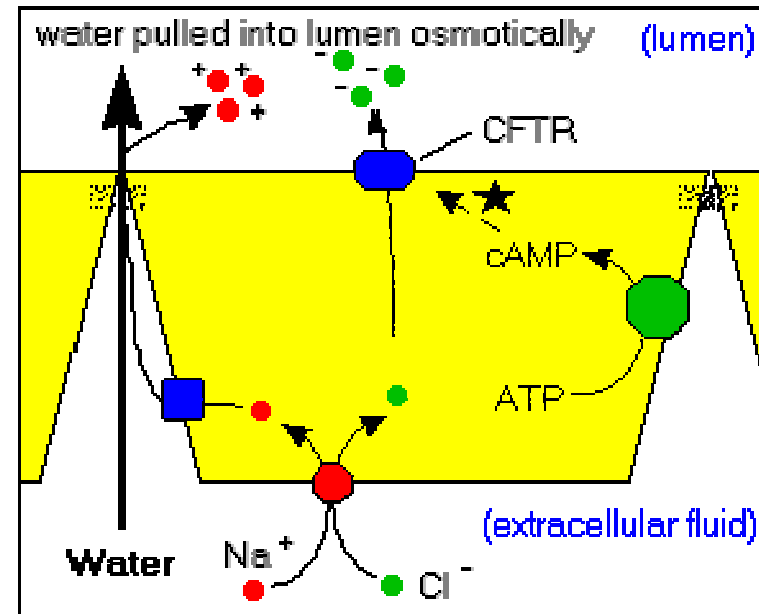
Secretion in the Small Intestine

2. Crypt cells actively secrete electrolytes, leading to water secretion

- The apical or luminal membrane of crypt epithelial cells contain a ion channel of immense medical significance - a **cyclic AMP-dependent chloride channel known also as the cystic fibrosis transmembrane conductance regulator or CFTR**. Mutations in the gene for this ion channel result in the disease cystic fibrosis.

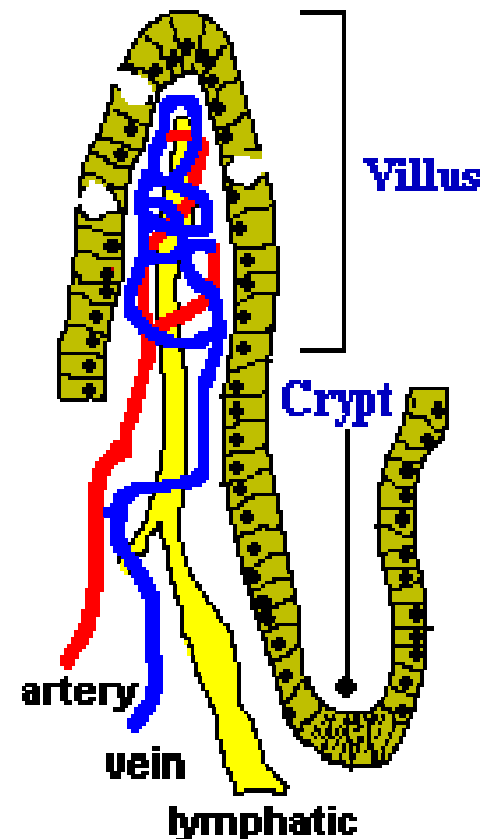
This channel is responsible for secretion of water by the following steps:

- Elevated intracellular concentrations of cAMP in crypt cells activate this channel, resulting in secretion of chloride ions into the lumen.
- Accumulation of negatively-charged chloride anions in the crypt creates an electric potential that attracts sodium, pulling it into the lumen across the tight junctions - the net result is secretion of NaCl.
- Secretion of NaCl into the crypt creates an osmotic gradient across the tight junction - water is drawn into the lumen.

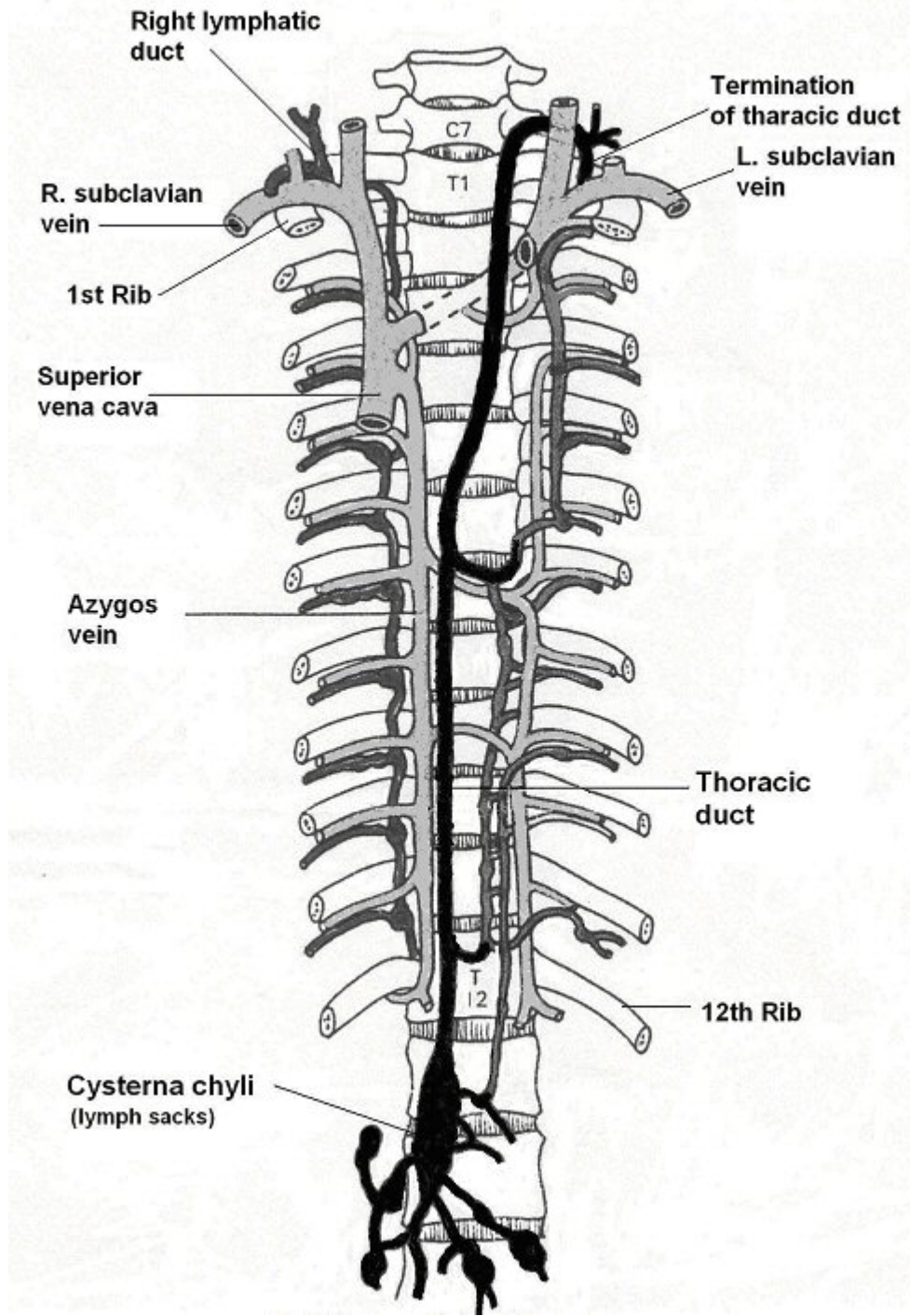
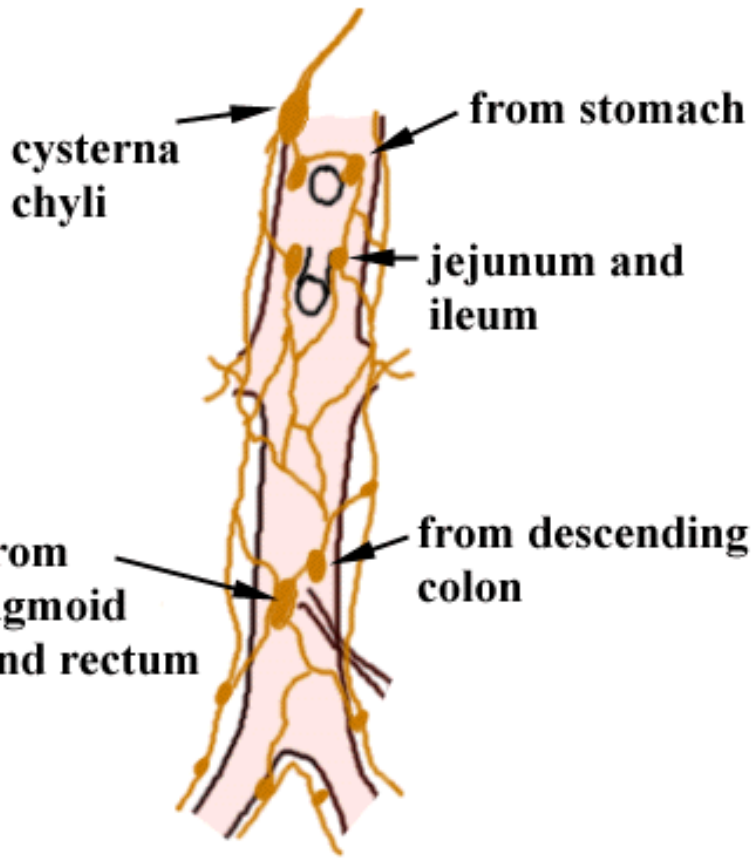


Small Intestine Mucosa

- Virtually all nutrients, including all amino acids and sugars, enter the body across the epithelium covering small intestinal villi.
- Each villus contains a **capillary bed** and a blunt-ended **lymphatic vessel** referred to as the "**central lacteal**".
- After crossing the epithelium, **most molecules diffuse into the capillary network** inside the villus, and hence into systemic blood.
- Some molecules, **fats in particular, are transported** not into capillaries, but rather **into the lymphatic vessel**, which drains from the intestine and rapidly flows into blood via the **thoracic duct**.



Lymphatic Drainage



Absorption in the Small Intestine

- Major food groups absorbed
 - Water and electrolytes
 - Carbohydrates, after digestion to monosaccharides
 - Proteins, after digestion to small peptides and amino acids
 - Neutral fat, after digestion to monoglyceride and free fatty acids

Absorption of Water and Electrolytes

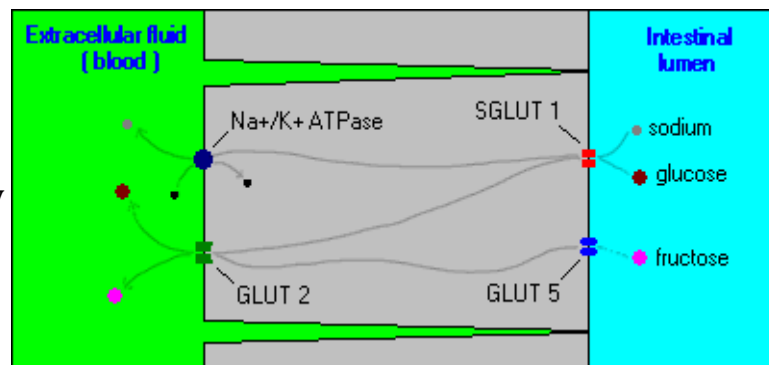
- A normal person or animal of similar size takes in roughly 1 to 2 liters of dietary fluid every day plus another 6 to 7 liters of fluid is received by the small intestine daily as secretions from salivary glands, stomach, pancreas, liver and the small intestine itself.
- By the time the ingesta enters the large intestine, approximately 80% of this fluid has been absorbed.
- Net movement of water across cell membranes always occurs by osmosis
 - the absorption of water is absolutely dependent on absorption of solutes, particularly sodium:

Absorption of Water and Electrolytes

- **Sodium is absorbed into the cell** by several mechanisms, but chief among them is by cotransport with glucose and amino acids
- **Absorbed sodium is rapidly exported from the cell via sodium pumps**
 - establishes a high osmolarity in the small intercellular spaces between adjacent enterocytes.
- **Water diffuses in response to the osmotic gradient established by sodium**
- **Water, as well as sodium, then diffuses into capillary blood** within the villus.
- **Water is thus absorbed into the intercellular space by diffusion down an osmotic gradient.**

Carbohydrates, After Digestion to Monosaccharides

- Polysaccharides and disaccharides must be digested to monosaccharides prior to absorption and the key players in these processes are the brush **border hydrolases**, which include **maltase, lactase and sucrase**.
- Dietary lactose and sucrose, and maltose derived from digestion of starch, diffuse in the small intestinal lumen and come in contact with the surface of absorptive epithelial cells covering the villi where they engage with brush border hydrolases:
 - **maltase cleaves maltose** into two molecules of glucose
 - **lactase cleaves lactose** into a glucose and a galactose
 - **sucrase cleaves sucrose** into a glucose and a fructose
- **Glucose and galactose are taken into the enterocyte by cotransport with sodium** using the same transporter
- **Fructose enters the cell from the intestinal lumen via facilitated diffusion through another transporter.**
- Glucose is transported out of the enterocyte through a different transporter (called GLUT-2) in the basolateral membrane.



Absorption of Amino Acids and Peptides

- Dietary proteins are, with very few exceptions, not absorbed. Rather, they must be digested into amino acids or di- and tripeptides first.
- Two sources secrete proteolytic enzymes into the lumen of the digestive tube:
 - the **stomach secretes pepsinogen**, which is converted to the active protease pepsin by the action of acid
 - the **pancreas secretes a group of potent proteases**, chief among them **trypsin, chymotrypsin and carboxypeptidases**.
- Through the action of these gastric and pancreatic proteases, dietary proteins are hydrolyzed within the lumen of the small intestine predominantly into medium and small peptides (oligopeptides).
- **Brush border peptidases** function to further the hydrolysis of luminal peptides, converting them to free amino acids and very small peptides.
- These end products of digestion, formed on the surface of the enterocyte, are ready for absorption.

Absorption of Amino Acids and Peptides

- The mechanism by which amino acids are absorbed is conceptually identical to that of monosaccharides.
- The luminal plasma membrane of the absorptive cell bears at least four **sodium-dependent amino acid transporters** - one each for acidic, basic, neutral and amino acids.
- The basolateral membrane of the enterocyte contains additional transporters which export amino acids from the cell into blood.

Absorption of Amino Acids and Peptides

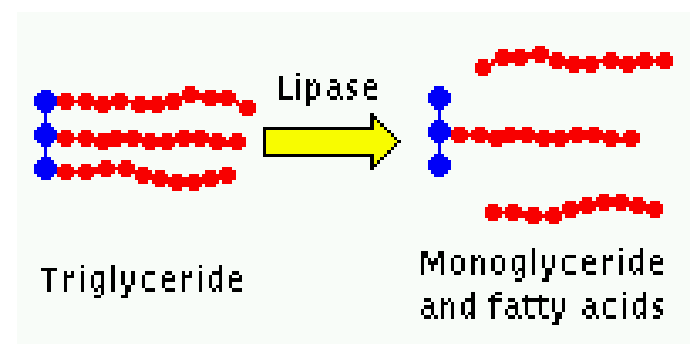
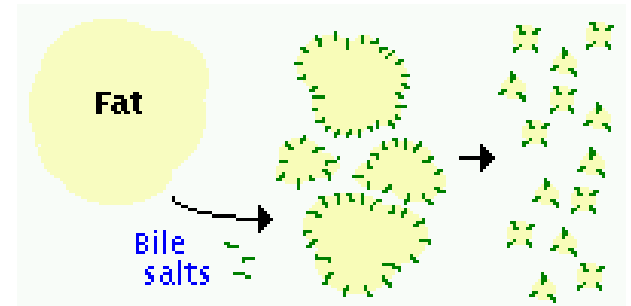
- **There is virtually no absorption of peptides longer than three amino acids. However, it seems that there is abundant absorption of di- and tripeptides in the small intestine.**
- These small peptides are absorbed without dependence on sodium, probably by a single transport molecule.
- Once inside the enterocyte, the vast bulk of di- and tripeptides are digested into amino acids by cytoplasmic peptidases and exported from the cell into blood.
- **Absorption of intact proteins occurs only in a few circumstances**
 - **One important exception to this general statement is that for a very few days after birth, neonates have the ability to absorb intact proteins.**
 - This ability, which is rapidly lost, is of immense importance because **it allows the newborns to acquire passive immunity** by absorbing immunoglobulins in colostrum milk.

Absorption of Lipids

- **In order for the triglyceride to be absorbed, two processes must occur:**
 - Large aggregates of dietary triglyceride, which are virtually insoluble in an aqueous environment, must be broken down physically and held in suspension –ie., emulsification.
 - Triglyceride molecules must be enzymatically digested to yield monoglyceride and fatty acids, both of which can efficiently diffuse into the enterocyte
- The key players in these two transformations are **bile salts and pancreatic lipase**, both of which are mixed with chyme and act in the lumen of the small intestine.

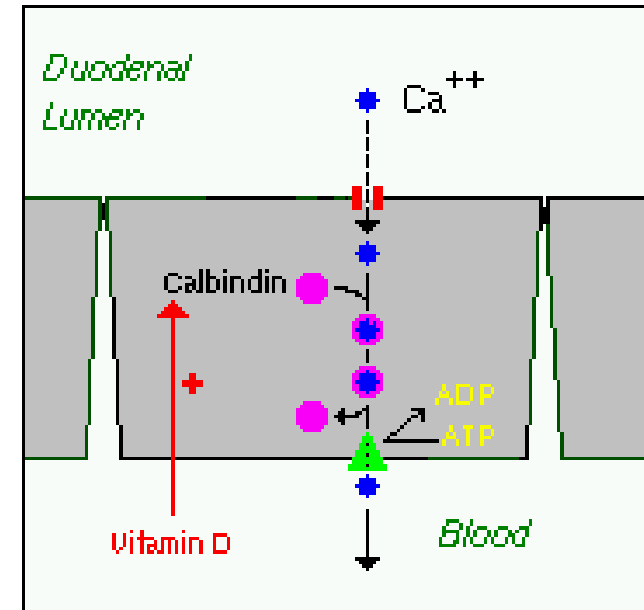
Absorption of Lipids

- **Bile salts** play their first critical role in lipid assimilation by promoting emulsification.
- Hydrolysis of triglyceride into monoglyceride and free fatty acids is accomplished predominantly by **pancreatic lipase**.



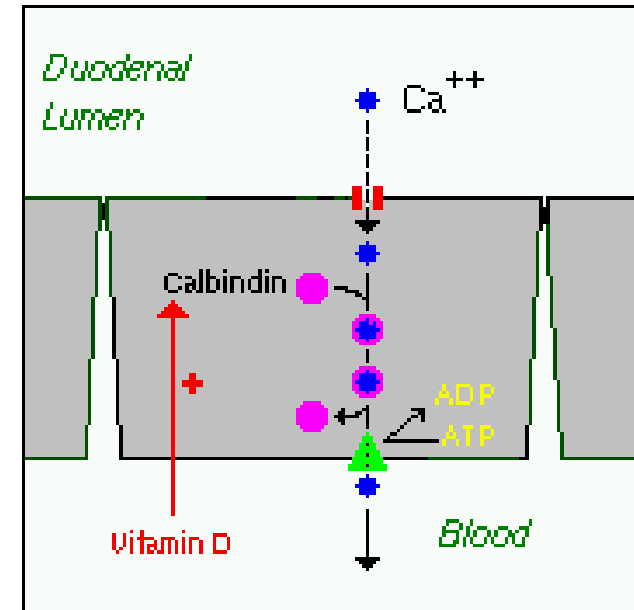
Absorption of Minerals and Metals: Calcium

- The quantity of calcium absorbed in the intestine is controlled by how much calcium has been in the diet during recent periods of time.
- Calcium is absorbed by two distinct mechanisms, and their relative magnitude of importance is set by dietary calcium "history":
 - **Active, transcellular absorption** occurs only in the duodenum when calcium intake has been low.
 - Calcium enters the intestinal epithelial cells through voltage-insensitive channels and is pumped out of the cell via a calcium-ATPase.



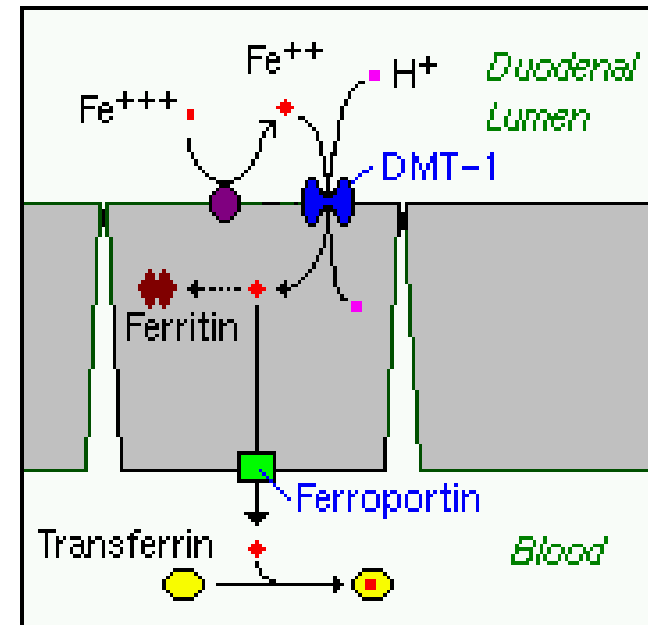
Absorption of Minerals and Metals: Calcium

- The **rate limiting step** in transcellular calcium absorption is **transport across the epithelial cell**, which is greatly **enhanced by** the carrier protein **calbindin**, the synthesis of which is totally **dependent on vitamin D**.
- **Passive, paracellular absorption** occurs in the jejunum and ileum, and, to a much lesser extent, in the colon **when dietary calcium levels have been moderate or high**.
 - In this case, ionized calcium diffuses through tight junctions into the basolateral spaces around enterocytes, and hence into blood.
 - Such transport depends on having higher concentrations of free calcium in the intestinal lumen than in blood.



Absorption of Minerals and Metals: Iron

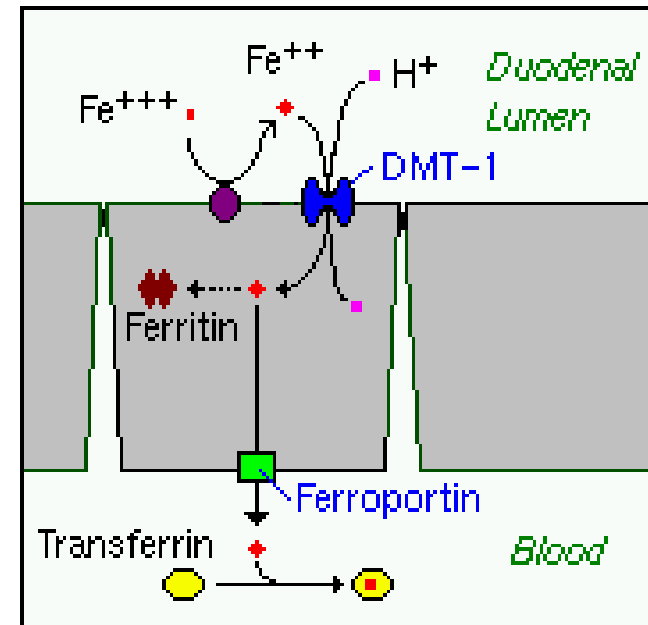
- **Iron homeostasis is regulated at the level of intestinal absorption, and it is important that adequate but not excessive quantities of iron be absorbed from the diet.**
- Inadequate absorption can lead to iron-deficiency disorders such as anemia. On the other hand, excessive iron is toxic because mammals do not have a physiologic pathway for its elimination.
- **Iron is absorbed by villus enterocytes in the proximal duodenum.**
- Efficient absorption requires an acidic environment, and antacids or other conditions that interfere with gastric acid secretion can interfere with iron absorption.
- Ferric iron (Fe^{+++}) in the duodenal lumen is reduced to its ferrous form through the action of a brush border ferrireductase



Absorption of Minerals and Metals:

Iron

- Iron is cotransported with a proton into the enterocyte via the divalent metal transporter DMT-1.
 - This transporter is not specific for iron, and also transports many divalent metal ions.
- Once inside the enterocyte, iron follows one of two major pathways. Which path is taken depends on a complex programming of the cell based on both dietary and systemic iron loads:
 - **Iron abundance states:** iron within the enterocyte is trapped by incorporation into ferritin and hence, not transported into blood. When the enterocyte dies and is shed, this iron is lost.
 - **Iron limiting states:** iron is exported out of the enterocyte via a transporter (ferroportin) located in the basolateral membrane. It then binds to the iron-carrier transferrin for transport throughout the body.

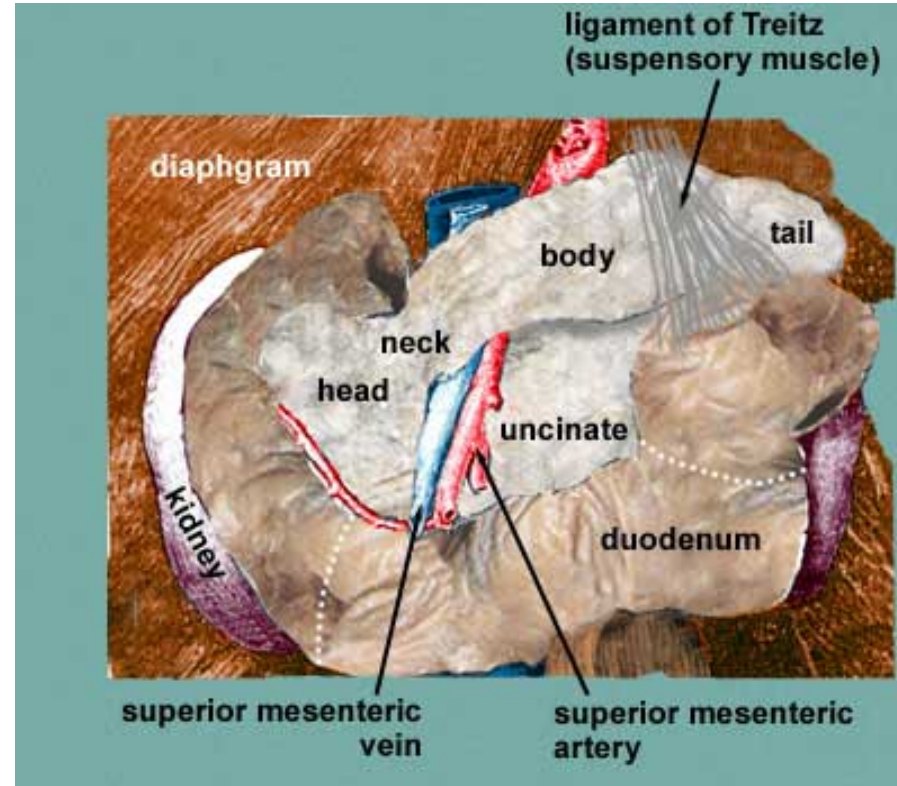


Intestinal Motility

- In most animals, the **small intestine cycles through two states**, each of which is associated with distinctive patterns of motility:
 - **Following a meal**, when the lumen of the small intestine contains chyme, two types of motility predominate:
 - **segmentation contractions** chop, mix and roll the chyme and
 - **peristalsis** slowly propels it toward the large intestine.
 - The **interdigestive state** is seen between meals, when the lumen is largely devoid of contents.
 - During such times, so-called **housekeeping contractions** propagate from the stomach through the entire small intestine, sweeping it clear of debris.
 - This complex pattern of motility is also known as the **migrating motor complex** and is the cause of "growling".
- **Motility in the small intestine**, as in all parts of the digestive tube, is **controlled** predominantly **by excitatory and inhibitory signals from the enteric nervous system**.
- These local **nervous signals** are however **modulated by inputs from the central nervous system**, and a number of **gastrointestinal hormones**

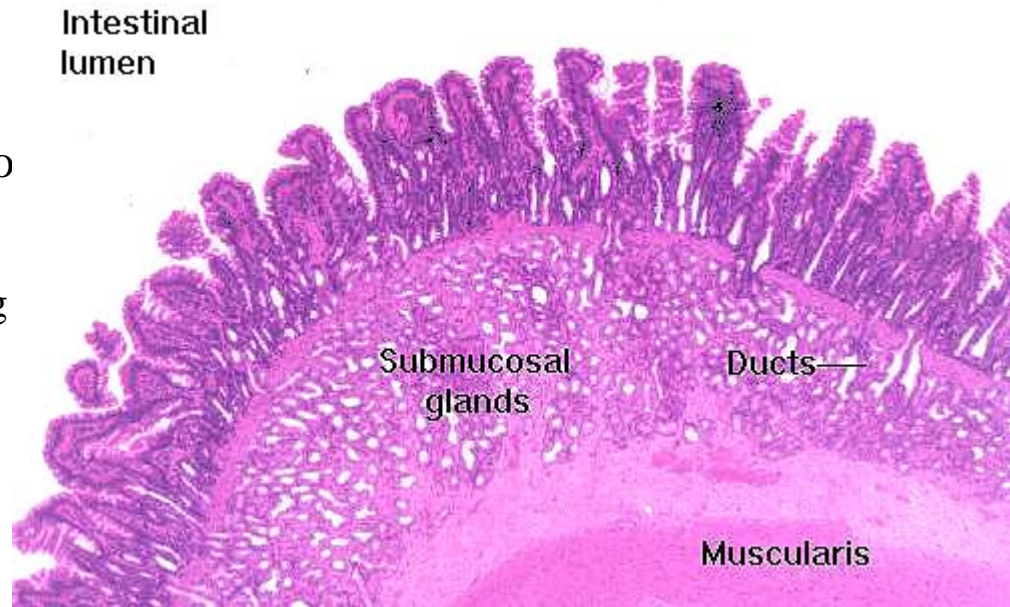
Duodenum

- The duodenum, into which the stomach opens,
 - is about 25 cm long,
 - C-shaped and
 - begins at the pyloric sphincter.
 - It is almost entirely retroperitoneal
 - and is the most fixed part of the small intestine.
- The duodenum is described as having four parts:
 - superior part
 - descending part
 - horizontal part
 - ascending part
- The fourth part of the duodenum terminates at the **duodenojejunal flexure** with the jejunum.
- The **ligament of Treitz** is a musculofibrous band that extends from the upper aspect of the ascending part of the duodenum to the right crus of the diaphragm and tissue around the celiac artery.

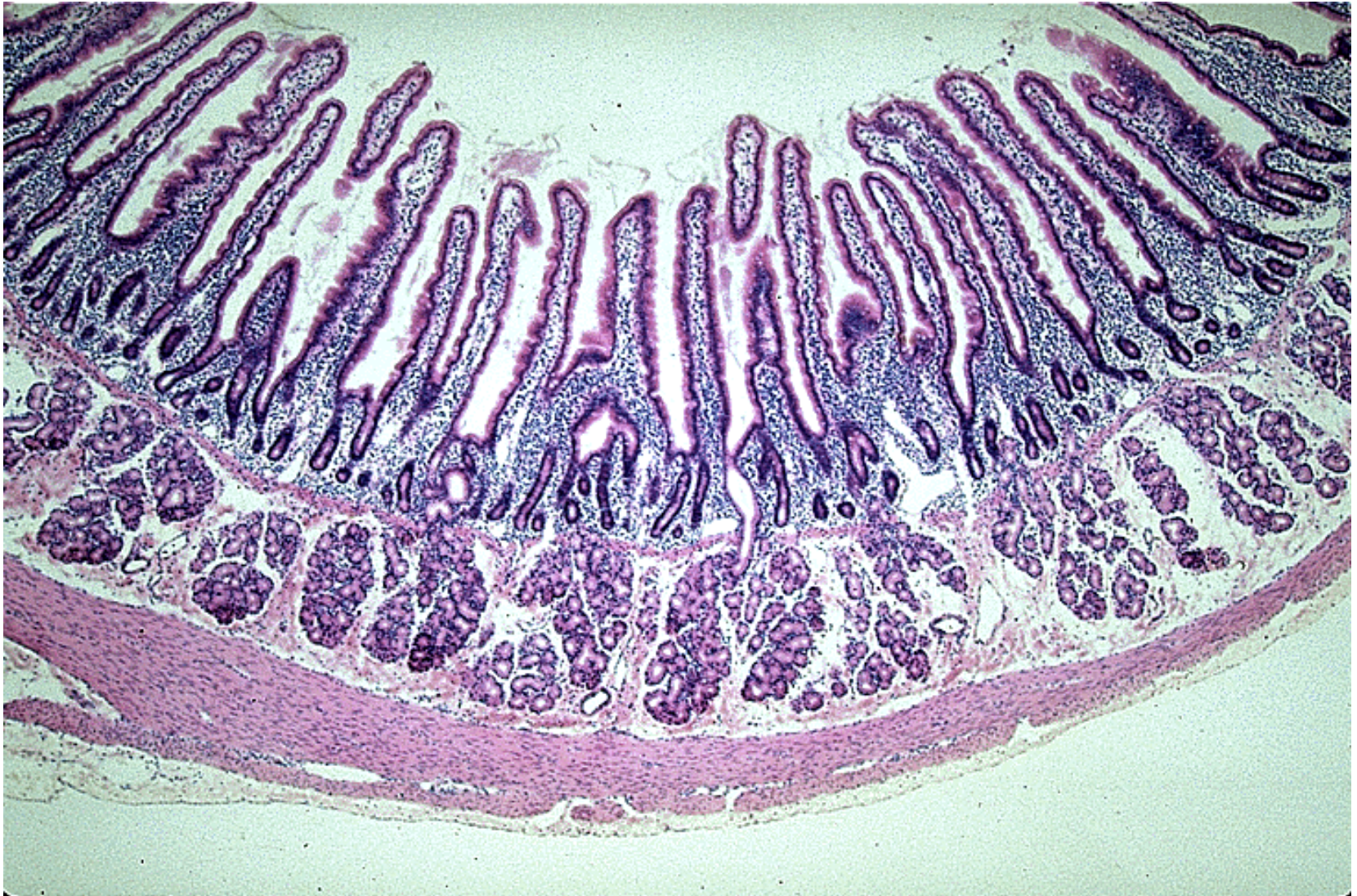


Duodenum

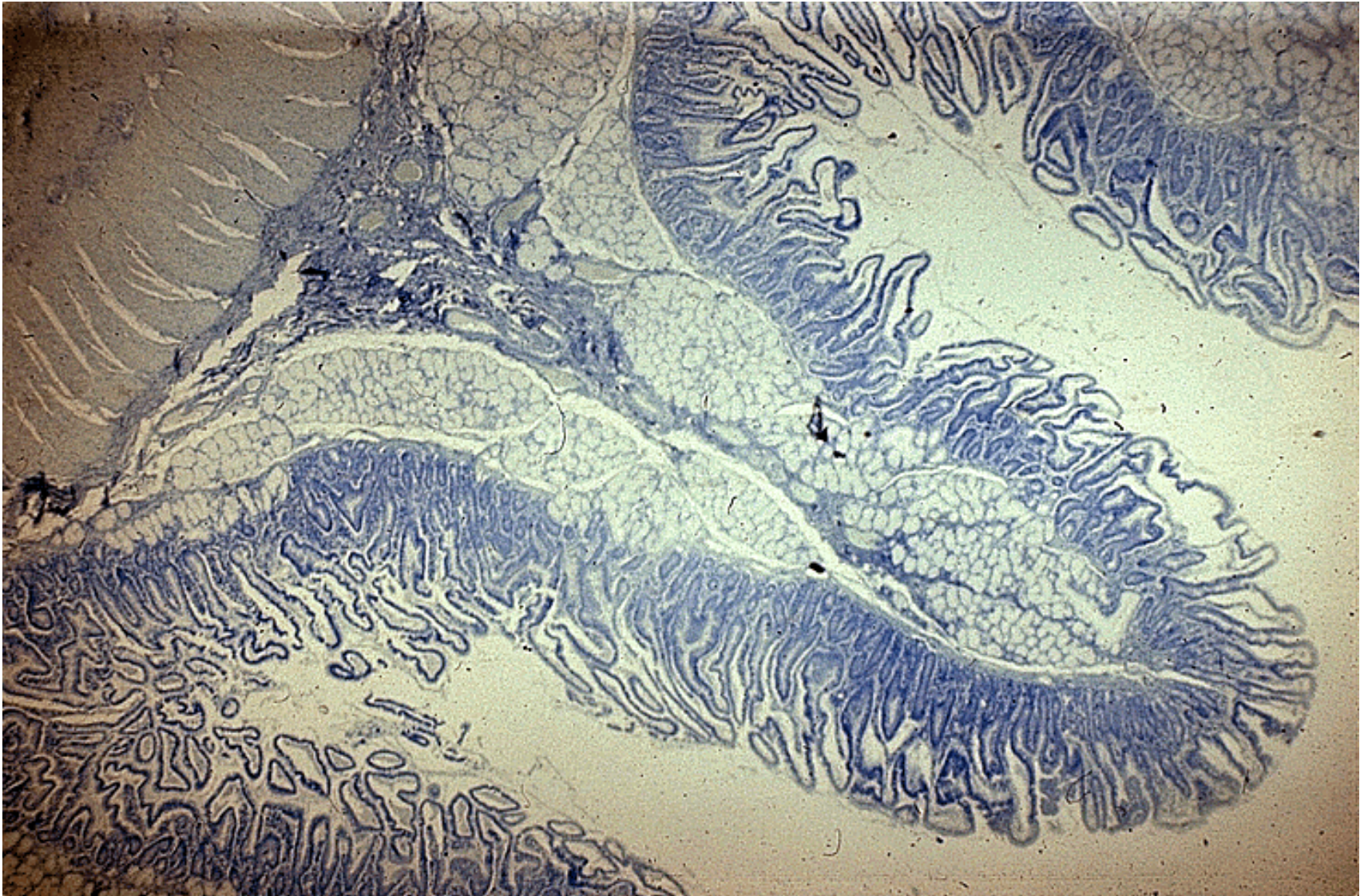
- The **villi** in this portion of the small intestine are short and broad with blunt tops, quite unlike the longer and more slender villi seen in the deeper parts of the gut.
- the "landmark" for this region of the digestive tract, is the **submucosal glands** o "**Brunner's glands.**"
 - **make an alkaline material that acts to neutralize the very acidic chyme** entering the duodenum through the pylorus.
 - Secretes **urogastrone**- a hormone that inhibits secretion of HCl by the parietal cells
 - The ducts of the glands (as seen in this slide) perforating through the muscularis mucosae and into the base of the duodenal crypts.
- Note that **this is one of only two places in the digestive tract where the glands are in the submucosa!** Except for the esophageal glands proper, all the other glands in the alimentary canal are found in the mucosal tunic.



Brunner's Glands

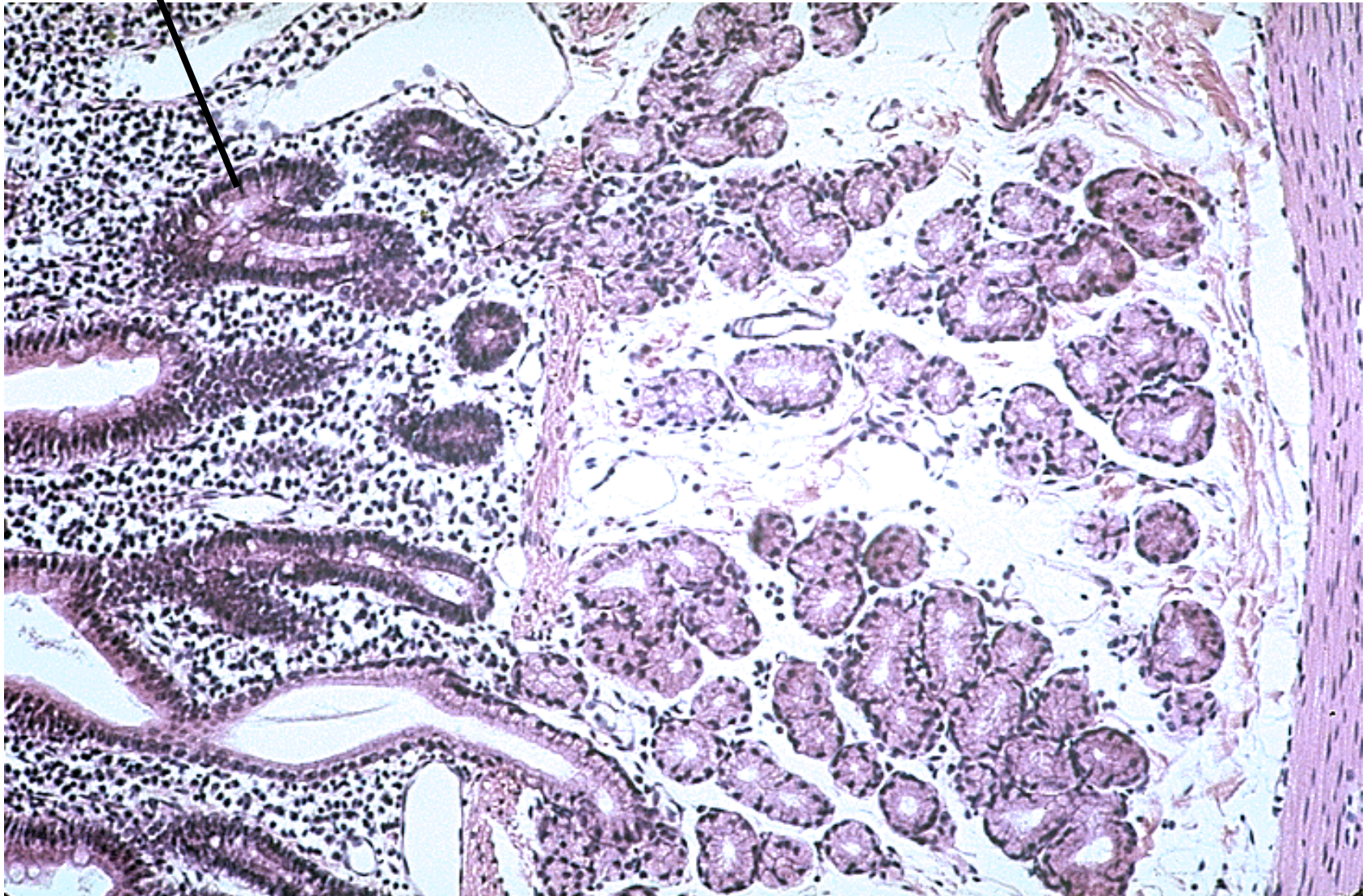


Duodenum Plicae & Villi

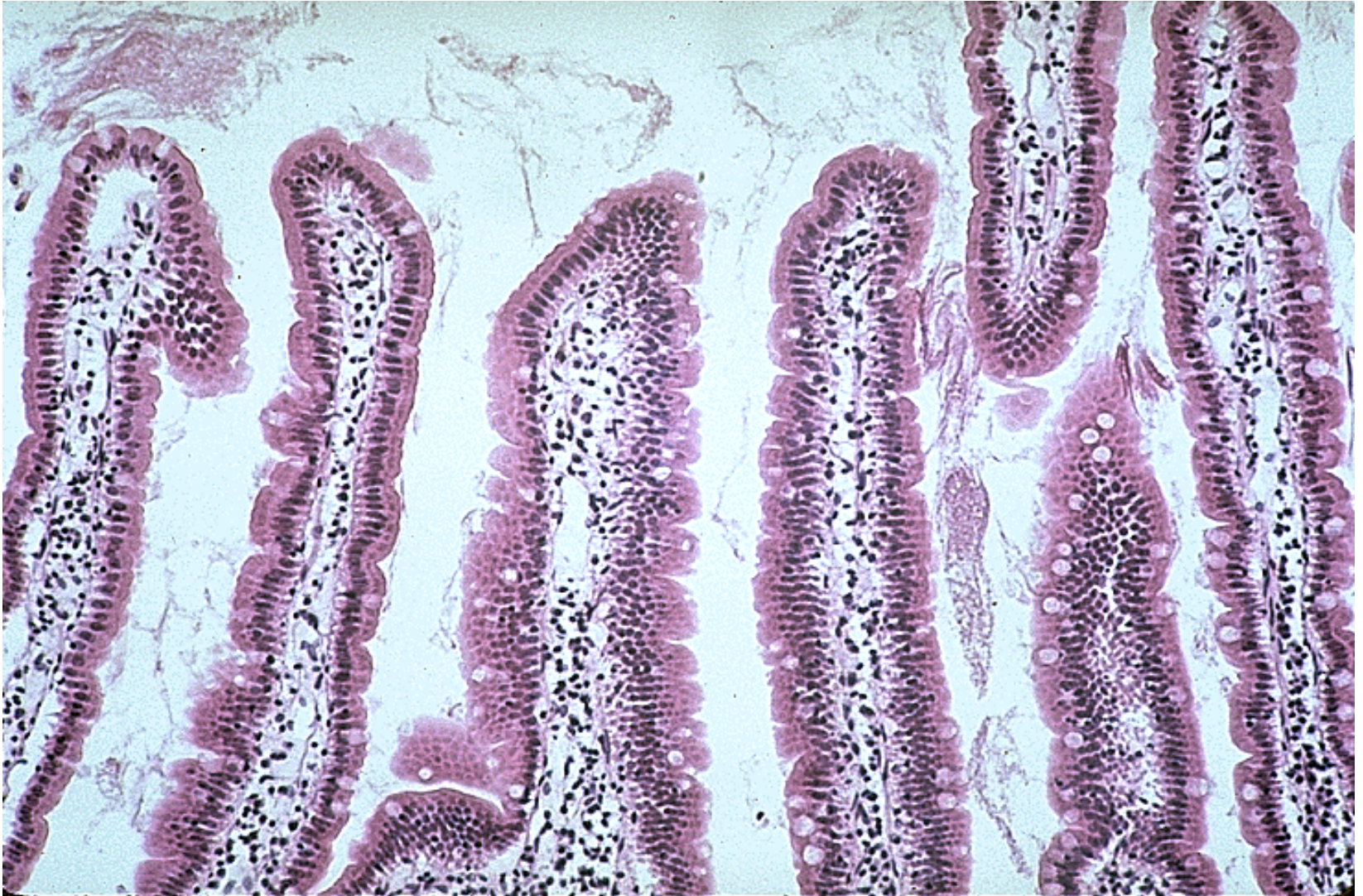


Brunner's Glands

Intestinal gland



Duodenal Villi



Large Intestine

Functions in three processes

- **Recovery of water and electrolytes from ingesta:** By the time ingesta reaches the terminal ileum, roughly 90% of its water has been absorbed, but considerable water and electrolytes like sodium and chloride remain and must be recovered by absorption in the large gut.
- **Formation and storage of feces:** As ingesta is moved through the large intestine, it is dehydrated, mixed with bacteria and mucus, and formed into feces.
- **Microbial fermentation:** The large intestine of all species teems with microbial life. Those microbes produce enzymes capable of digesting many of molecules that to vertebrates are indigestible, cellulose being a premier example. The extent and benefit of fermentation also varies greatly among species.

Large Intestine

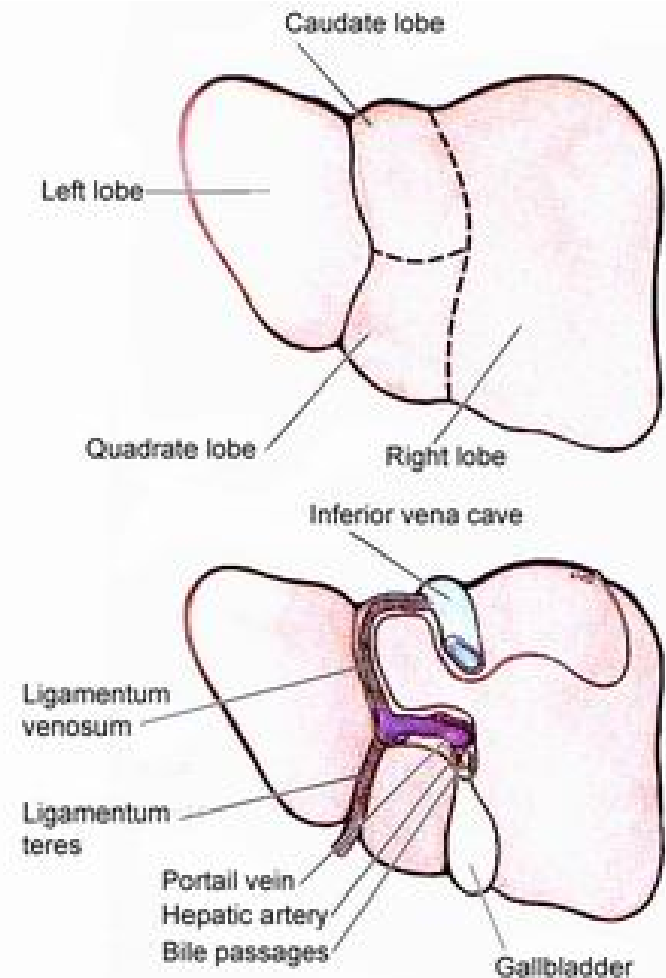
- **digestive tube between the terminal ileum and anus.**
- **ingesta from the small intestine enters the large intestine through either the ileocecal**
- **Within the large intestine, three major segments are recognized:**
- **the cecum** is a blind-ended pouch that in humans carries a worm-like extension called the vermiform **appendix**.
- **the colon** constitutes the majority of the length of the large intestine and is subclassified into ascending, transverse and descending segments.
- **the rectum** is the short, terminal segment of the digestive tube, continuous with the anal canal.

Liver

- The heaviest gland in the body, weighting about 3 lbs in the average adult.
- It is located under the diaphragm, mostly on the right side of the abdominal cavity.
- It is covered by a connective tissue capsule and the visceral peritoneum.
- Its 3 major functions are:
 - Production of bile: the main digestive function.
 - Metabolic activities relating to carbohydrate, fat and protein.
 - Filtration of blood to remove bacteria and foreign particles that enters the blood from the lumen of the intestine.

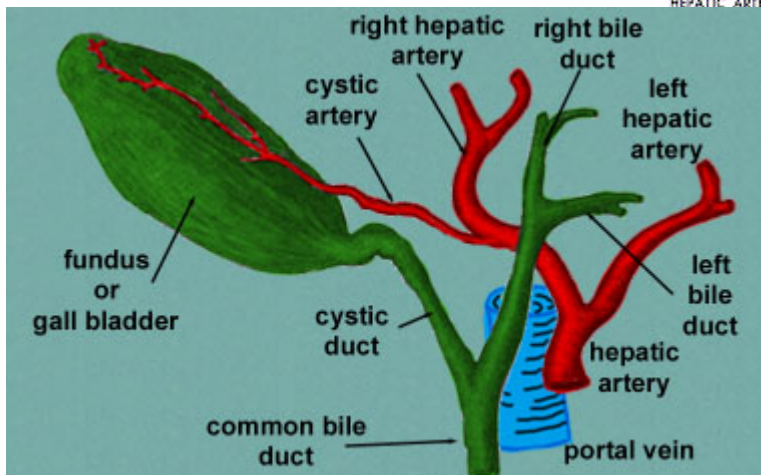
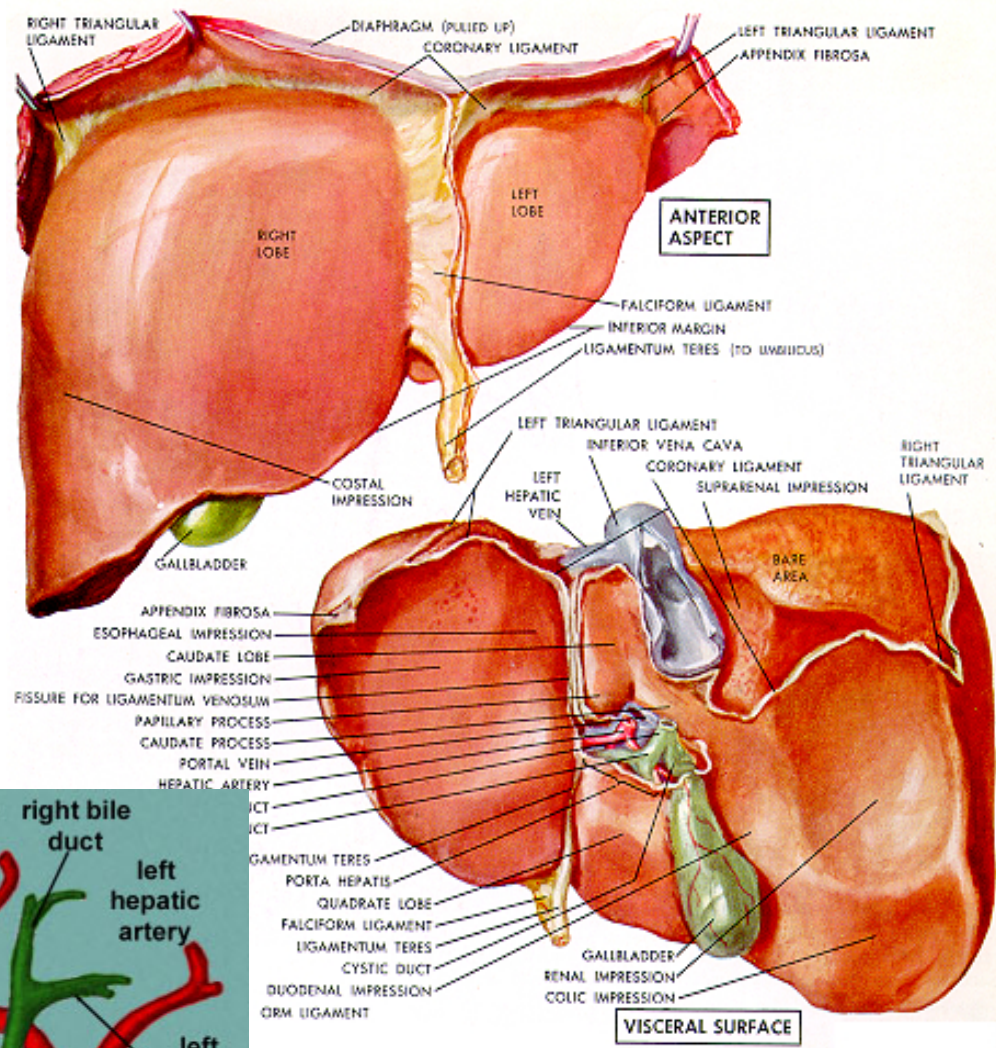
Liver

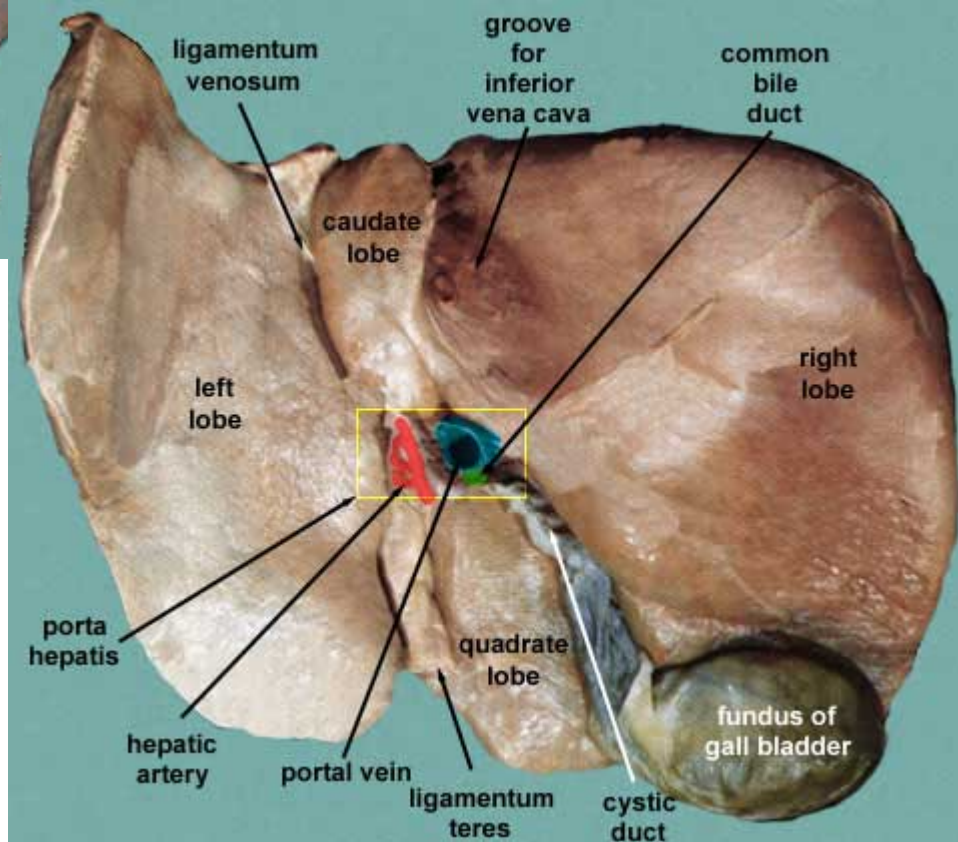
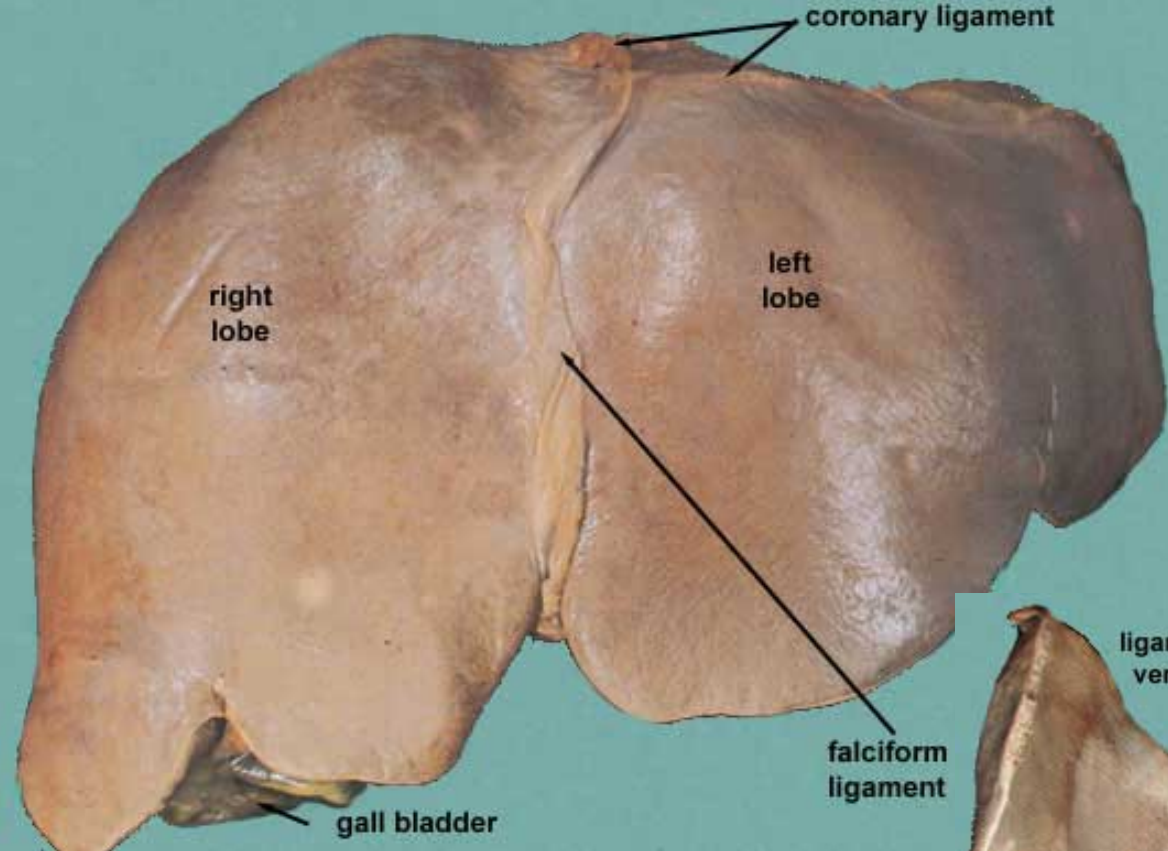
- Anatomically, the **falciform ligament** (a fold of peritoneum attaching the liver to the anterior abdominal wall at the level of umbilicus and the diaphragm) divides the liver into a
 - large **right lobe**
 - further divided into a **quadrate lobe** and a **caudate lobe** by **gallbladder**, **ligamentum venosum** and **ligamentum teres** (the sickle-shaped free margin of the **falciform ligament**).
 - small **left lobe**.
- The caudate and quadrate lobes are functionally part of the left lobe.
- Each functional (portal) lobe has its own vascular supply from the hepatic artery and portal vein.



Liver

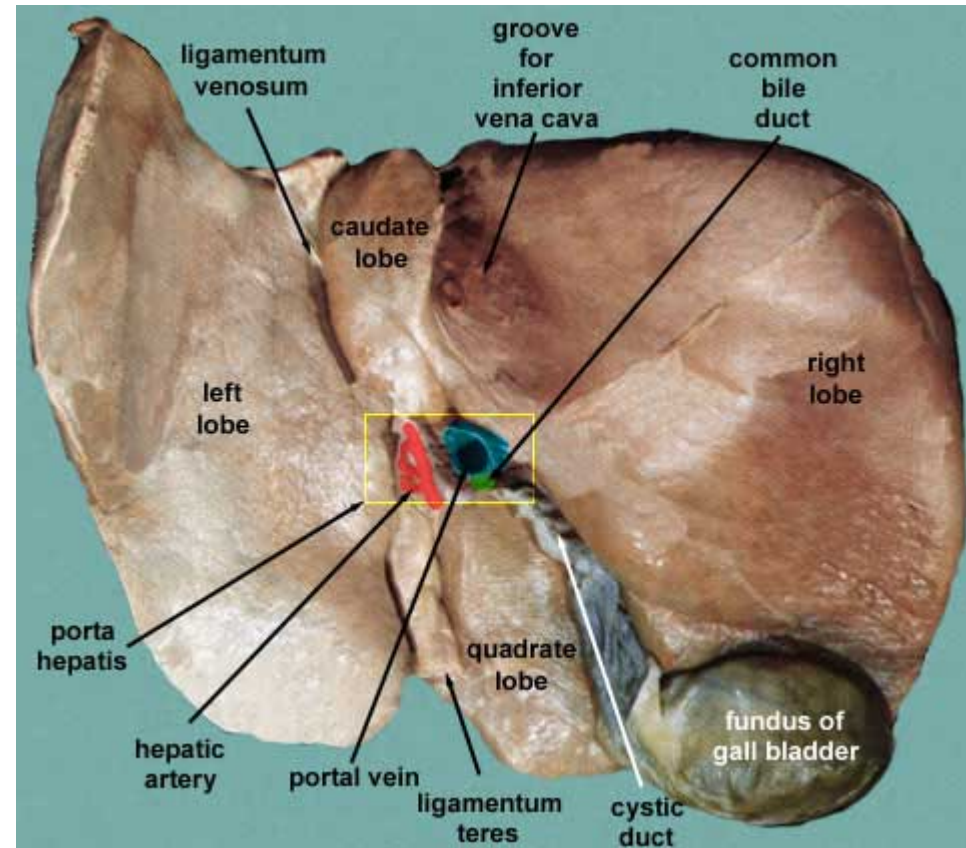
- Found on the inferior surface of the right lobe is the gallbladder
- The entire liver is surrounded by a serosa except for a bare area fused to the diaphragm.
- The hepatic artery, hepatic portal vein and common hepatic duct all travel to/from the liver via the **lesser omentum** (which anchors the liver to the lesser curvature of the stomach).
- Bile leaves the liver through several **bile ducts** that form the **left and right hepatic ducts** which then combine to yield the **common hepatic duct**.
- The common hepatic duct will fuse with the **cystic duct** from the gallbladder to form the **common bile duct** which empties into the duodenum.





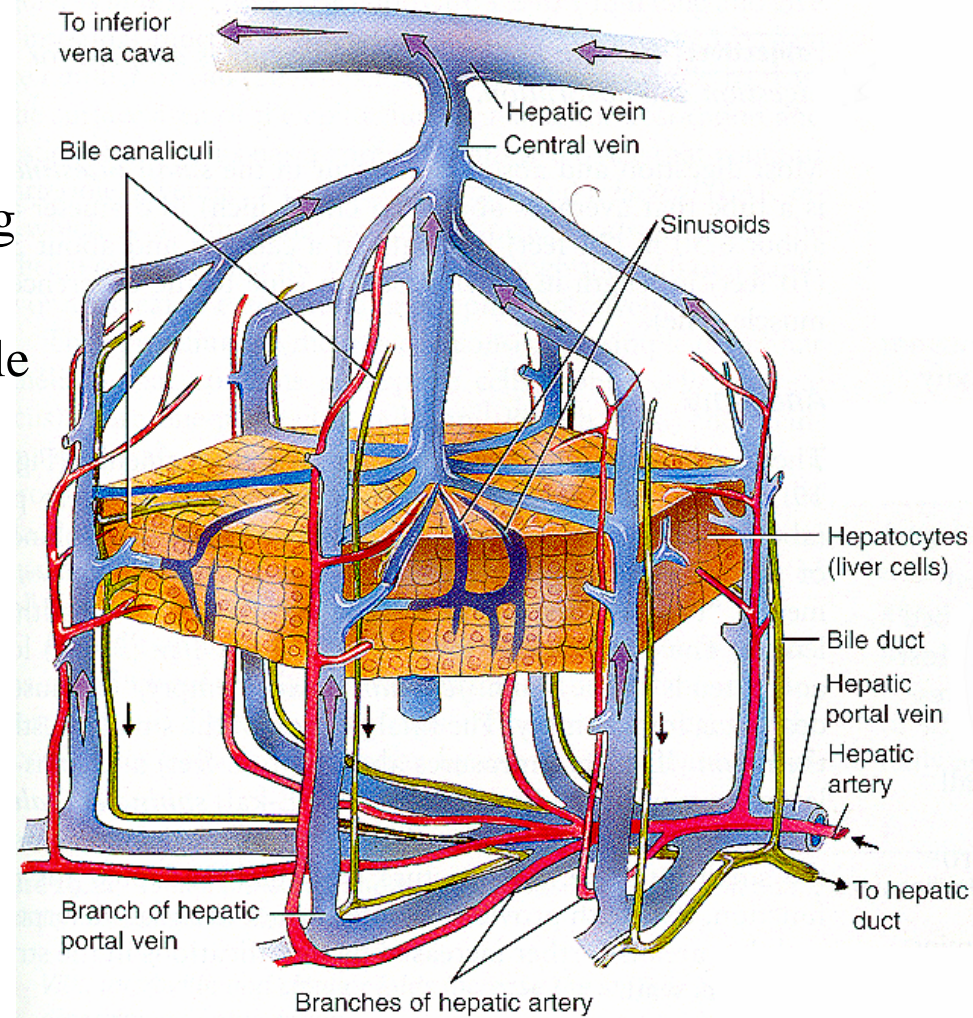
Liver

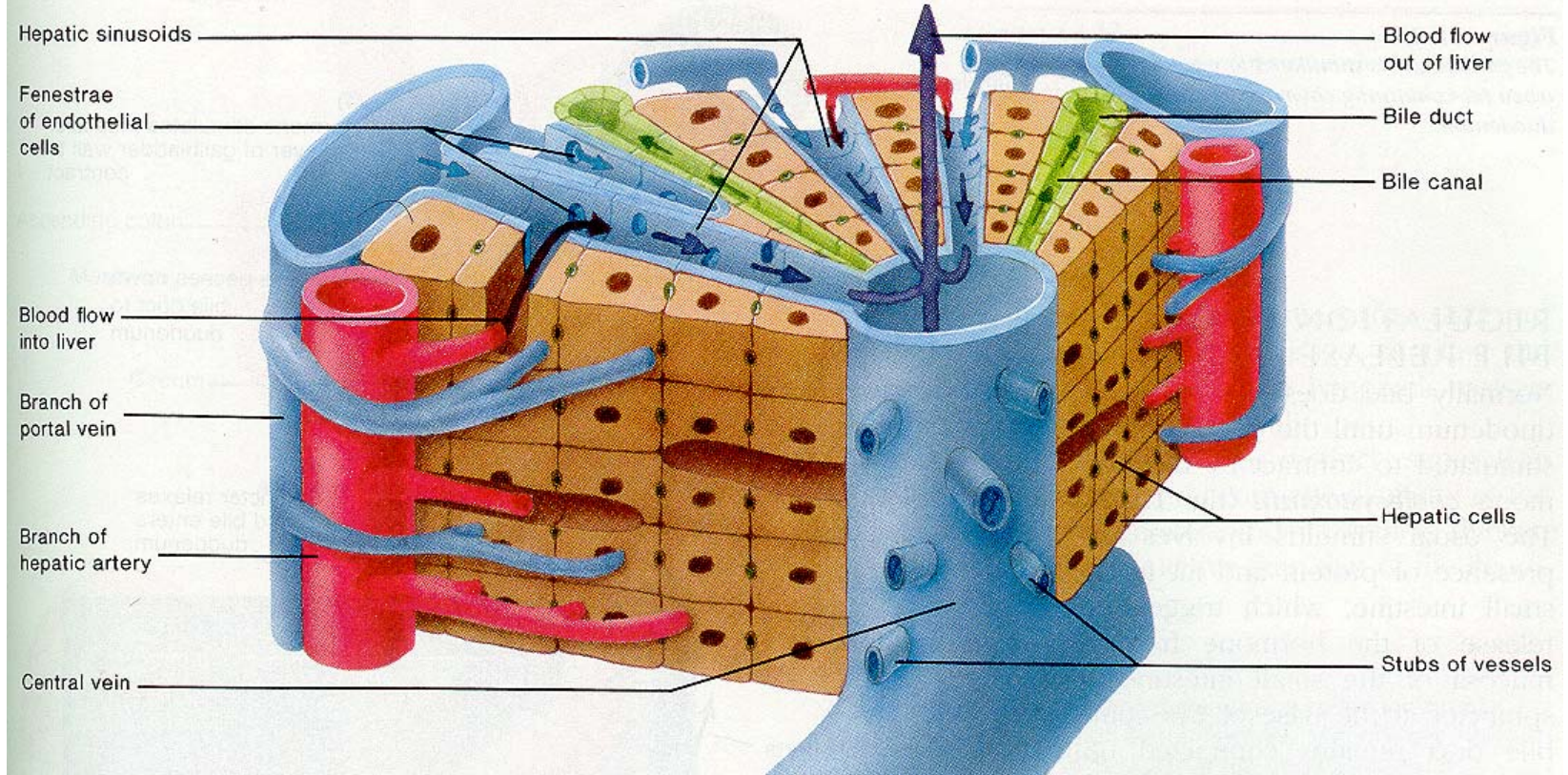
- The **hepatic artery** and **portal vein** enter the liver while the **hepatic ducts** leave the liver through the **porta hepatis**
- Lymphatic vessels and hepatic nerve plexus also pass through the same passage.



Liver: Microanatomy

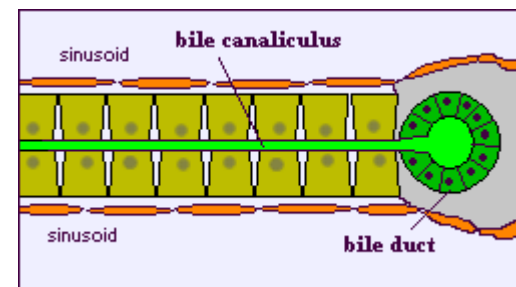
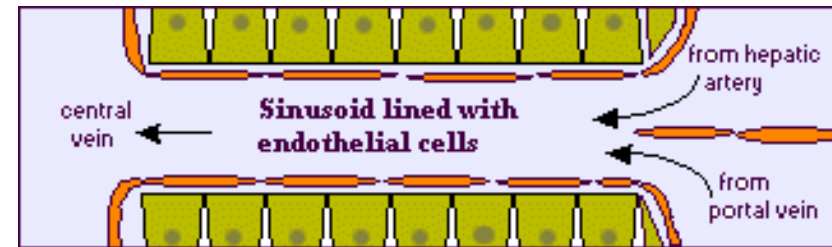
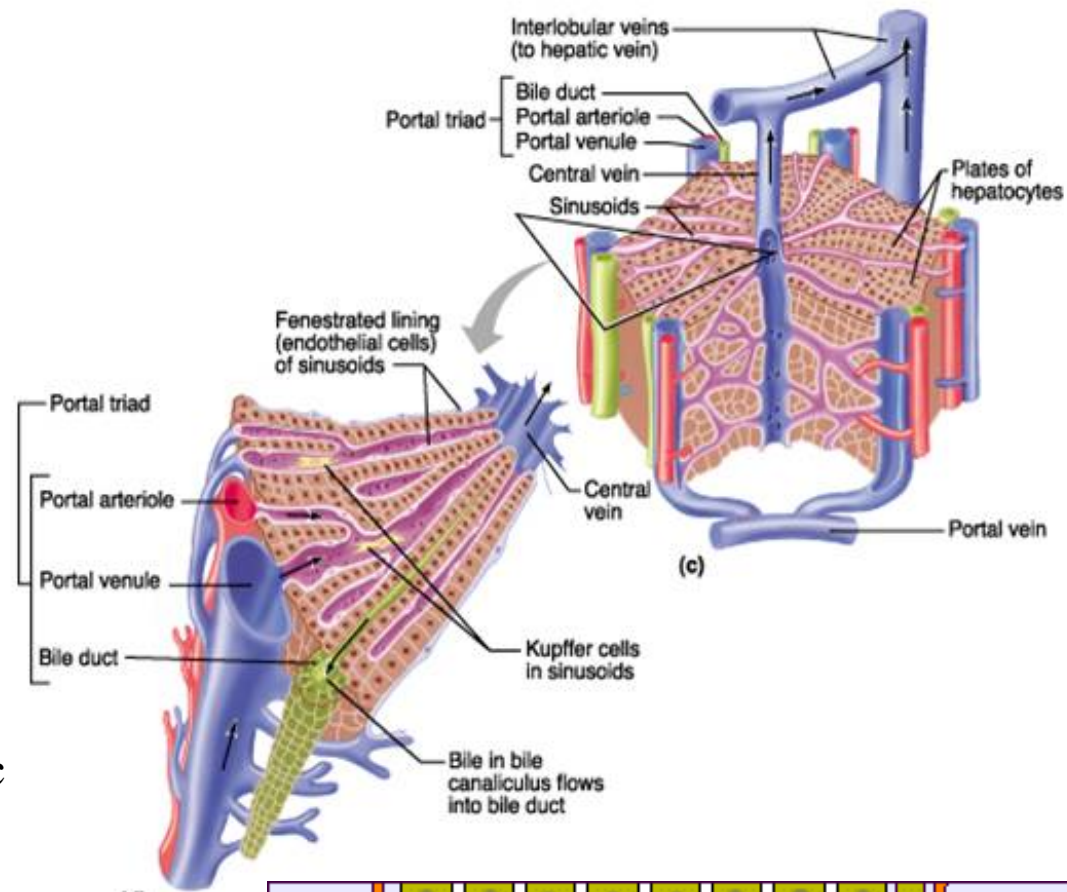
- **Lobules**-functional units of the liver
 - a hexagonal structure made up of hepatocytes (liver cells) surrounding a central vein.
 - At each of the 6 corners of the lobule is a portal triad
 - Blood will enter the lobule via a branch of the **hepatic artery** or a branch of the **hepatic vein**.
 - Connecting these 2 with the central vein are the liver **sinusoids**.
 - Central veins from all the lobules eventually give rise to the **hepatic veins**.





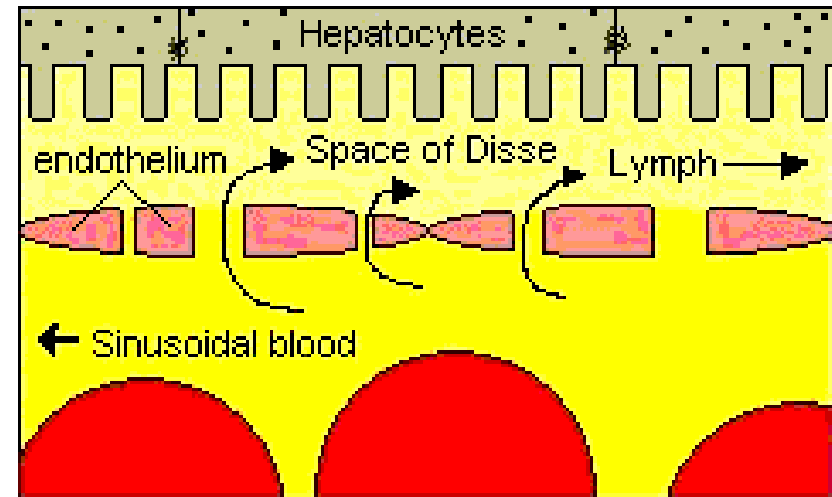
- **sinusoids**- channels that separate groups of hepatocytes. Blood from the portal vein brings nutrients to the hepatocytes via the sinusoids.
 - blood rich in oxygen and nutrients will percolate through these sinusoids alongside the hepatocytes and towards the central vein.
- **Stellate reticuloendothelial cells** (Kupffer cells)- partly line the sinusoids that function to destroy worn-out white and red cells, bacteria, and toxic substances.
- **Bile canaliculi**- small channels that course between the hepatocytes that relay bile to the right and left hepatic ducts.
- **Common hepatic duct**- formed when the right and left hepatic ducts unite to a single tube to leave the liver.
- **Cystic duct**- duct that leads from the gallbladder.
- **Common bile duct**- formed from the uniting of the cystic duct and the common bile duct.

- As blood flows, the hepatocytes
 - exchange O₂ for CO₂ and
 - take up nutrients for processing and storage.
 - take up fat-soluble vitamins (A,D,E,K) for storage,
 - take up toxins for detoxification,
 - they produce bile.
 - Blood flows through the sinusoids and empties into the central vein of each lobule.
 - Central veins coalesce into hepatic veins, which leave the liver and empty into the vena cava.
- Bile flows thru the lobule in the opposite direction of the blood.
- Hepatocytes secrete bile into small channels called **bile canaliculi**.
- Bile canaliculi run to the **bile ducts** in the portal triads.



Formation of Lymph in the Liver

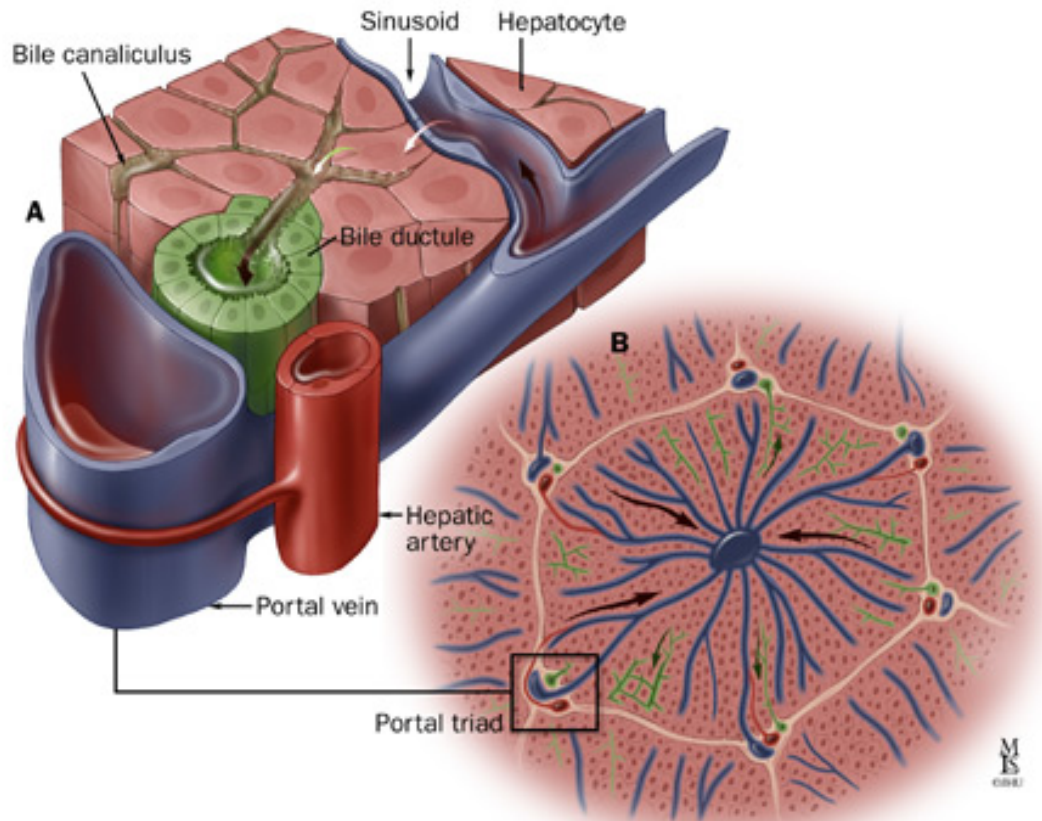
- **Approximately half of the lymph formed in the body is formed in the liver.**
- Due to the large pores or fenestrations in sinusoidal endothelial cells, fluid and proteins in blood flow freely into the space between the endothelium and hepatocytes (the "**space of Disse**"), forming lymph.
- **Lymph flows through the space of Disse to collect in small lymphatic capillaries associated with portal triads**
- **if pressure in the sinusoids increases much above normal, there is a corresponding increase in the rate of lymph production.**
 - In severe cases the liver literally sweats lymph, which accumulates in the abdominal cavity as **ascitic fluid**.

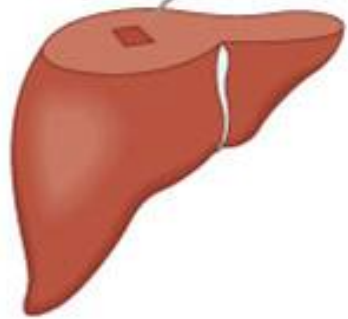


Liver


Hepatic (portal) triad

- located where two or more lobules meet
- Contain the portal vein, hepatic artery, and bile ductule



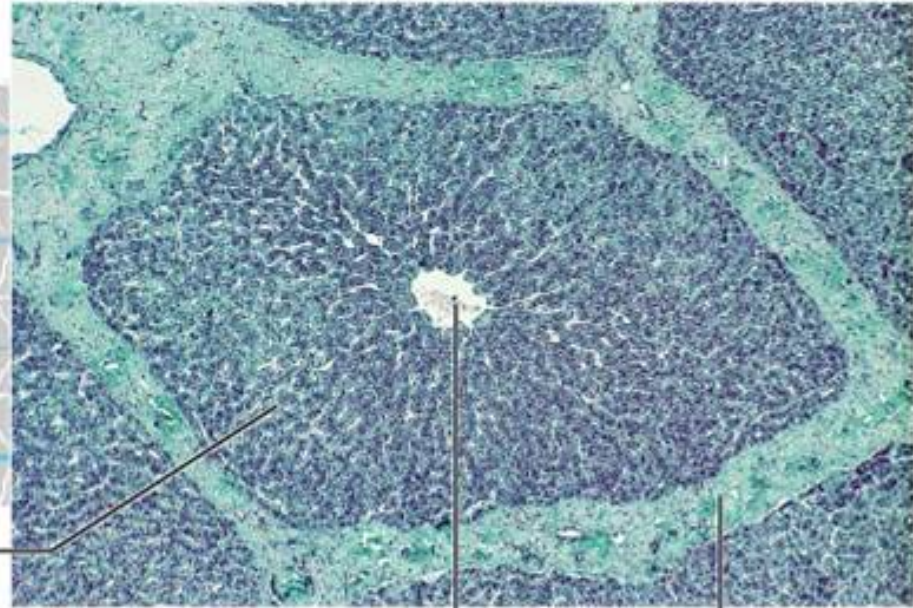


(a)



Lobule

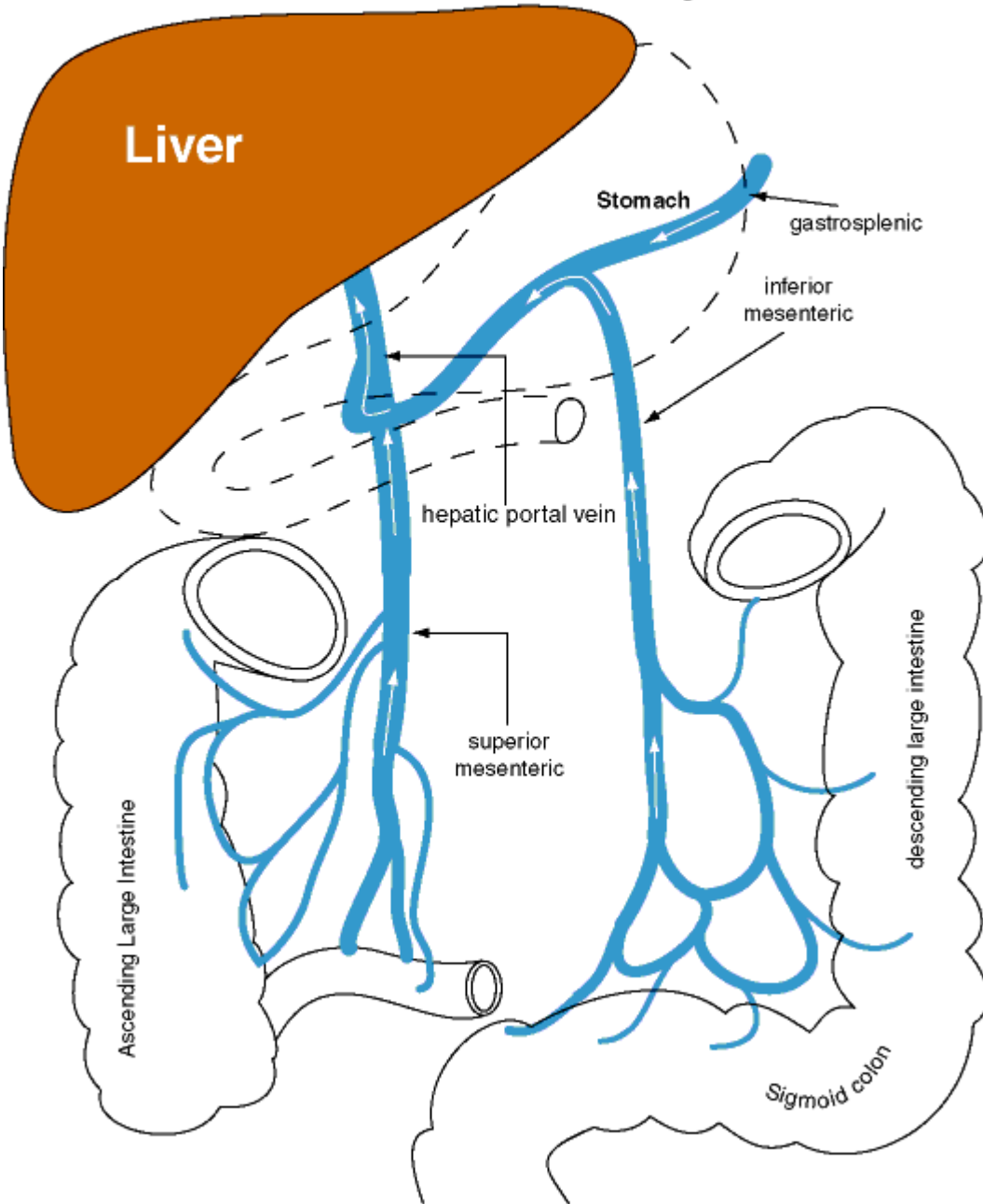
(b)



Central vein

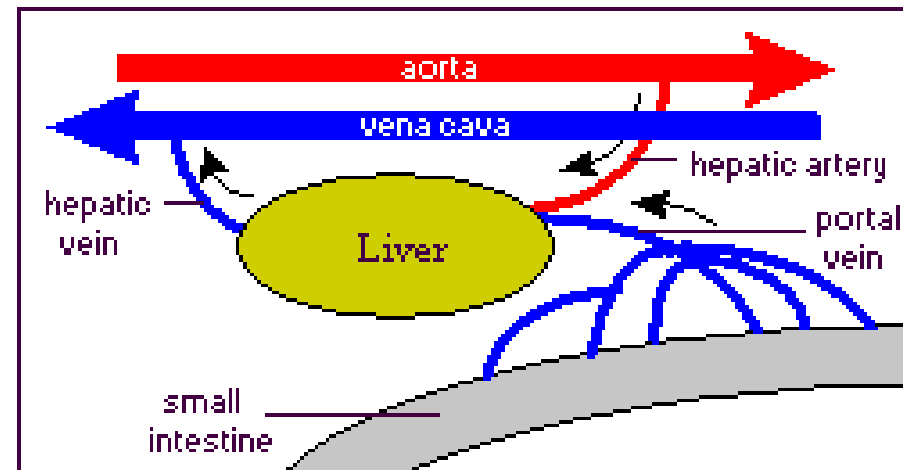
Connective tissue septum

Hepatic Portal System



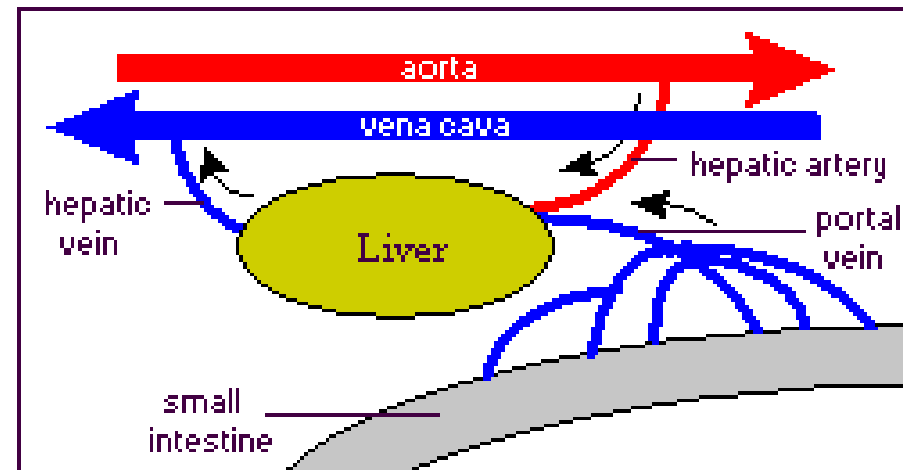
Liver Blood Supply

- **The circulatory system of the liver is unlike that seen in any other organ.**
- **Of great importance is the fact that a majority of the liver's blood supply is venous blood!**
 - **Roughly 75% of the blood entering the liver is venous blood from the portal vein.**
 - all of the venous blood returning from the small intestine, stomach, pancreas and spleen converges into the portal vein.
 - One consequence of this is that the liver gets "first pickings" of everything absorbed in the small intestine, which, as we will see, is where virtually all nutrients are absorbed.

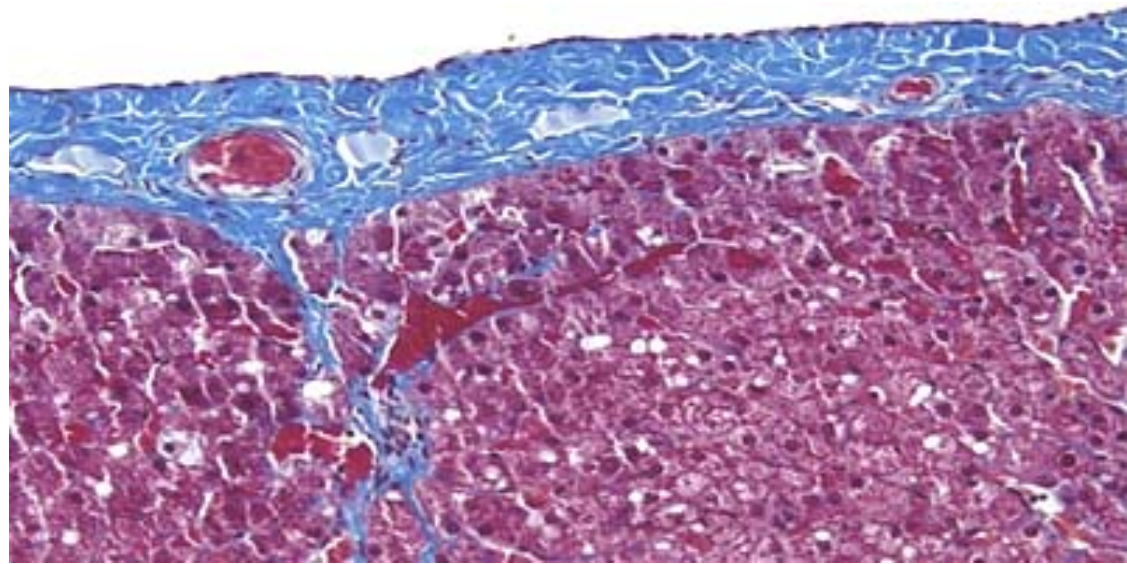


Liver Blood Supply

- The remaining 25% of the blood supply to the liver is arterial blood from the hepatic artery.
- Terminal branches of the hepatic portal vein and hepatic artery empty together and mix as they enter sinusoids in the liver.

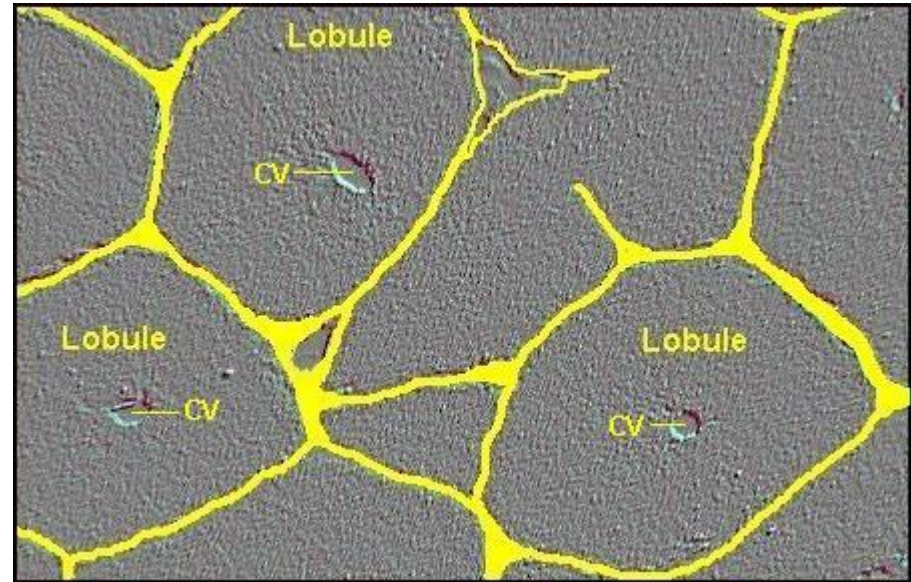
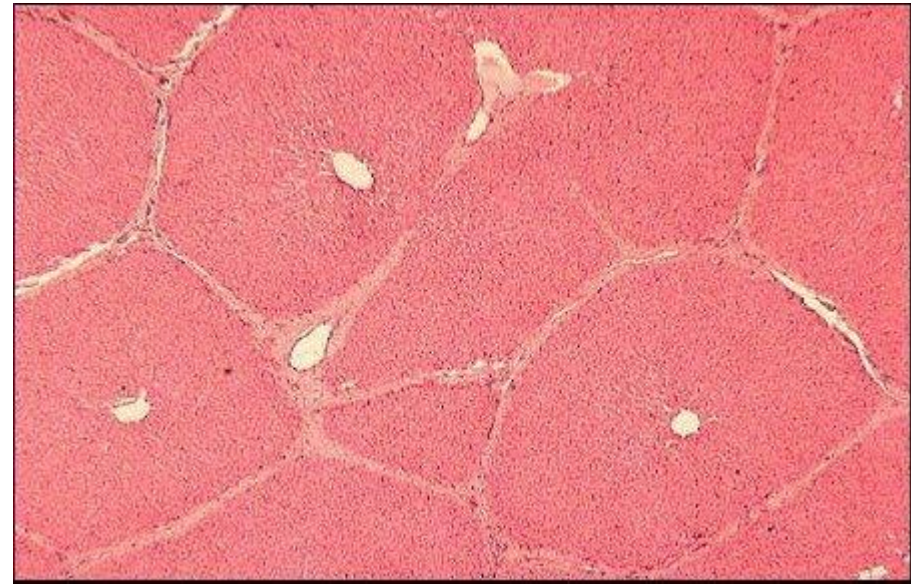


- The liver is bounded by a connective tissue capsule which extends into its substance as highly branched **septae**.
- In the section of equine liver below (Masson's trichrome stain), the capsule and septae are stained blue , while hepatocytes are magenta . Notice how the capsule extends as a septum into the liver about one-third of the way from left, immediately below a large capsular blood vessel.



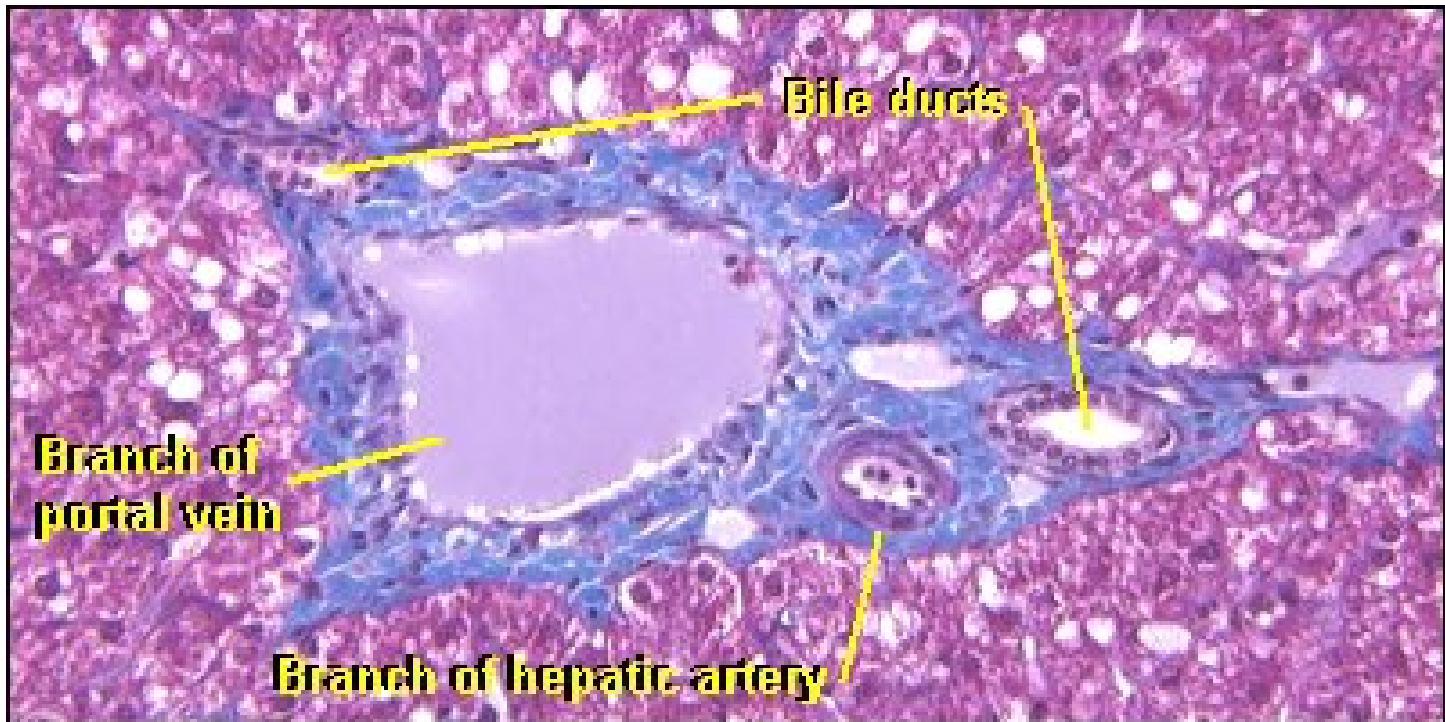
Liver

- The **connective tissue septae** invaginating from the capsule delineate **hepatic lobules**, the structural unit of the liver.



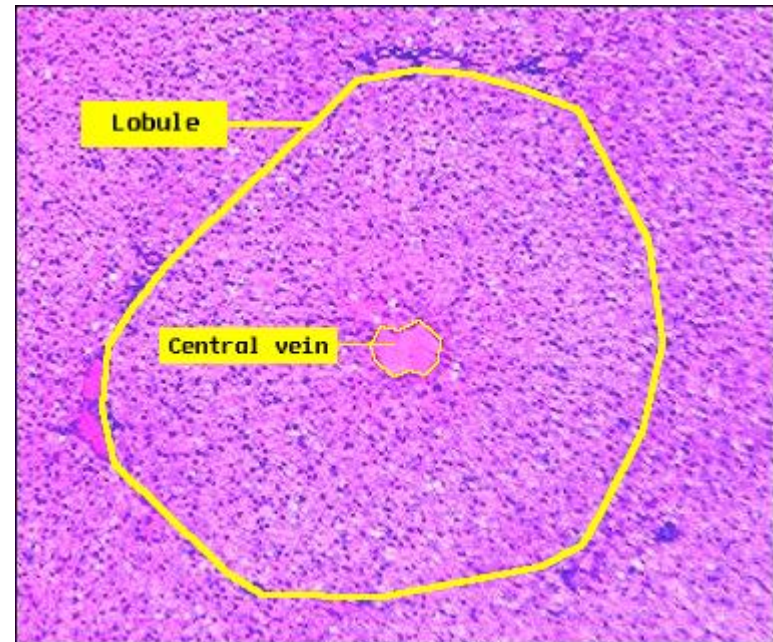
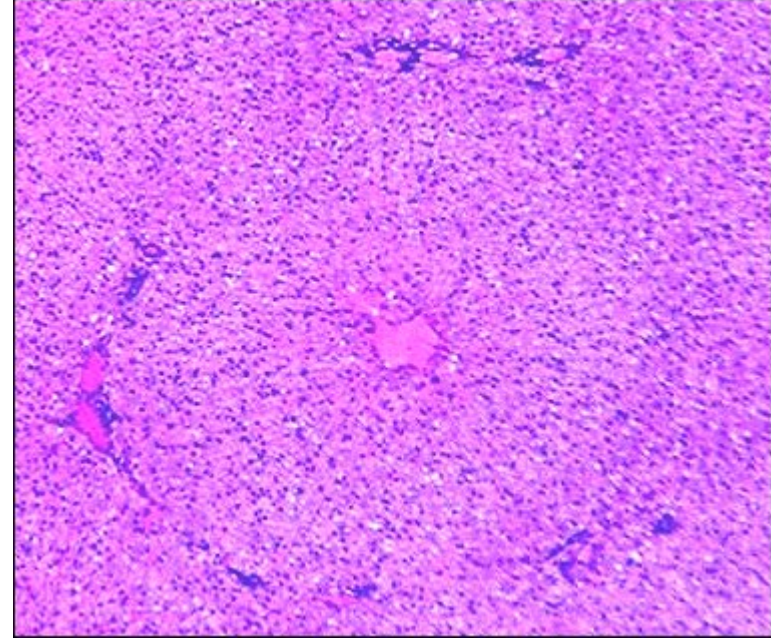
Liver

Portal Triad



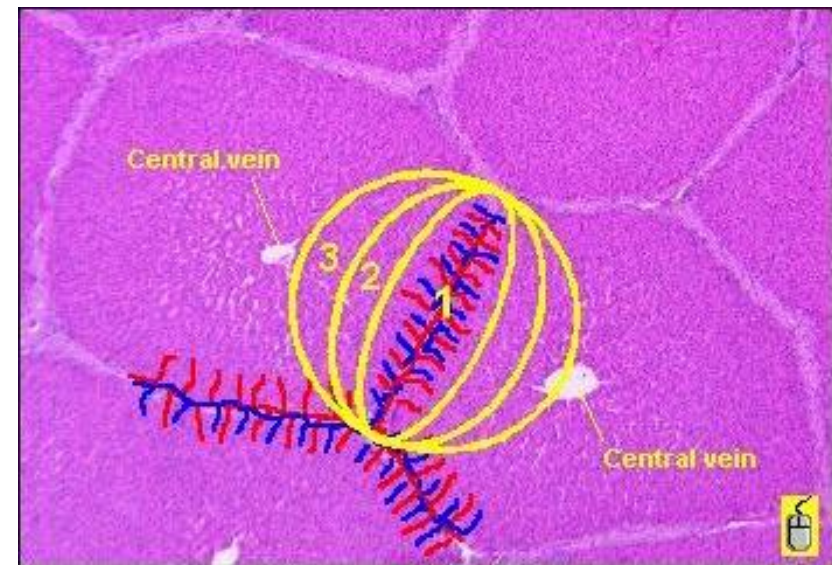
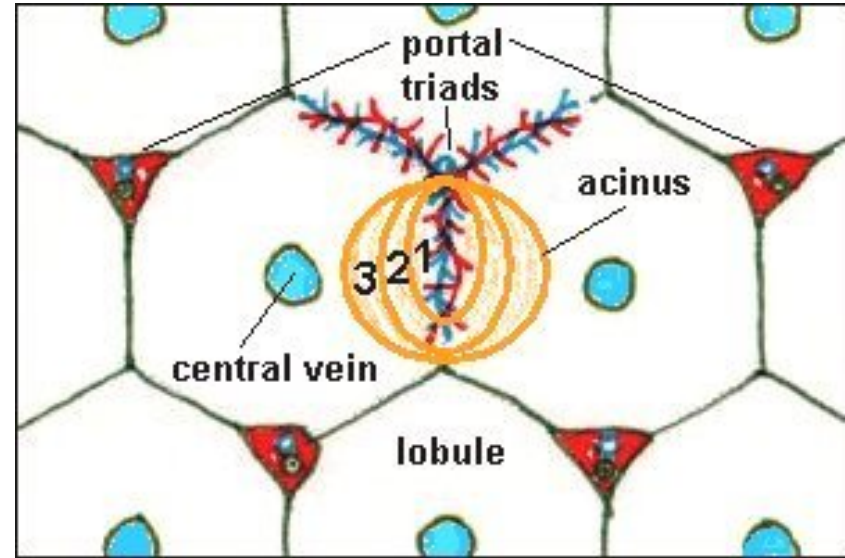
Liver Lobule

Although the precise boundaries of lobules are sometimes difficult to discern, orienting on central veins and portal tracts allow "easy" identification.



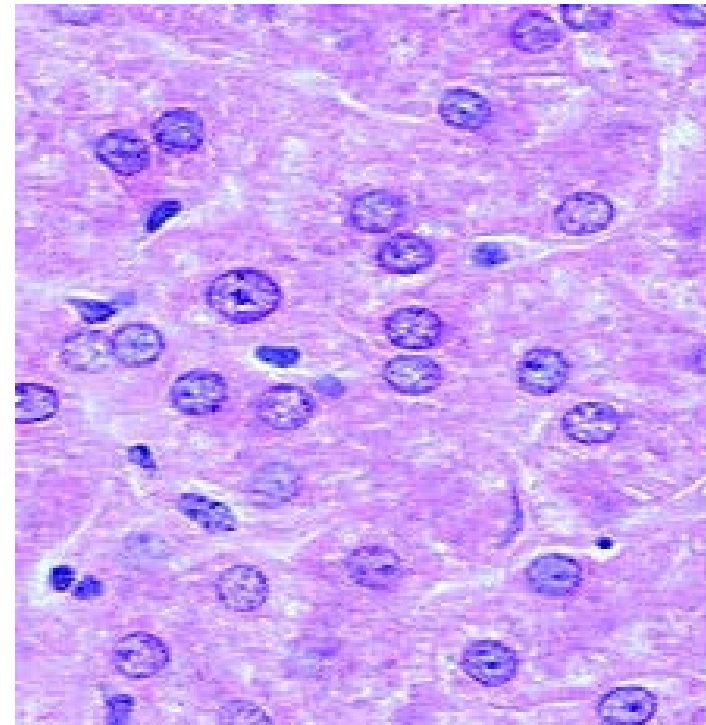
Hepatic Acinus

- **The hepatic acinus is the functional unit of the liver.** The acinus is more difficult to visualize than the lobule, but represents a unit that is of more relevance to hepatic function because it is oriented around the afferent vascular system.
- the acinus consists of an irregular shaped, roughly ellipsoidal mass of hepatocytes aligned around the hepatic arterioles and portal venules just as they anastomose into sinusoids.
- **The acinus is roughly divided into zones that correspond to distance from the arterial blood supply** - those hepatocytes closest to the arterioles (zone 1 below) are the best oxygenated, while those farthest from the arterioles have the poorest supply of oxygen.
- Importantly, the cells in Zone 3 are the most susceptible to ischemic conditions due to the already low level of oxygen that reaches them through the blood.



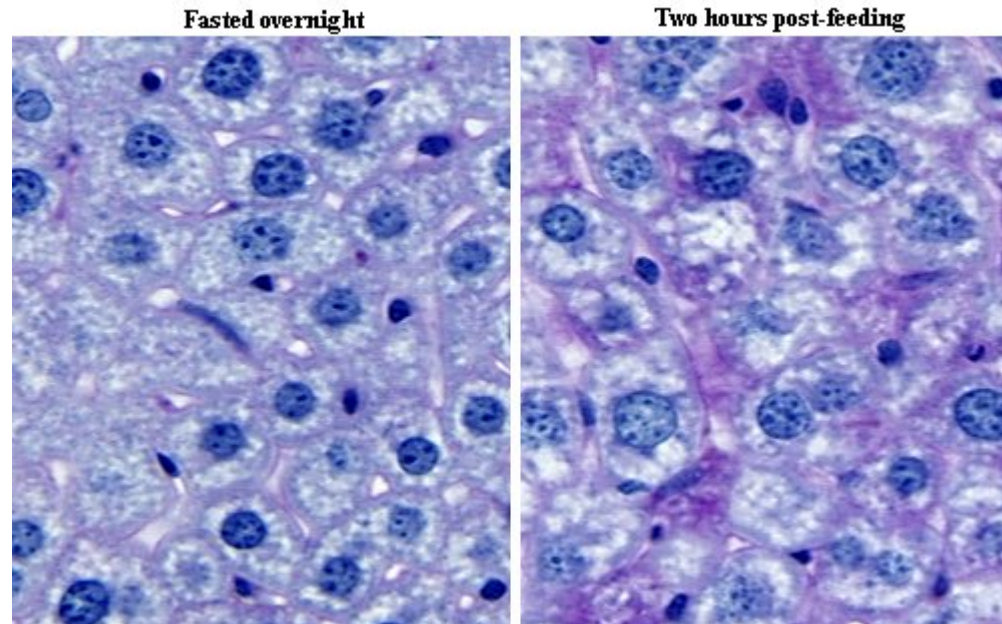
Hepatocyte

- The cells are polygonal in shape and their sides can be in contact either with sinusoids (sinusoidal face) or neighboring hepatocytes (lateral faces). A portion of the lateral faces of hepatocytes is modified to form bile canaliculi. Microvilli are present abundantly on the sinusoidal face and project sparsely into bile canaliculi.
- **Hepatocyte nuclei are distinctly round, with one or two prominent nucleoli.** A majority of cells have a single nucleus, but binucleate cells are common.



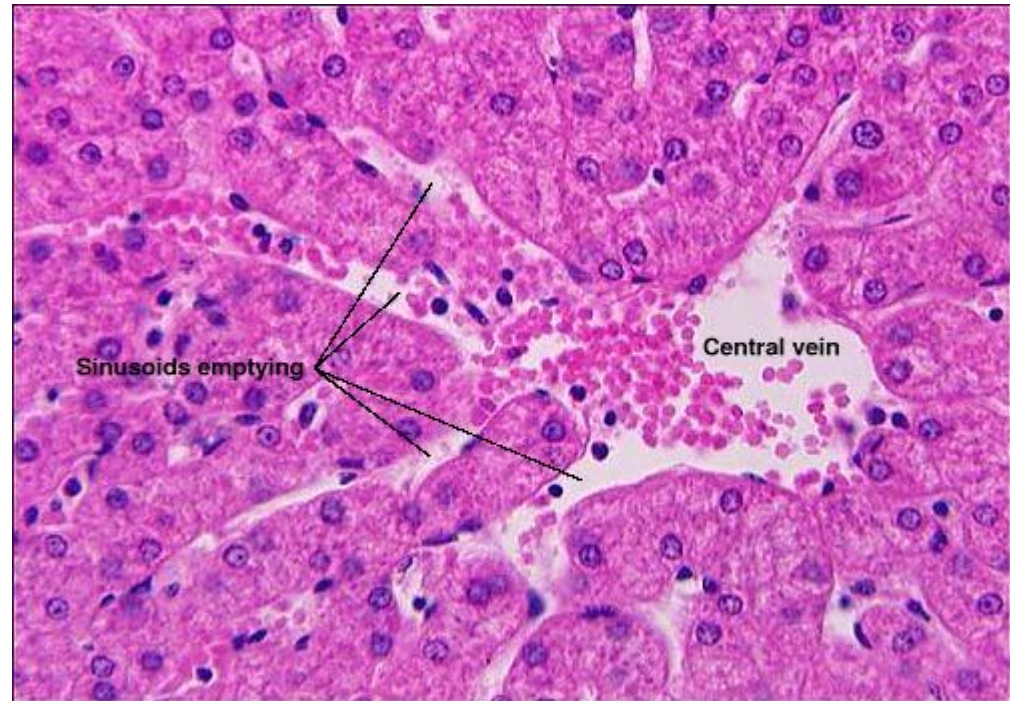
Liver Glycogen

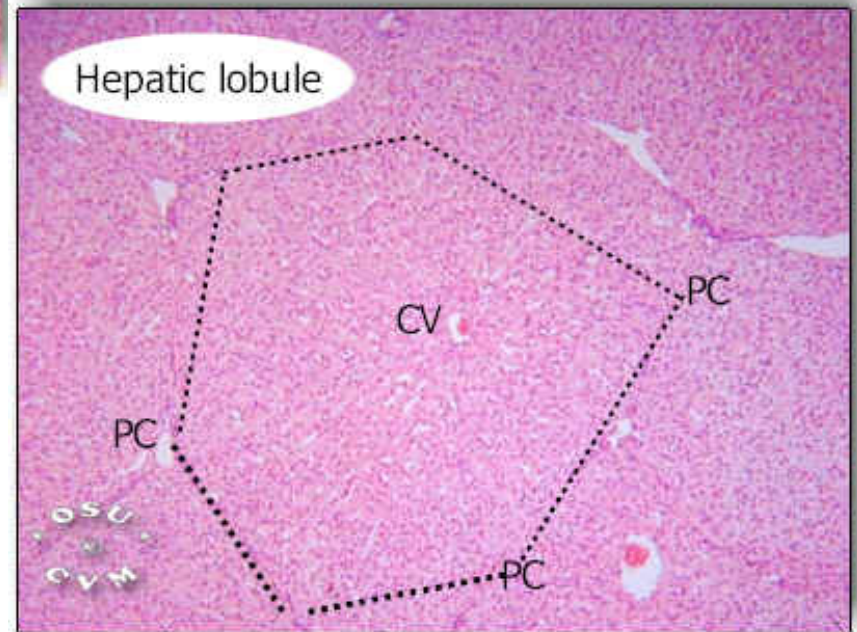
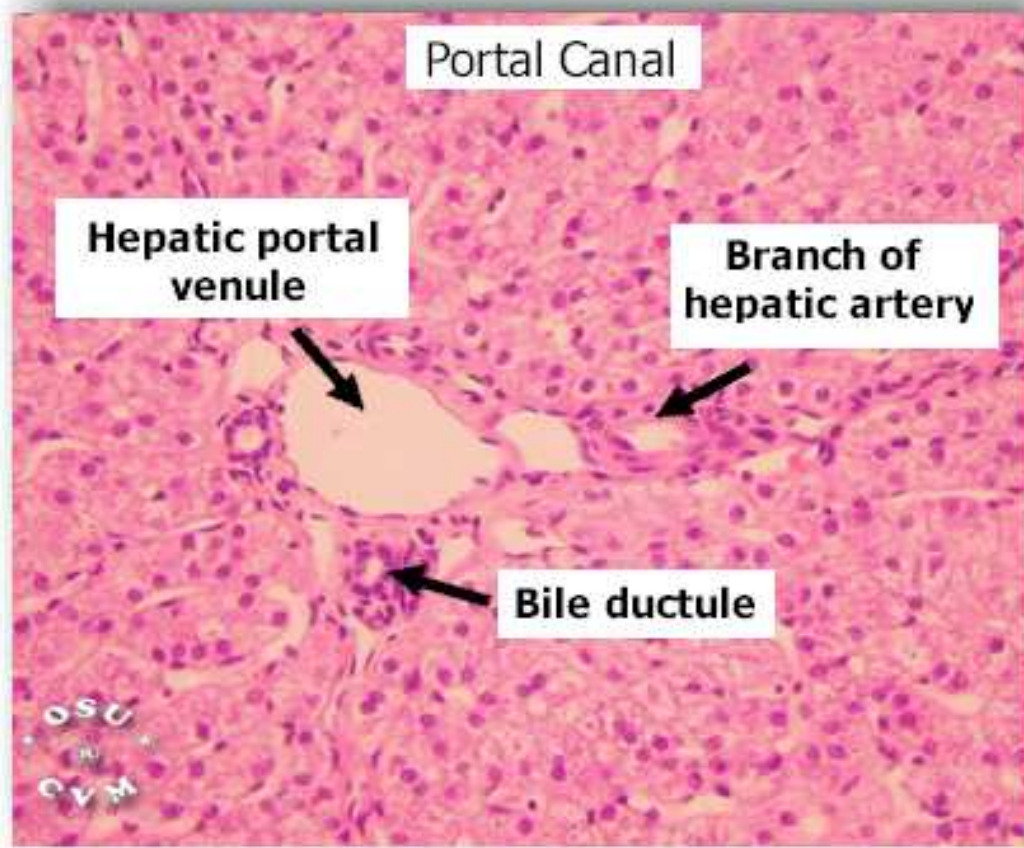
- Particle observed in copious quantities in liver is **glycogen**. Glycogen is a polymer of glucose and the density of glycogen aggregates in hepatocytes varies dramatically depending on whether the liver is examined shortly after a meal (abundant glycogen) or following a prolonged fast (minimal quantities of glycogen).
- In paraffin sections of liver stained with hematoxylin and eosin, accumulations of glycogen in hepatocytes do not stand out. However, when stained with using the periodic acid-Schiff (PAS) technique, **glycogen stains bright pink in color**. The images below represent PAS-stained sections of liver from two mice:
 - **Left panel:** from a mouse that fasted overnight and thus had very low levels of glycogen in liver.
 - **Right panel:** from mouse that stuffed himself on mouse chow two hours prior to fixing the liver, and thus had high levels of hepatic glycogen. These accumulations are seen as pink areas of PAS-positive material throughout the section.



Liver Sinusoids

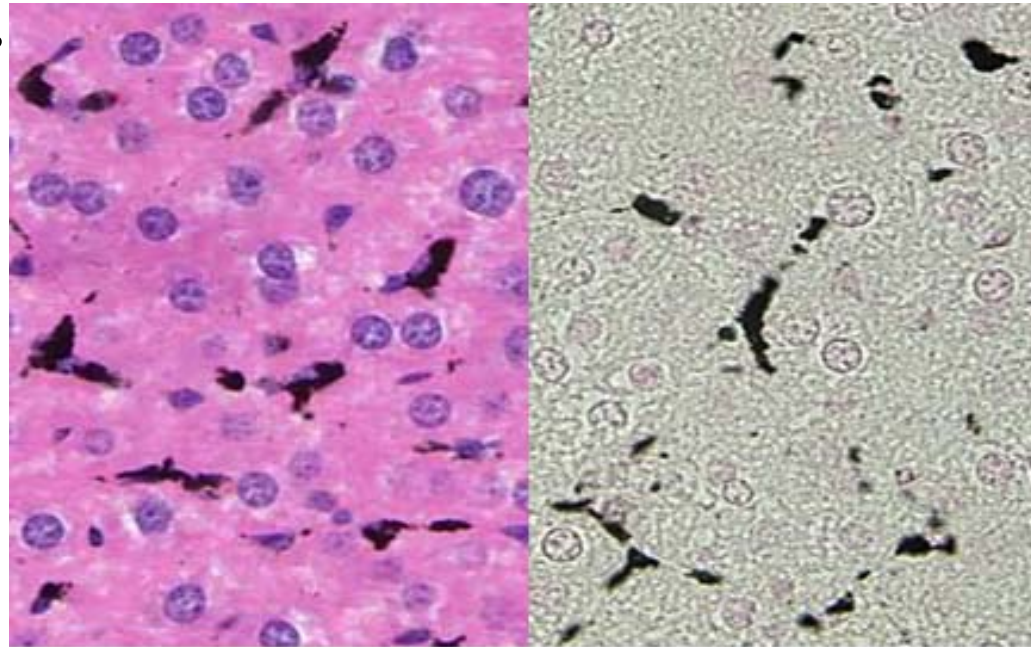
- **Sinusoids are low pressure vascular channels that receive blood from terminal branches of the hepatic artery and portal vein at the periphery of lobules and deliver it into central veins.** Sinusoids are lined with endothelial cells and flanked by plates of hepatocytes.
- **The space between sinusoidal endothelium and hepatocytes is called the space of Disse.** Sinusoidal endothelial cells are highly fenestrated, which allows virtually unimpeded flow of plasma from sinusoidal blood into the space of Disse. This arrangement has at least two important consequences:
 - Hepatocytes are bathed in plasma derived in large part from venous blood returning from the small intestine. Following meals, that plasma is nutrient-rich.
 - Plasma which collects in the space of Disse flows back toward the portal tracts, collecting in lymphatic vessels and forming a large fraction of the body's lymph.





Liver Kupffer Cells

- Another important feature of hepatic sinusoids is that they house an important part of the phagocytic system.
- Sinusoids are populated by numerous **Kupffer cells**, a type of fixed macrophage.
- Identifying Kupffer cells in conventionally-stained sections of liver is not easy. However, they stand out sharply when full of phagocytosed ink particles.
- The images below are of a mouse liver fixed two hours after an intravenous injection of a small quantity of India ink, which provides a clear view of these tiny warriors. All of the black masses are ink-laden Kupffer cells lying in sinusoids.

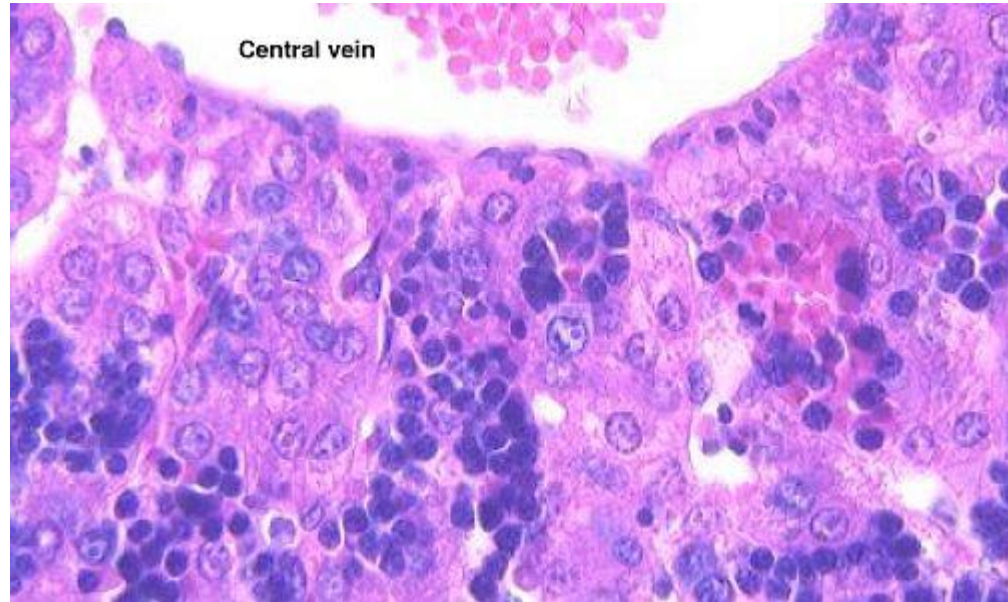


Standard H&E

Light H&E

Liver Hematopoiesis

- The clusters of cells in sinusoids are various types of immature blood cells.
- **In the fetus, the liver is a major site of hematopoiesis, or formation of blood cells.**
- Hepatic hematopoiesis is not normally seen after birth, although it can occur under certain pathologic conditions.



Metabolic Functions of the Liver

the major metabolic functions of the liver can be summarized into several major categories:

- **Carbohydrate Metabolism**
 - Maintenance of normal blood glucose levels over both short (hours) and long (days to weeks) periods of time is one particularly important function of the liver.
- **Fat Metabolism**
- **Protein Metabolism**

Metabolic Functions of the Liver

Carbohydrate Metabolism

- Maintenance of normal blood glucose levels over both short (hours) and long (days to weeks) periods of time is one particularly important function of the liver.
 - Excess glucose entering the blood after a meal is rapidly taken up by the liver and sequestered as the large polymer, glycogen (a process called **glycogenesis**).
 - Later, when blood concentrations of glucose begin to decline, the liver activates other pathways which lead to depolymerization of glycogen (**glycogenolysis**) and export of glucose back into the blood for transport to all other tissues.
 - When hepatic glycogen reserves become exhausted, as occurs when an animal has not eaten for several hours, enzymes are activated that begin synthesizing glucose out of such things as amino acids and non-hexose carbohydrates (**gluconeogenesis**).

Metabolic Functions of the Liver

Fat Metabolism

- **Major examples of the role of the liver in fat metabolism include:**
 - The liver is extremely active in **oxidizing triglycerides to produce energy**
 - A bulk of the **lipoproteins are synthesized** in the liver.
 - is the major site for **converting excess carbohydrates and proteins into fatty acids and triglyceride**, which are **then exported and stored in adipose tissue.**
 - **synthesizes** large quantities of **cholesterol and phospholipids.**

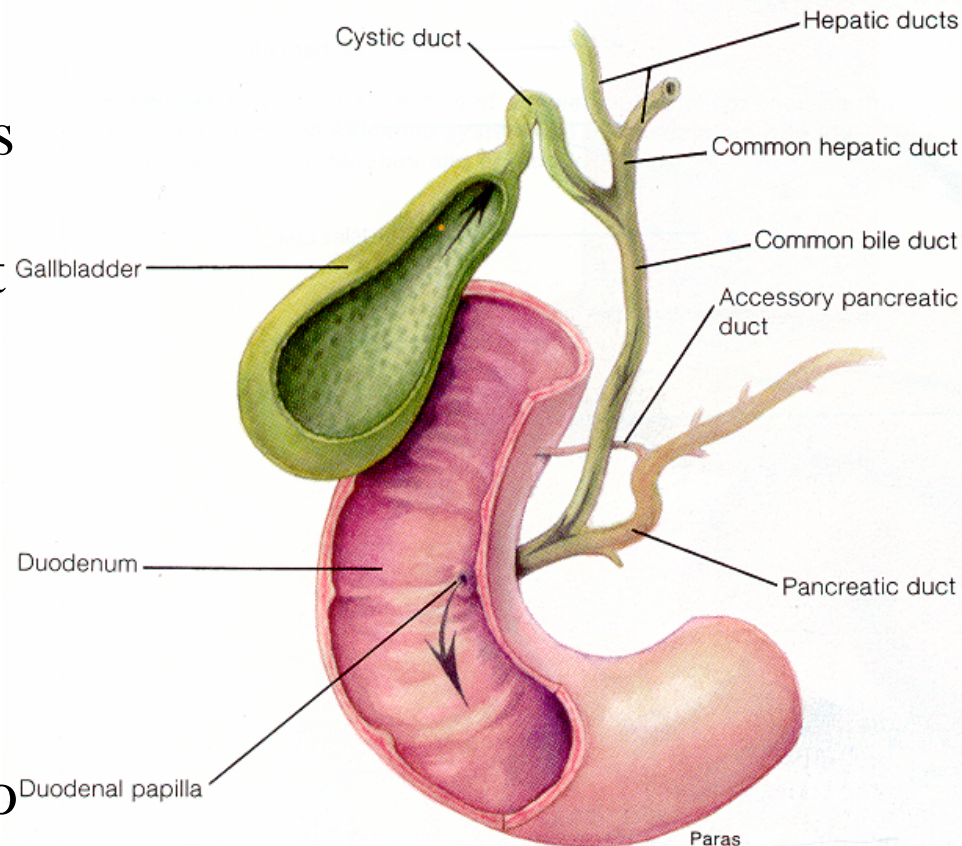
Metabolic Functions of the Liver

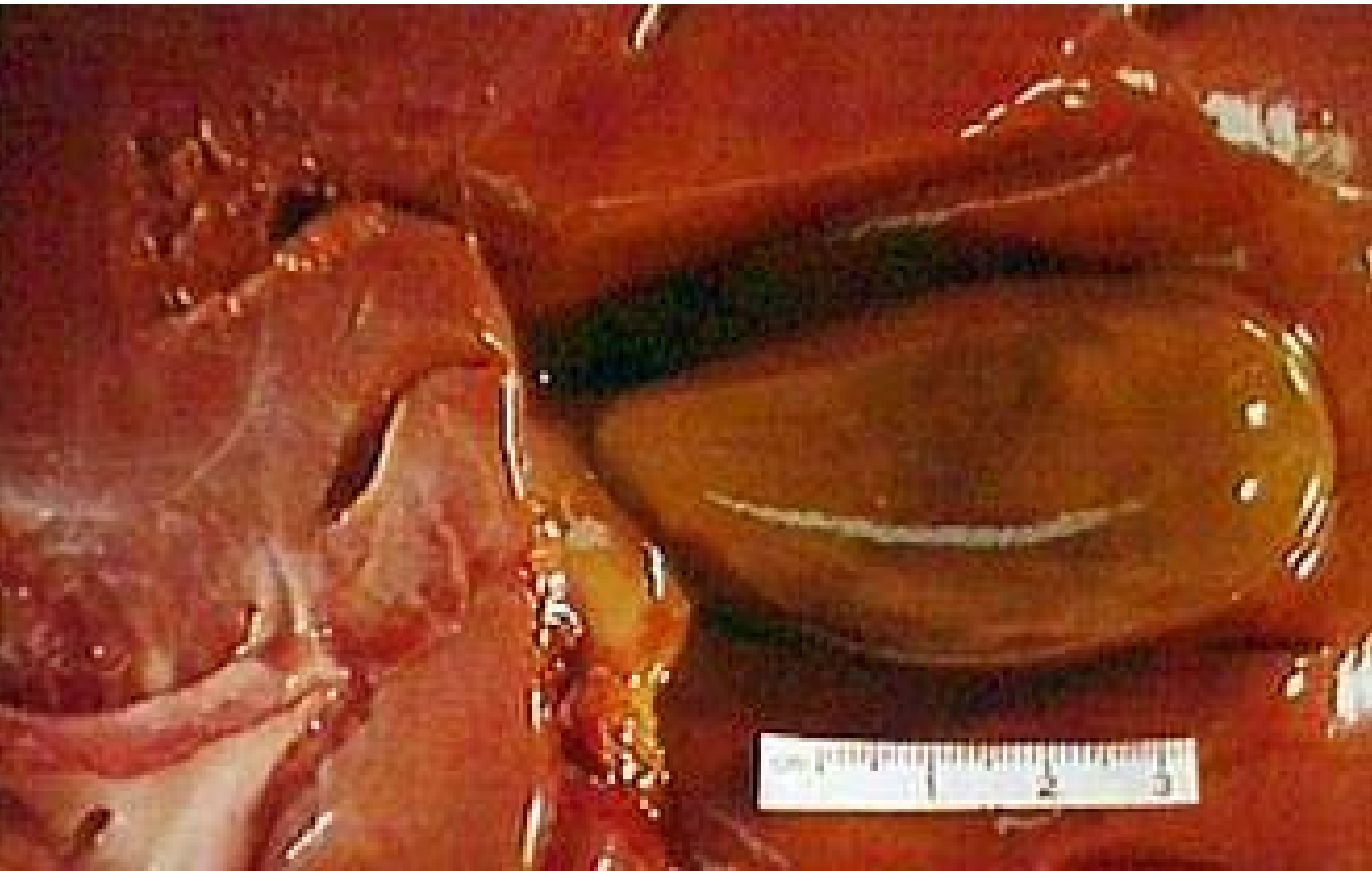Protein Metabolism


- The most critical aspects of protein metabolism that occur in the liver are:
 - Deamination and transamination of amino acids, followed by conversion of the non-nitrogenous part of those molecules to glucose or lipids.
 - Removal of ammonia from the body by synthesis of urea.
 - Ammonia is very toxic and if not rapidly and efficiently removed from the circulation, will result in central nervous system disease.
 - Synthesis of non-essential amino acids.
 - synthesis of most of the plasma proteins
 - Albumin, the major plasma protein, is synthesized almost exclusively by the liver. Also, the liver synthesizes many of the clotting factors necessary for blood coagulation.

Gallbladder

- a thin-walled, green, muscular sac, the size of a kiwi fruit located within a shallow fossa on the ventral surface of the liver and it's covered by visceral peritoneum.
- It **stores bile and concentrates it** by absorbing water and ions.
- When its muscular wall contracts bile is expelled into the cystic duct, common bile duct, and duodenum.
- In the absence of lipid intake, the hepatopancreatic sphincter is closed tight and bile backs up into the common bile duct, cystic duct and into the gallbladder itself.



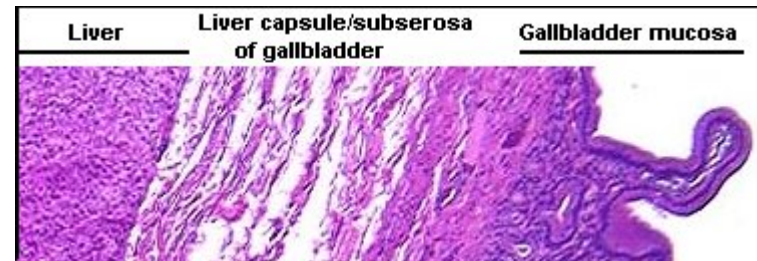
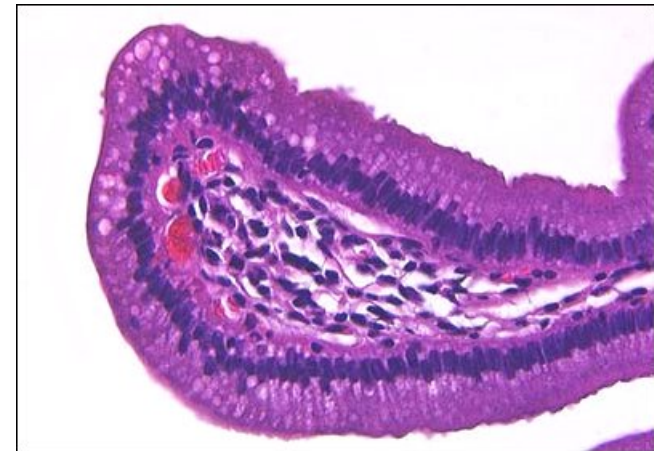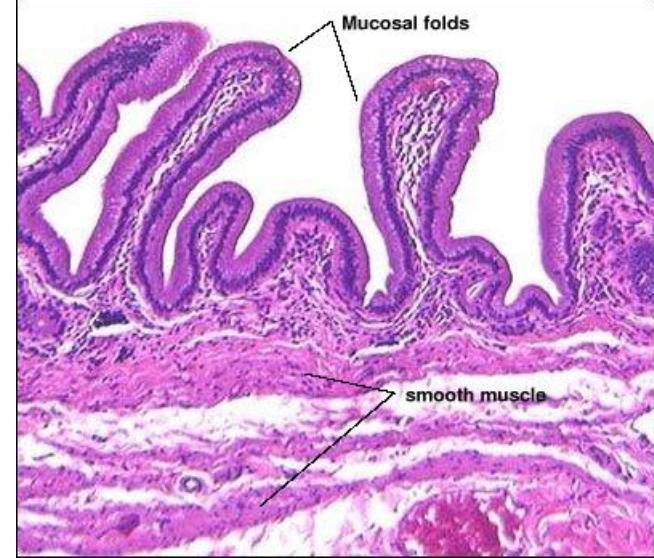




© Cornell University Medical College

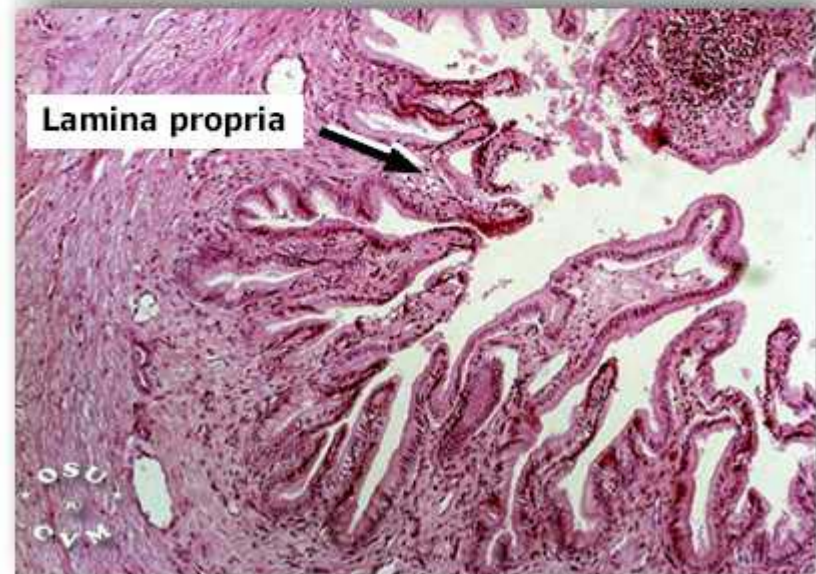
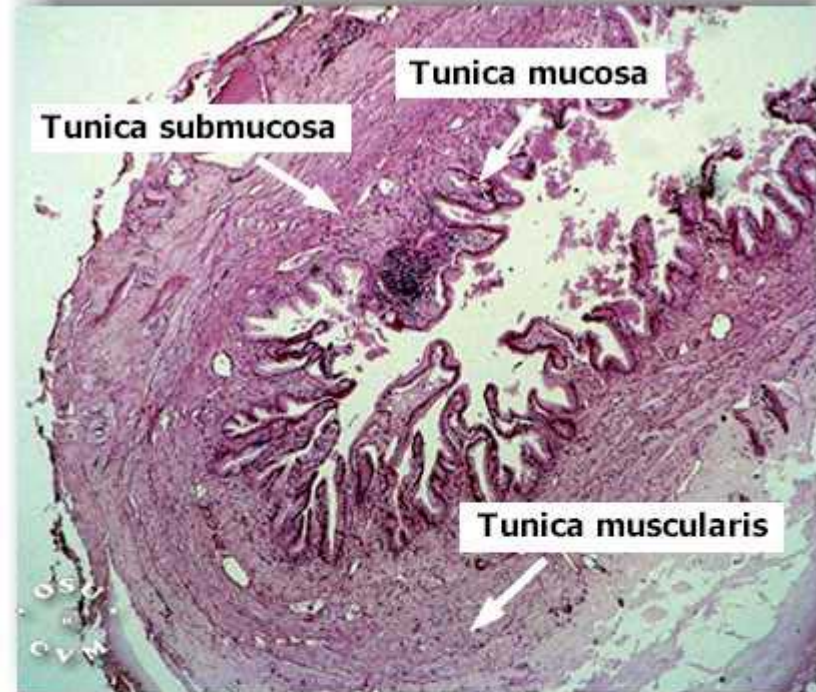
Gallbladder

- **When not distended, its mucosa is thrown into many folds.** The lumen of the gallbladder is lined with a **high columnar epithelium**.
- The connective tissue wall contains abundant elastic fibers and layers of smooth muscle which predominantly run obliquely.
- These epithelial cells are devoted to absorption of inorganic salts and water, and provide the mechanism for the gallbladder's ability to concentrate bile.
- Between the smooth muscle layers and serosa is a thick subserosal layer of connective tissue. One face of the gallbladder is attached to the liver, and in that area, the connective tissue of the two organs is shared.



Tunics (layers) of the Gall Bladder

- When the gall bladder is empty, this layer is extremely folded. When full, this layer is smoother but still has some short folds.
- **lamina epithelialis:** composed of simple columnar epithelial cells with numerous microvilli on their luminal surfaces and connected by tight junctions near luminal surfaces.
- **lamina propria:** composed of loose connective tissue rich in reticular and elastic fibers to support the large shape changes that occur in the lamina epithelialis
- **lamina muscularis mucosae:** not present
- **Tunica submucosa:** present and typical
- **Tunica muscularis:** contains much smooth muscle, poorly organized
- **Tunica serosa:** present and typical

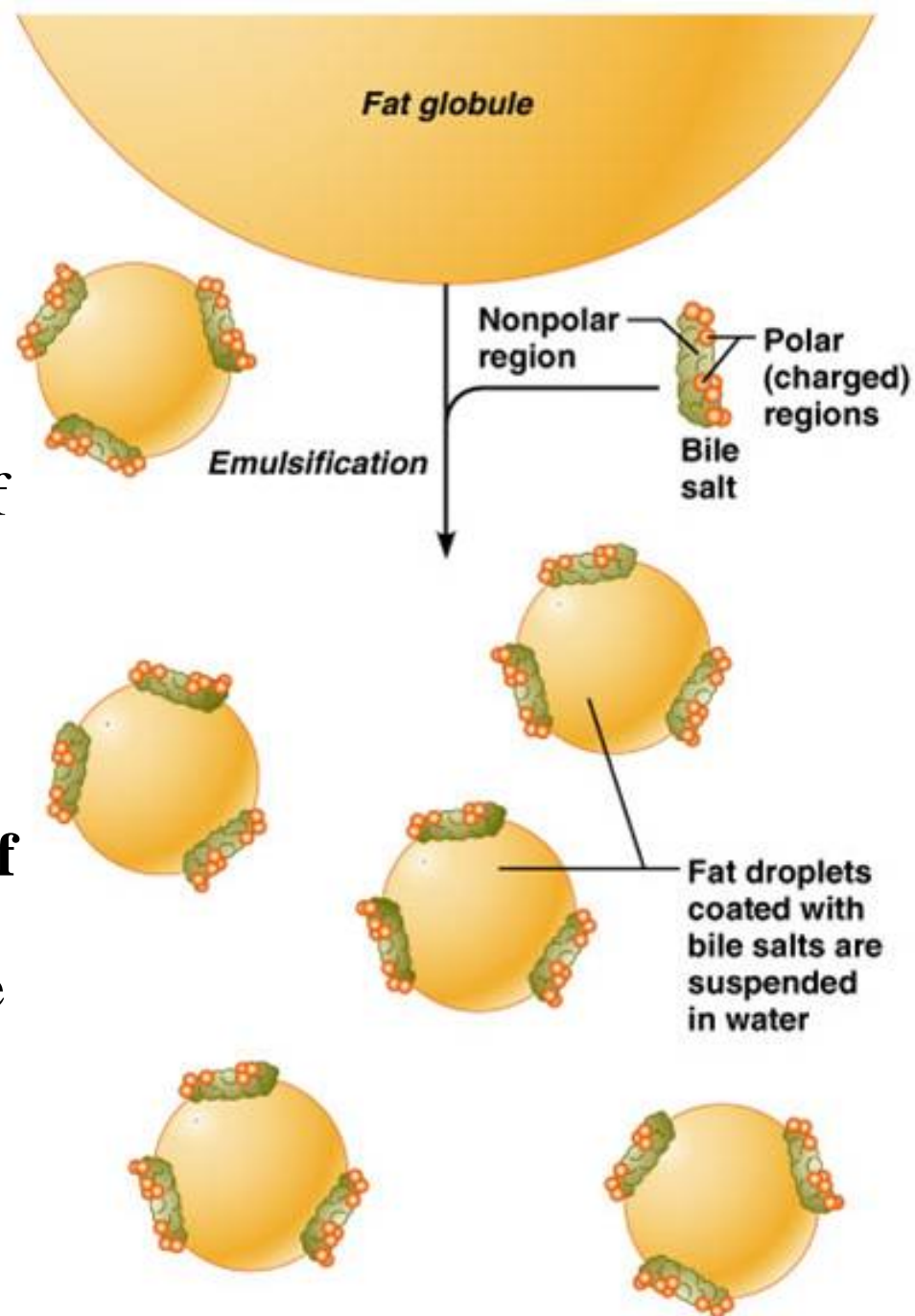


Bile

- Bile is a yellow-green, **alkaline solution** containing **bile salts, bile pigments, cholesterol, neutral fats, phospholipids, and electrolytes.**
- The chief bile pigment is **bilirubin** (a breakdown product of red blood cells)
- Bile is made almost continuously by the liver and is stored and modified within the gallbladder
- There are two fundamentally important functions of bile in all species:
 - **Many waste products are eliminated from the body by secretion into bile and elimination in feces.**
 - **Bile contains bile acids, which are critical for digestion and absorption of fats and fat-soluble vitamins in the small intestine.**

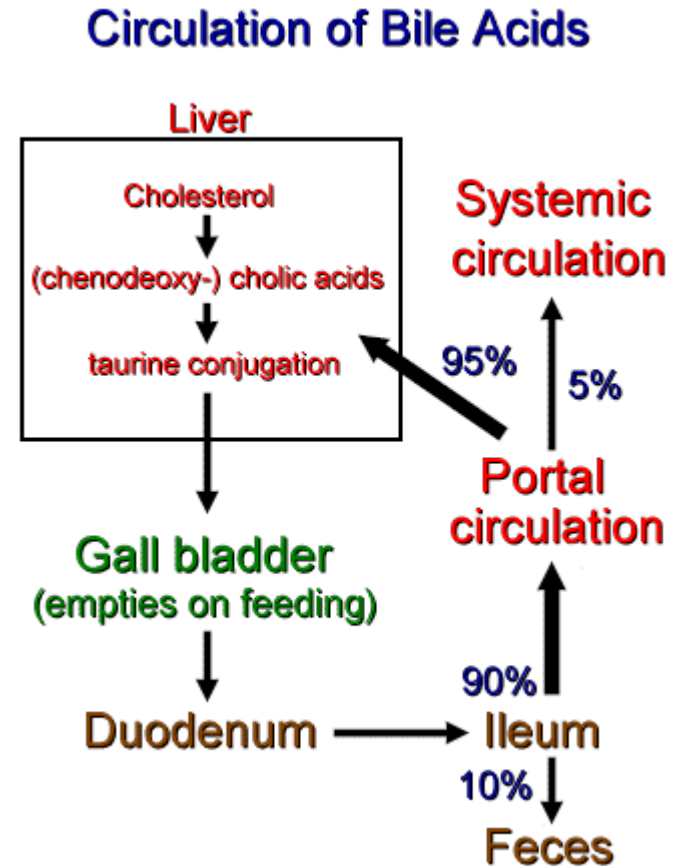
Bile & the Emulsification of Fat

- Due to their hydrophobic nature, ingested fats tend to clump together in the watery environs of the digestive tract.
- This decreases the surface area available to lipases - fat digesting enzymes.
- **Bile salts separate the clumps of fat into smaller pieces (this is emulsification)** and thus increase the surface area available to digestive enzymes.



Enterohepatic Recirculation of Bile

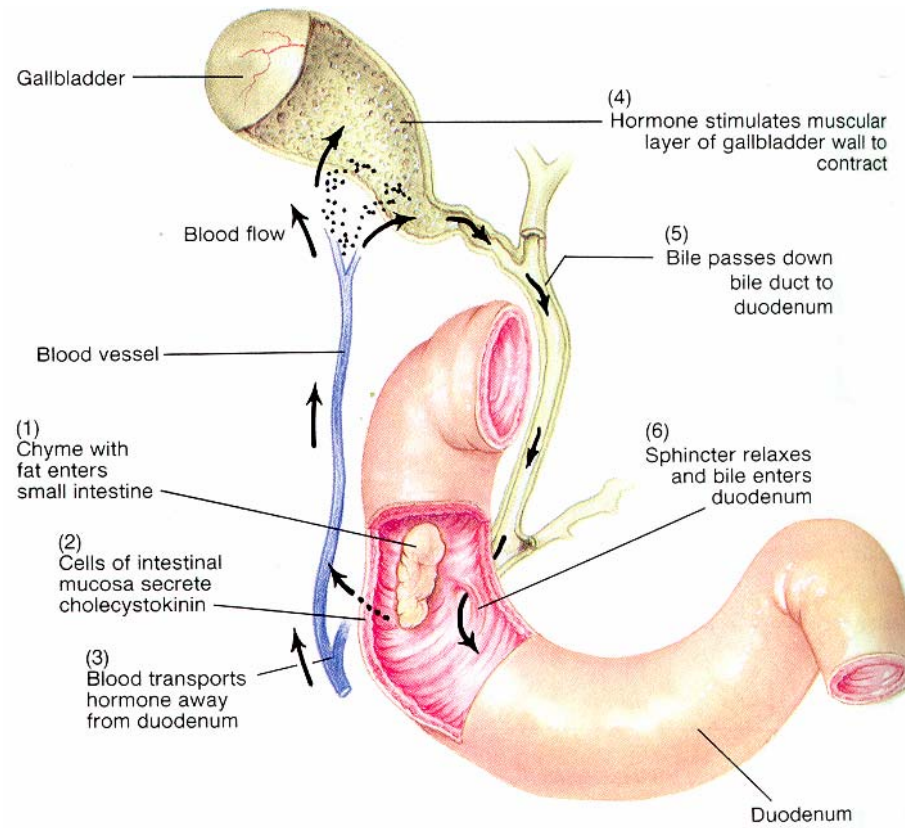
- Large amounts of bile acids are secreted into the intestine every day, but only relatively small quantities are lost from the body.
- This is because approximately 95% of the bile acids delivered to the duodenum are absorbed back into blood within the ileum.
- The remaining five percent is excreted in the feces.



Gallbladder

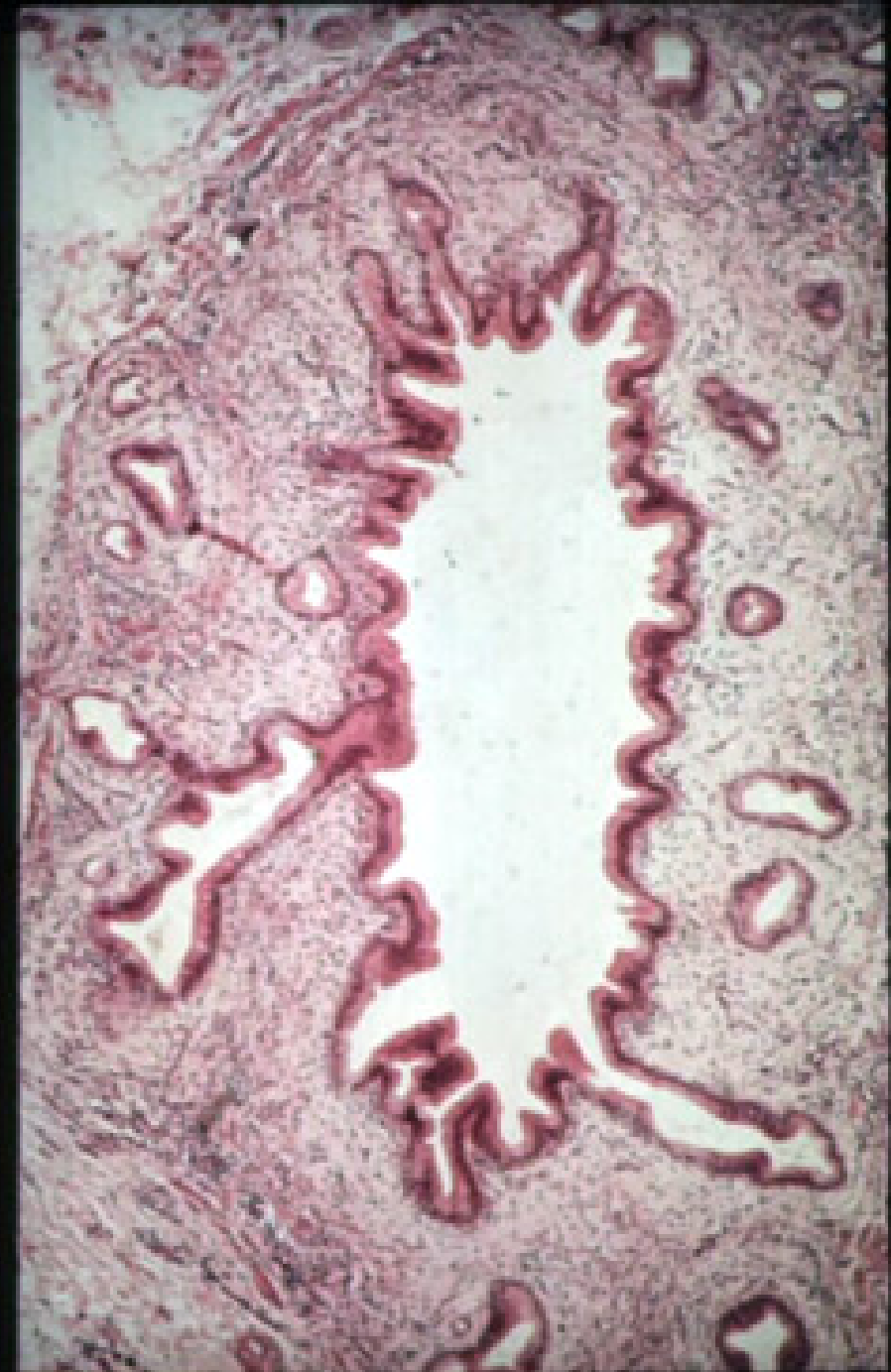Emptying of the Gallbladder

- When triglycerides enter the small intestine, **cholecystokinin** is released to stimulate contractions of the gallbladder, which releases bile into the common bile duct and on into the small intestine.



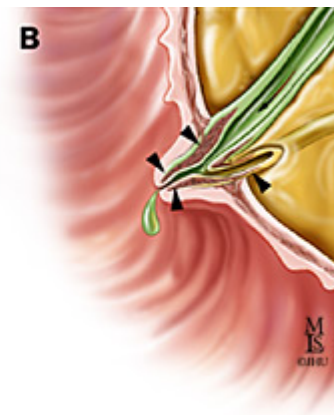
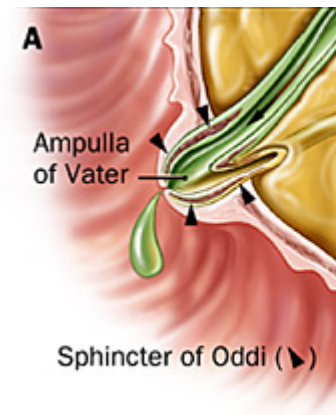
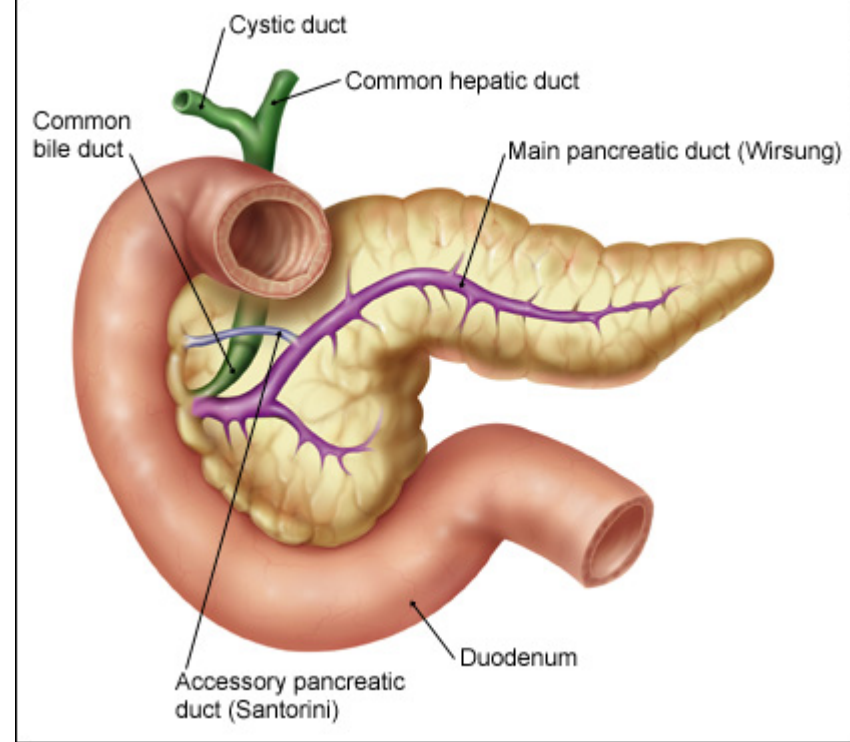
- **Bile Duct**

- **The epithelium is tall columnar, may secrete mucous, lies in an elastic connective tissue layer surrounded by scanty smooth muscle cells.**



Pancreas

- The pancreas is an elongated organ, light tan or pinkish in color, that lies in close proximity to the duodenum.
- The majority is retroperitoneal.
- It is covered with a very thin connective tissue capsule which extends inward as septa, partitioning the gland into lobules.
- the major pancreatic duct merges with the common bile duct to form a swelling in the duodenal wall called the **ampulla (of Vater)**.
- The muscular wall of the ampulla may be thickened, forming the **sphincter of Oddi**.



Pancreas: Parts and relations

- **Head**

- lies within the curve of the duodenum
- uncinete process is a prolongation of the head. The superior mesenteric artery and vein crosses this process.

- **uncinate process**

- the part of the head that wraps behind the superior mesenteric artery and vein and comes to lie adjacent to the ascending part of the duodenum.

- **Neck**

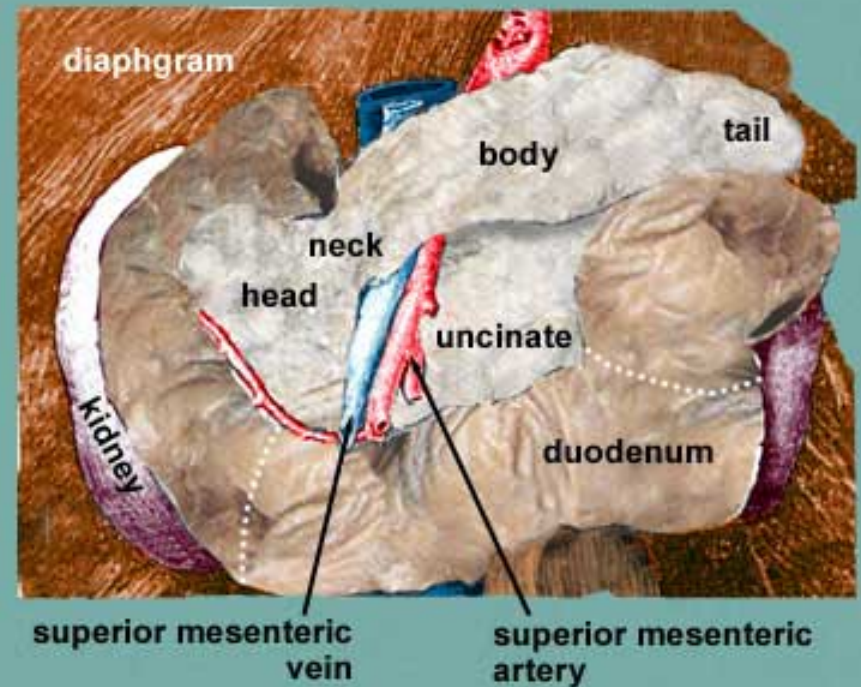
- a constricted portion to the left of the head. It abuts the pylorus above and the beginning of the portal vein behind.

- **Body**

- anterior surface separated from the stomach by the omental bursa
- posteriorly related to the aorta, splenic vein, left kidney and renal vessels, left suprarenal, origin of superior mesenteric artery and crura of diaphragm.

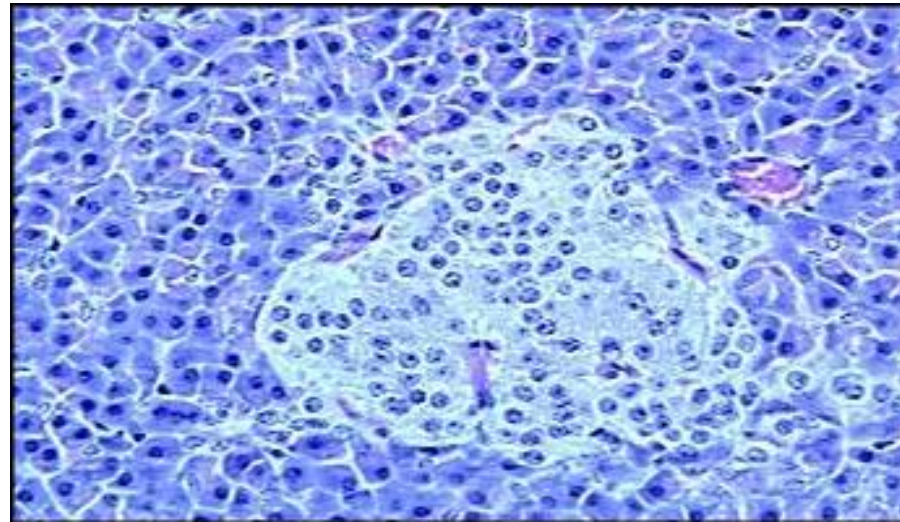
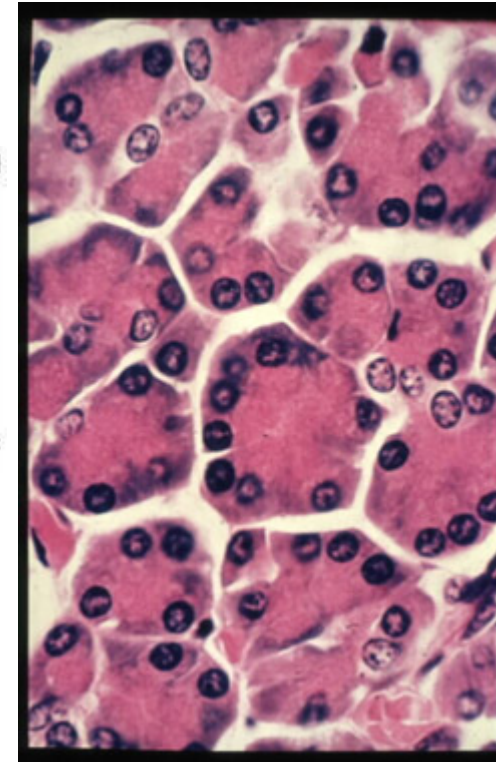
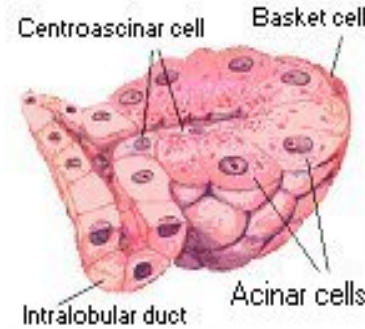
- **Tail**

- extends into the lienorenal ligament and abuts the spleen.



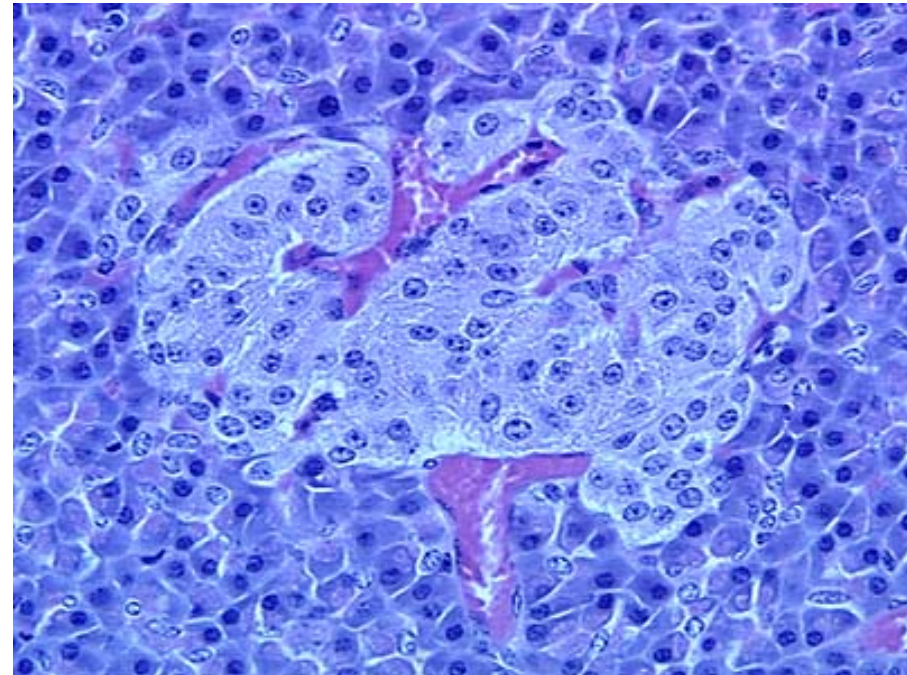
Pancreas

- The bulk of the pancreas is composed of pancreatic exocrine cells forming **acini** and their associated ducts.
- Embedded within this exocrine tissue are roughly one million small clusters of cells called the **Islets of Langerhans**, which are the endocrine cells of the pancreas and secrete insulin, glucagon and several other hormones.
- **Insulin** is released by beta cells in response to high plasma [glucose] and acts to decrease plasma [glucose].
- **Glucagon** is released by alpha cells in response to low plasma [glucose] and acts to raise plasma [glucose].

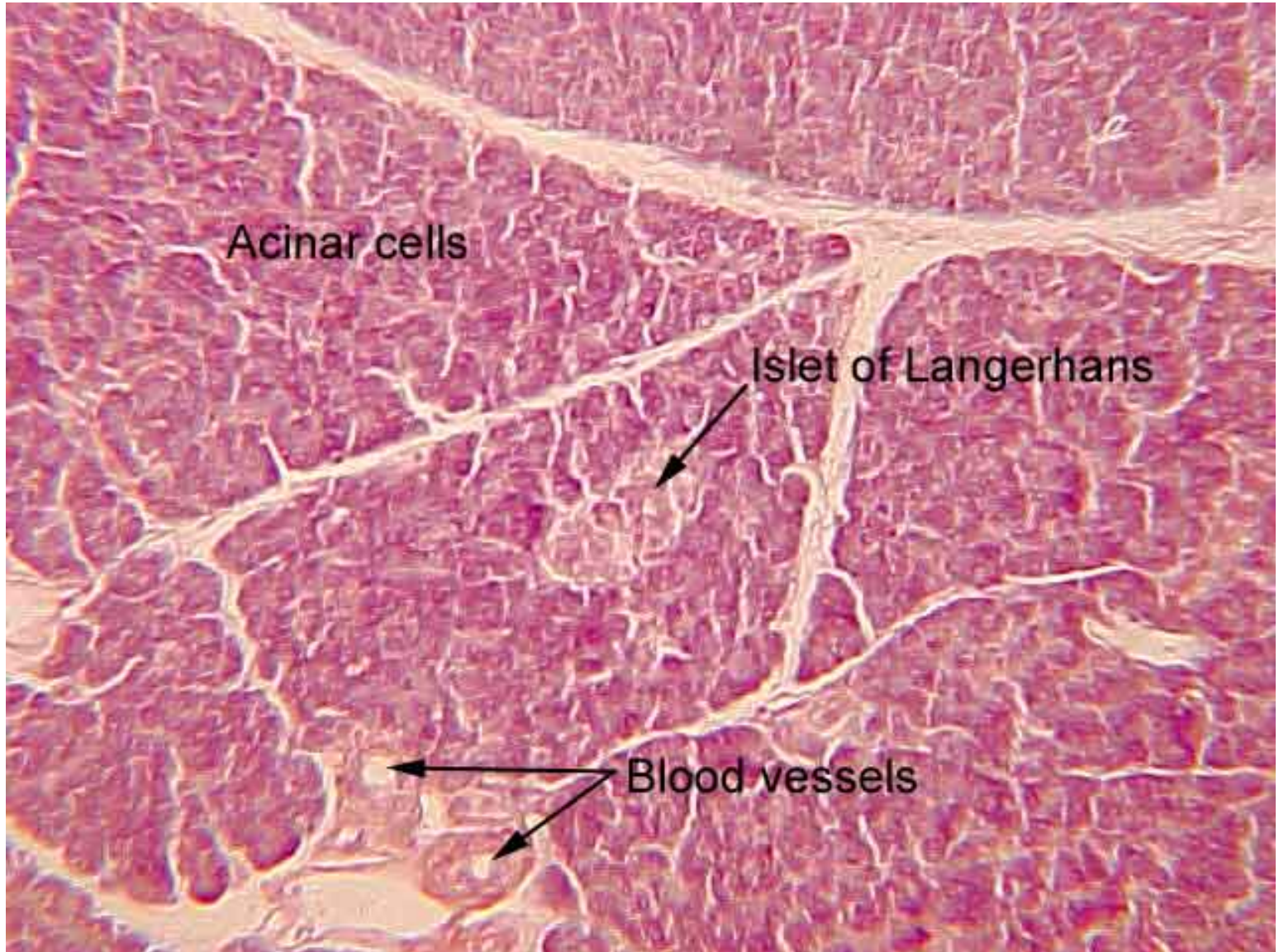


Pancreas

- **Islets contain several different endocrine cell types.** The most abundant are **beta cells**, which produce **insulin**, and **alpha cells**, which secrete **glucagon**.
 - In sections stained with H&E, **the different endocrine cell types cannot be differentiated from one another.** Special stains, or better yet, immunostaining, is required to identify specific cell types.
- The endocrine cells within islets are arranged as irregular cords around abundant capillaries, which receive the secreted hormones for delivery into the systemic circulation.
 - Examine the images of islets below and note their rich vascularity, evidenced by clusters and streams of red blood cells next to endothelial cells that can be identified by their flattened nuclei.

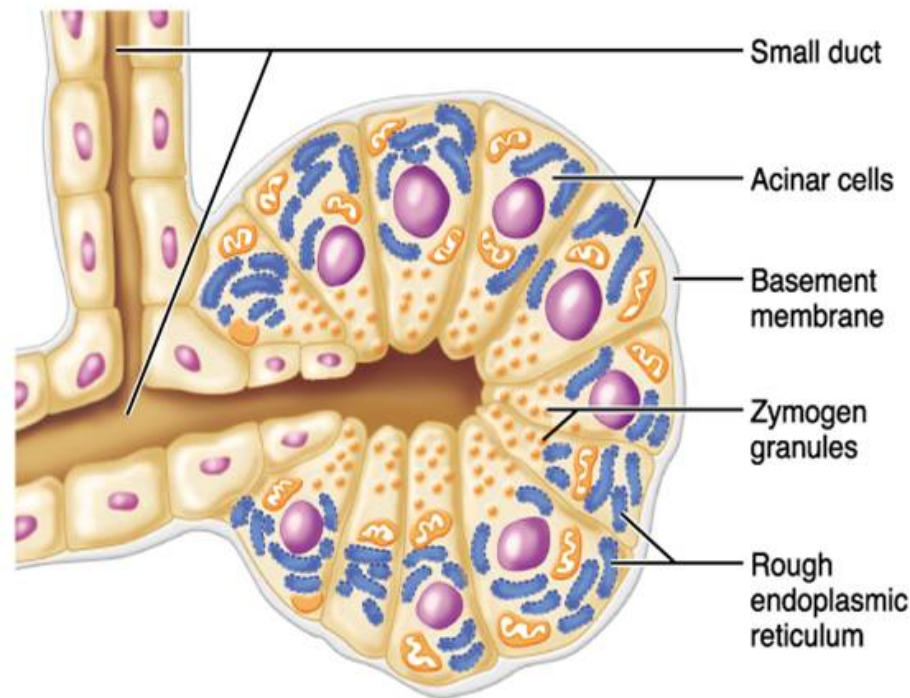


Pancreas



Pancreas

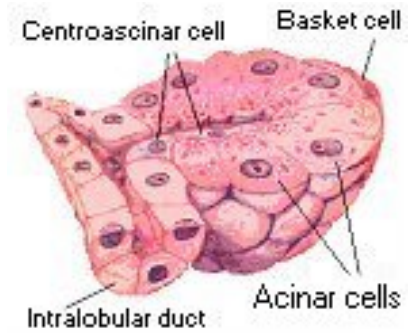
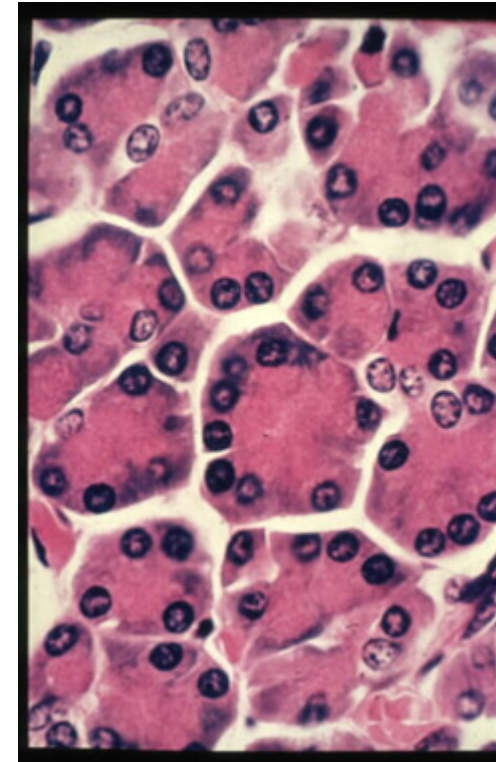
- Acini are arranged in grape-like clusters
- The exocrine cells themselves are packed with membrane-bound secretory granules which contain digestive enzymes that are exocytosed into the lumen of the acinus.
- Enzymes secreted by the acinar cells include proteases (e.g., trypsin), pancreatic amylase, lipase, and nuclease.
- Note that many of these enzymes are secreted as zymogens - inactive precursors that'll be activated by brush border enzymes within the duodenum.
- Recall that in response to proteins and fats within chyme, duodenal enteroendocrine cells release CCK. CCK causes pancreatic acinar cells to secrete its enzymes.
- In response to acidic chyme, duodenal enteroendocrine cells secrete the hormone **secretin**.
 - Secretin stimulates the pancreatic duct cells to release their alkaline fluid.
- Vagal stimulation during the cephalic and gastric phases also causes secretion of pancreatic juice.



Pancreas

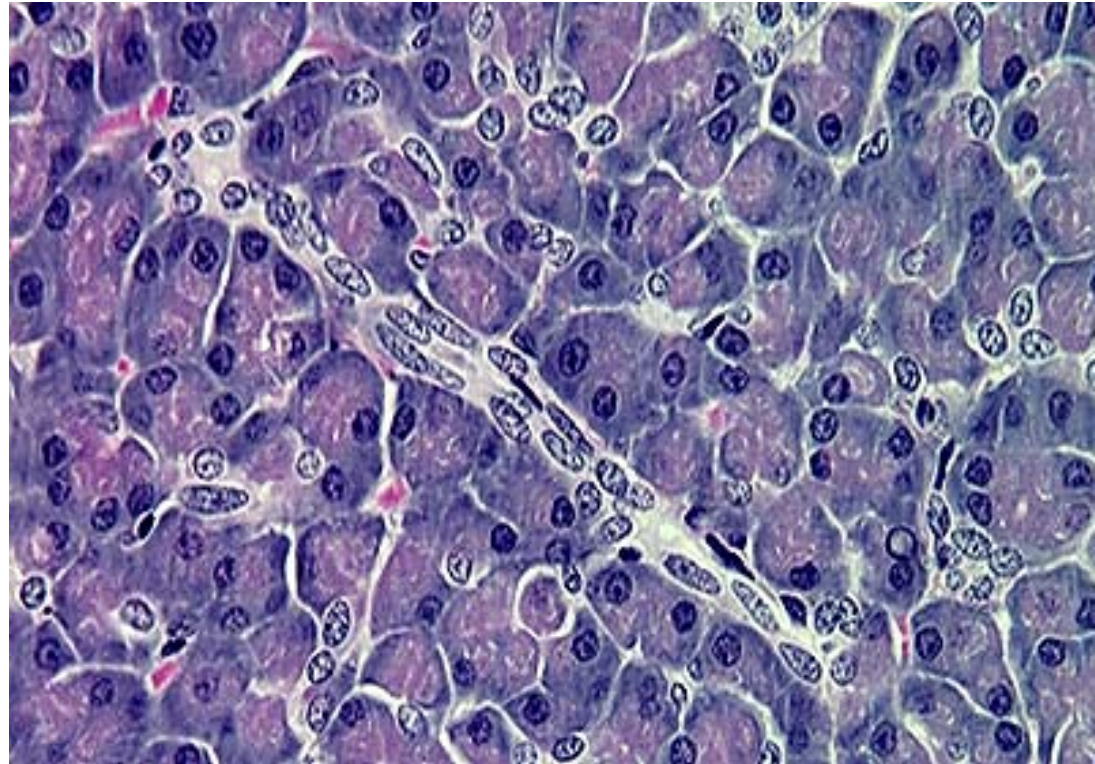
- Pancreatic ducts are classified into four types which are discussed here beginning with the terminal branches which extend into acini.

- **Intercalated ducts** receive secretions from acini. They have flattened cuboidal epithelium that extends up into the lumen of the acinus to form what are called **centroacinar cells**.
- **Intralobular ducts** have a classical cuboidal epithelium and, as the name implies, are seen within lobules. They receive secretions from intercalated ducts.
- **Interlobular ducts** are found between lobules, within the connective tissue septae. They vary considerably in size. The smaller forms have a cuboidal epithelium, while a columnar epithelium lines the larger ducts. Intralobular ducts transmit secretions from intralobular ducts to the major pancreatic duct.
- **The main pancreatic duct** received secretion from interlobular ducts and penetrates through the wall of the duodenum. In some species, including man, the pancreatic duct joins the bile duct prior to entering the intestine.



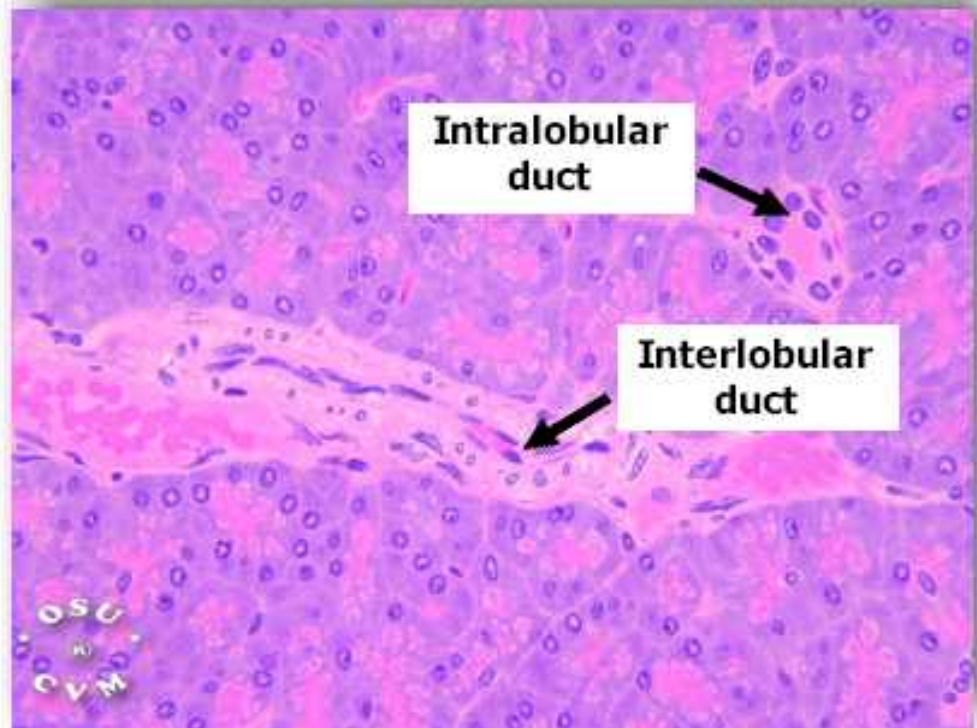
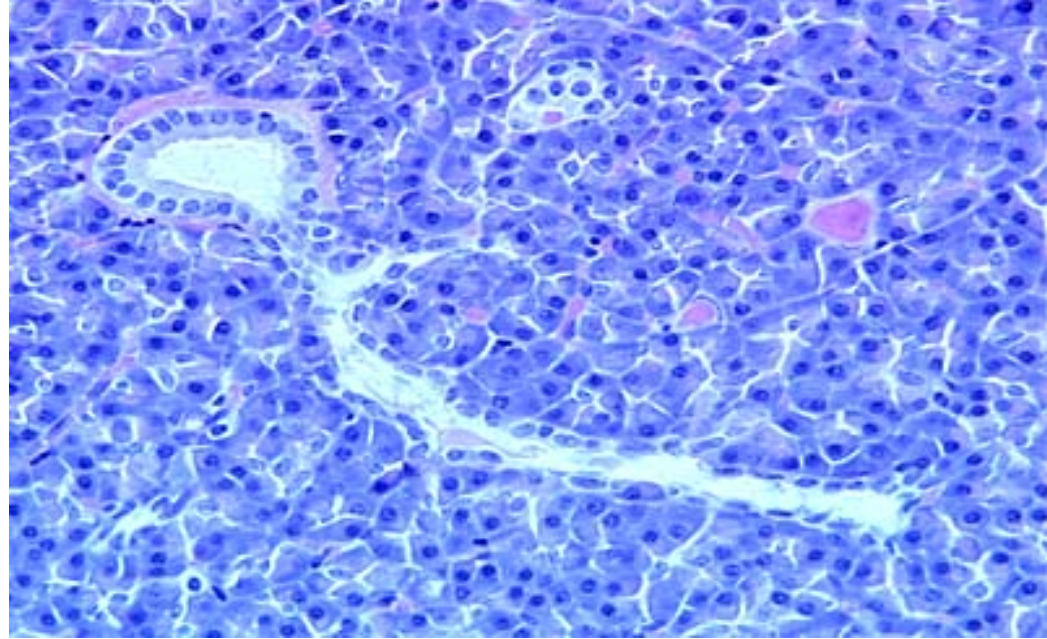
Pancreas

- A longitudinal section through an **intercalated duct** (H&E stain). The duct is running from upper left to lower right. Note the low cuboidal, almost squamous epithelium.



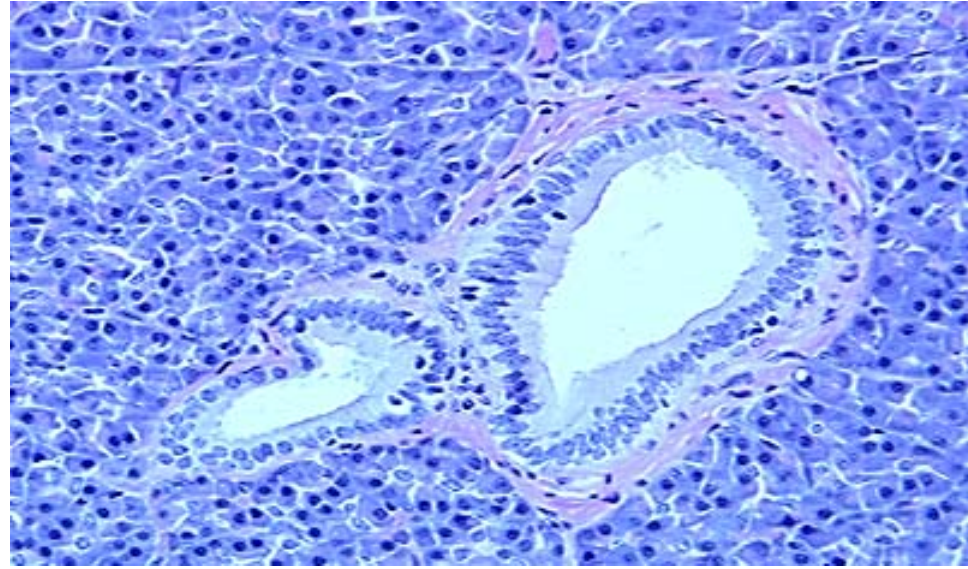
Pancreas

- Section of equine pancreas (H&E stain) showing a longitudinal section through an **intercalated duct** emptying into an **intralobular duct**. Note the **cuboidal epithelium** in the intralobular duct.



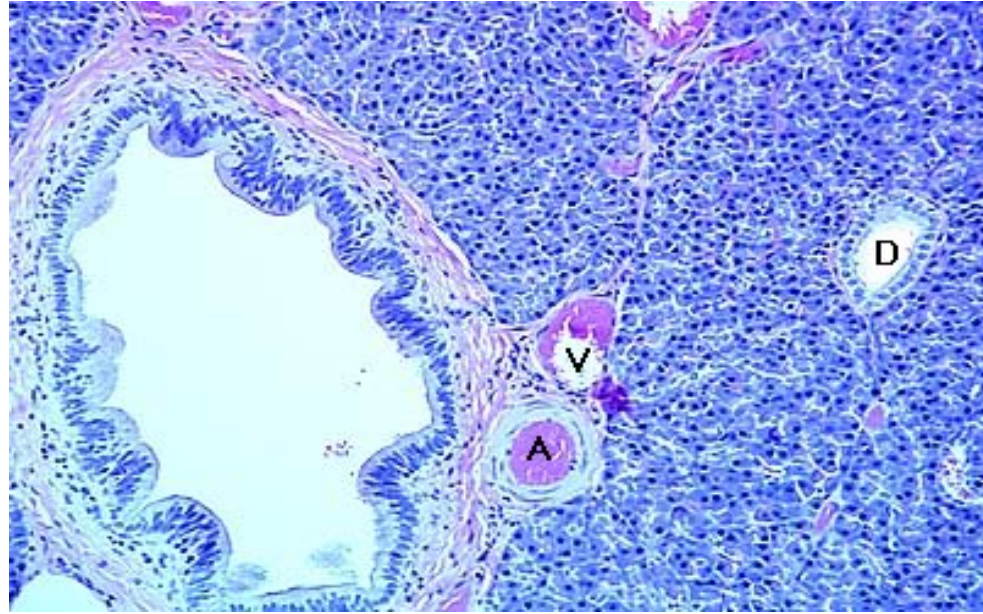
Pancreas

- **Small interlobular ducts** (equine pancreas; H&E stain): note the columnar epithelium. A thin interlobular septum is seen running horizontally immediately above the duct.



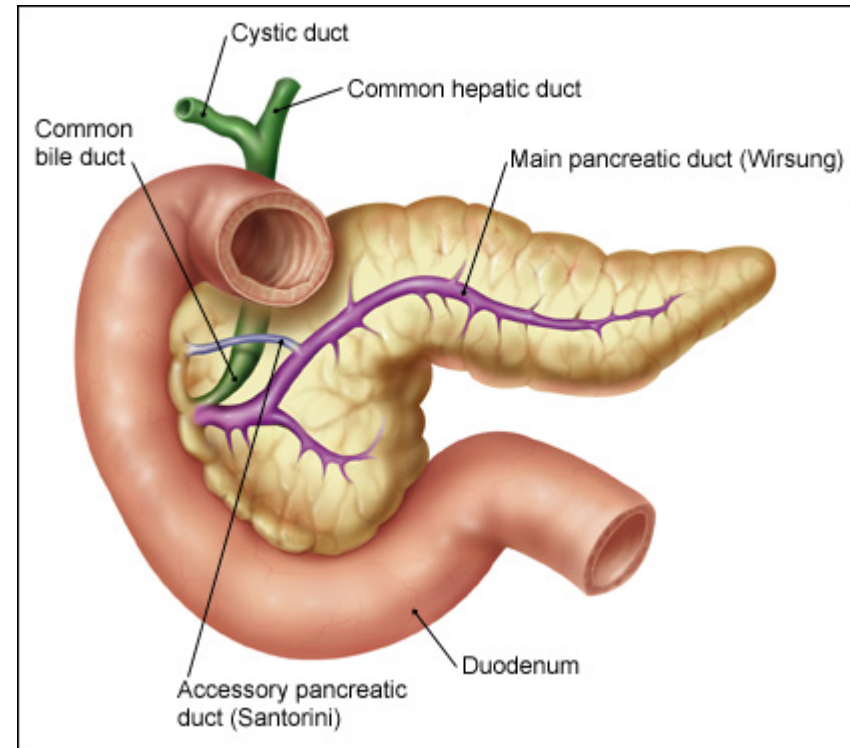
Pancreas

- A low magnification image of equine pancreas (H&E stain) showing a **large interlobular duct** in association with a pancreatic artery (A) and vein (V). An **intralobular duct (D)** is seen on the right side.



Pancreas Duct

- The anatomy of the main pancreatic duct varies among species.
 - In some animals, two ducts enter the duodenum rather than a single duct.
 - **Accessory pancreatic** duct that branches from the main duct and enters the duodenum at the minor duodenal papilla
 - In some species, the main pancreatic duct fuses with the common bile duct just before its entry into the duodenum at the main duodenal papilla



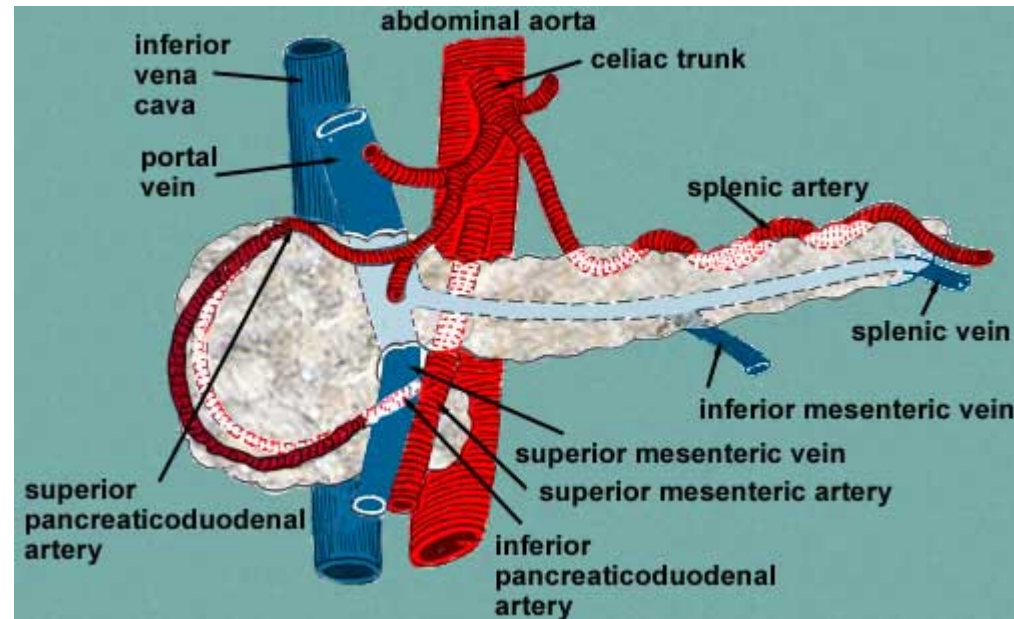
Pancreas: Blood Supply

Arteries

- small branches from the splenic
- superior pancreaticoduodenal - from the gastroduodenal
- inferior pancreaticoduodenal - from the superior mesenteric

Veins

- splenic vein to portal vein
- superior mesenteric vein which then becomes the portal vein



Pancreatic Enzymes

- The pancreas secretes a magnificent battery of enzymes that collectively have the capacity to reduce virtually all digestible macromolecules into forms that are capable of, or nearly capable of being absorbed. Three major groups of enzymes are critical to efficient digestion:
 - **Proteases**
 - **Digestion of proteins is initiated by pepsin in the stomach, but the bulk of protein digestion is due to the pancreatic proteases**
 - The two major pancreatic proteases are **trypsin** and **chymotrypsin**, which are synthesized and packaged into secretory vesicles as inactive **proenzymes trypsinogen and chymotrypsinogen**.
 - Trypsinogen is activated by the intestinal enzyme enterokinase, which is embedded in the intestinal mucosa.
 - Once trypsin is formed it activates chymotrypsinogen, as well as additional molecules of trypsinogen

Pancreatic Enzymes

- **Pancreatic Lipase**

- **A triglyceride molecule cannot be directly absorbed across the intestinal mucosa.**
 - digested into a monoglyceride and free fatty acids.
- Sufficient quantities of bile salts must also be present in the lumen of the intestine in order for lipase to efficiently digest dietary triglyceride and for the resulting fatty acids and monoglyceride to be absorbed.

Pancreatic Enzymes

- **Amylase**
 - hydrolyses starch to maltose (a glucose-glucose disaccharide), as well as the trisaccharide maltotriose and small branchpoints fragments called limit dextrins.
- **Other Pancreatic Enzymes**
 - ribonuclease
 - deoxyribonuclease
 - gelatinase
 - elastase
- **Bicarbonate and Water**
 - Epithelial cells in pancreatic ducts are the source of the bicarbonate and water secreted by the pancreas.