

## REVIEW ARTICLE

Dan L. Longo, M.D., *Editor*

## Graves' Disease

Terry J. Smith, M.D., and Laszlo Hegedüs, M.D., D.M.Sc.

From the Department of Ophthalmology and Visual Sciences, Kellogg Eye Center, and the Department of Internal Medicine, University of Michigan Medical School — both in Ann Arbor (T.J.S.); and the Departments of Endocrinology and Metabolism (L.H.) and Ophthalmology (T.J.S.), Odense University Hospital, University of Southern Denmark, Odense. Address reprint requests to Dr. Smith at the Department of Ophthalmology and Visual Sciences, University of Michigan Medical School, Brehm Tower, 1000 Wall St., Ann Arbor, MI 48105, or at [terrysmi@med.umich.edu](mailto:terrysmi@med.umich.edu).

N Engl J Med 2016;375:1552-65.  
DOI: 10.1056/NEJMra1510030  
Copyright © 2016 Massachusetts Medical Society.

**G**RAVES' DISEASE WAS FIRST RECOGNIZED IN THE 19TH CENTURY AS A syndrome comprising an enlarged and overactive thyroid gland, an accelerated heart rate, and ocular abnormalities (Fig. 1). Critical for our current understanding of this disease was the discovery of its autoimmune basis, which results from complex interactions between genetic and environmental factors.<sup>1,2</sup> Graves' disease has adverse effects on quality of life,<sup>3</sup> as a consequence of somatic<sup>4</sup> and psychiatric<sup>5</sup> symptoms and an inability to work,<sup>6</sup> and is associated with an increased risk of death.<sup>7</sup> Activating thyrotropin-receptor antibodies induce thyroid hormone overproduction. Many characteristic signs and symptoms of Graves' disease result from elevated thyroid hormone levels. Debate persists concerning the diagnosis of hyperthyroidism and adequate clinical care of affected patients.<sup>8,9</sup> Thyroid-associated ophthalmopathy (Fig. 1B), the most common and serious extrathyroidal manifestation, results from underlying autoimmunity, but insights into its pathogenesis and care remain elusive.

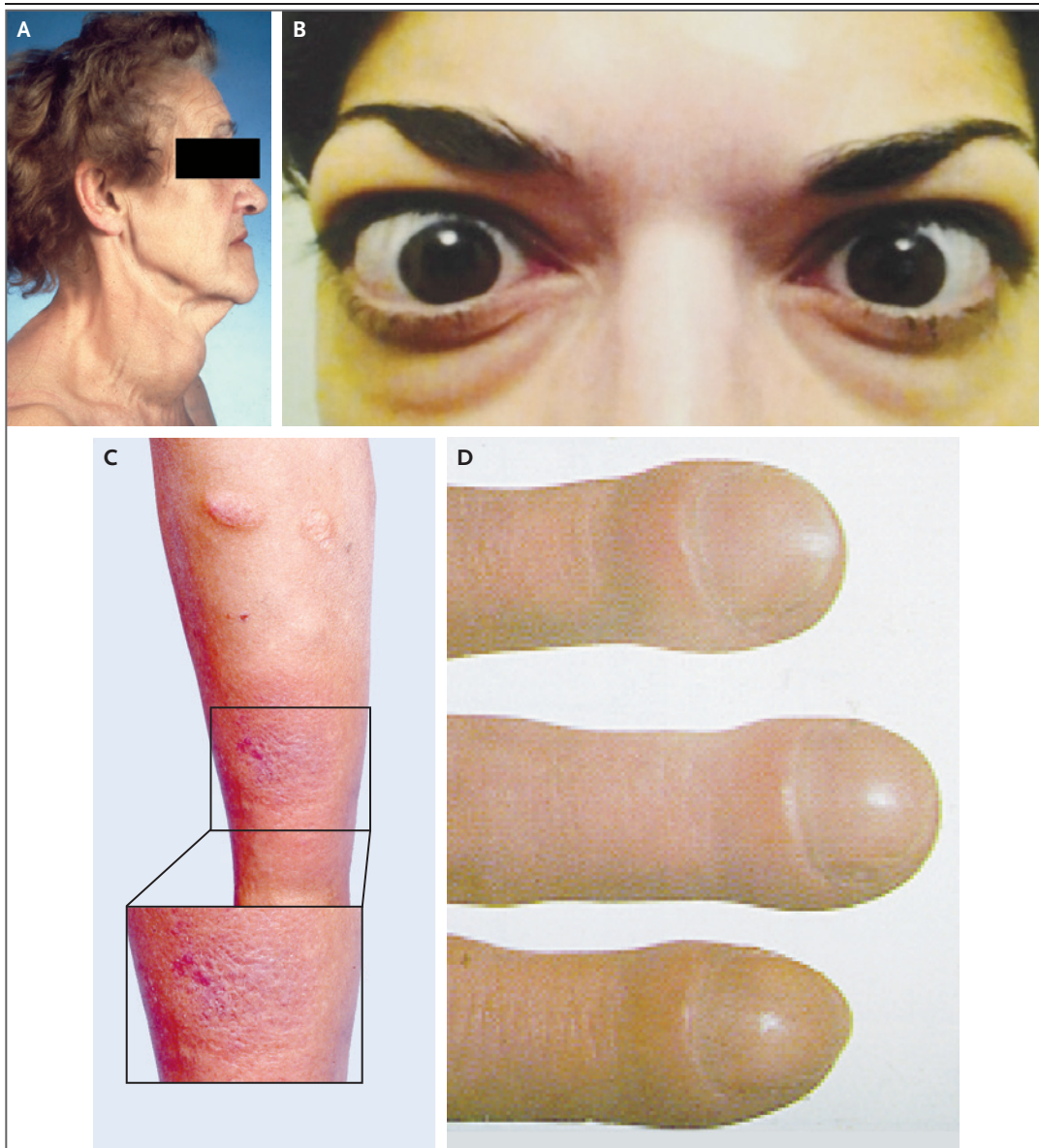
## EPIDEMIOLOGY

Graves' disease is the most common cause of hyperthyroidism, with an annual incidence of 20 to 50 cases per 100,000 persons.<sup>10</sup> The incidence peaks between 30 and 50 years of age, but people can be affected at any age. The lifetime risk is 3% for women and 0.5% for men. Long-term variations in iodine intake do not influence the risk of disease, but rapid repletion can transiently increase the incidence. The annual incidence of Graves' disease–associated ophthalmopathy is 16 cases per 100,000 women and 3 cases per 100,000 men. It is more common in whites than in Asians.<sup>11</sup> Severe ophthalmopathy is more likely to develop in older men than in younger persons.<sup>12</sup> Orbital imaging reveals subtle abnormalities in 70% of patients with Graves' disease.<sup>13</sup> In specialized centers, clinically consequential ophthalmopathy is detected in up to 50% of patients with Graves' disease, and it threatens sight as a consequence of corneal breakdown or optic neuropathy in 3 to 5% of such patients.<sup>14</sup> Hyperthyroidism and ophthalmopathy typically occur within 1 year of each other but can be separated by decades. In 10% of persons with ophthalmopathy, either thyroid levels remain normal or autoimmune hypothyroidism develops.<sup>12,14</sup>

## CLINICAL PRESENTATION

## HYPERTHYROIDISM

The manifestations of Graves' disease depend on the age of the patient at the onset of hyperthyroidism, as well as the severity and the duration of hyperthyroidism.<sup>15</sup> Symptoms and signs result from hyperthyroidism (goiter in some cases) or are a consequence of underlying autoimmunity (Table 1). Weight loss, fatigue, heat



**Figure 1. Clinical Manifestations of Graves' Disease.**

Panel A shows a diffuse, moderately enlarged goiter in a woman with Graves' hyperthyroidism. Panel B shows moderate-to-severe, thyroid-associated ophthalmopathy characterized by bilateral proptosis, periorbital edema, scleral injection, and lid retraction. Panel C shows the plaque form of pretibial dermopathy. Panel D shows acropachy with clubbing of the fingers.

intolerance, tremor, and palpitations are the most common symptoms, occurring in more than 50% of patients. Weight loss, decreased appetite, and cardiac manifestations are more common in elderly persons with hyperthyroidism than in those who are younger. Atrial fibrillation due to hyperthyroidism is rare in patients who are younger than 60 years of age but occurs in more than

10% of patients who are 60 years of age or older. Palpable goiter develops in most patients with hyperthyroidism who are younger than 60 years of age (Fig. 1A), as compared with less than 50% of older patients.<sup>16</sup> Diffuse thyroid enlargement is most frequent, but many patients with Graves' disease who live in iodine-deficient regions have coexisting nodular goiter.<sup>17</sup>

**Table 1. Major Symptoms and Physical Signs in Graves' Disease.****Symptoms**

Weight loss (weight gain in 10% of patients)  
 Palpitations  
 Dyspnea  
 Tremor  
 Tiredness, fatigue, muscle weakness  
 Heat intolerance, increased sweating  
 Increased stool frequency  
 Anxiety, altered mood, insomnia  
 Nervousness, hyperactivity  
 Pruritus  
 Thirst and polyuria  
 Menstrual disturbances in women (oligomenorrhea or amenorrhea)  
 Loss of libido  
 Neck fullness  
 Eye symptoms (swelling, pain, redness, double vision)

**Physical signs of hyperthyroidism**

Tachycardia, atrial fibrillation  
 Systolic hypertension, increased pulse pressure  
 Cardiac failure  
 Weight loss  
 Fine tremor, hyperkinesia, hyperreflexia  
 Warm, moist skin  
 Palmar erythema and onycholysis  
 Muscle weakness  
 Hair loss  
 Diffuse, palpable goiter and thyroid bruit  
 Mental-status and mood changes (e.g., mania or depression)

**Extrathyroidal physical signs**

Ophthalmopathy  
 Eyelid lag, retraction, or both  
 Proptosis (exophthalmos)  
 Double vision (extraocular-muscle dysfunction)  
 Periorbital edema, chemosis, scleral injection  
 Exposure keratitis  
 Optic neuropathy  
 Localized dermatopathy  
 Acropachy

**THYROID-ASSOCIATED OPHTHALMOPATHY**

Orbital involvement represents a parallel consequence of the underlying autoimmunity occurring within the thyroid. Ophthalmopathy can be disfiguring and can threaten sight. Its clinical course typically follows a pattern originally described by Rundle and Wilson.<sup>18</sup> Disease devel-

opment is heralded by an active phase lasting up to 3 years and dominated by evolving symptoms and signs of inflammation and congestion. Proptosis (Fig. 1B), eyelid swelling, and diplopia may prompt initial medical attention. Some patients have dry eye, increased tearing, and ocular discomfort early in the active phase. This is followed by an inactive phase in which the ocular manifestations become stable. Table 1 lists the most common features of ophthalmopathy. In a cohort of consecutively assessed patients with Graves' disease, the prevalence of distinct abnormalities was as follows: eyelid retraction, 92%; exophthalmos, 62%; extraocular muscle dysfunction, 43%; ocular pain, 30%; increased lacrimation, 23%; and optic neuropathy, 6%.<sup>19</sup>

Mild eyelid retraction or lag may occur in thyrotoxicosis from any cause, as a result of increased sympathetic tone. The activity of ophthalmopathy can be graded by assigning 1 point for each of the following manifestations: eyelid erythema and edema, conjunctiva injection, caruncular swelling, chemosis, retrobulbar pain, and pain with eye movement. A score of 3 or higher indicates active disease. The activity score — together with an evaluation of the severity of symptoms, including proptosis, reduced visual acuity, and impaired eye movement — guides treatment decisions.<sup>20</sup>

**LOCALIZED DERMOPATHY AND ACROPACHY**

Thyroid dermatopathy (Fig. 1C) occurs in 1 to 4% of patients with Graves' disease and is nearly always seen in those with severe ophthalmopathy.<sup>21</sup> It most frequently localizes to the pretibial region but can occur elsewhere, especially after trauma to the skin. Acropachy resembles clubbing of the fingers or toes and occurs only in patients with dermatopathy<sup>21</sup> (Fig. 1D).

**PATHOGENESIS****INITIATING FACTORS**

Unambiguous identification of the factors underlying Graves' disease has not yet been accomplished. Genetic and epigenetic determinants are leading candidates for these factors.<sup>1,2,22</sup> Large-scale genetic analyses have identified several genes conferring susceptibility. These include genes encoding thyroglobulin, thyrotropin receptor, HLA-DR $\beta$ -Arg74, the protein tyrosine phosphatase nonreceptor type 22 (PTPN22), cytotoxic

T-lymphocyte-associated antigen 4 (CTLA4), CD25, and CD40.<sup>1</sup> Hypermethylation of several genes has been identified, including those encoding thyrotropin receptor and proteins involved in T-cell signaling.<sup>22</sup> Environmental factors such as dietary iodine, exposure to tobacco smoke, infections, and emotional stress are frequently cited. Therapy with alemtuzumab, a CD52-targeting monoclonal antibody, can induce Graves' disease.<sup>23</sup> How these diverse factors interact to confer a risk of disease remains uncertain.<sup>24</sup>

#### ANTI-THYROTROPIN-RECEPTOR ANTIBODIES

Activating autoantibodies of the IgG1 subclass that are directed against the thyrotropin receptor are both specific for and central to Graves' disease (Fig. 2A).<sup>25</sup> Their oligoclonal generation, primarily by intrathyroidal B cells, reflects the disease's primary autoimmune reaction. These antibodies stimulate thyroid hormone production that is uncontrolled by the hypothalamic-pituitary axis. Activating antibodies mimic the actions of thyrotropin at its receptor through the initiation of similar, but not identical, signaling.<sup>26</sup> In addition to activating antibodies, those that block the thyrotropin receptor can result in hypothyroidism. The balance between stimulatory and blocking antibodies determines the level of thyroid function. Anti-thyrotropin-receptor antibodies recognize epitopes on the alpha subunit. A recent study has shown the importance of the multimeric form of the alpha subunit in promoting affinity maturation of these immunoglobulins.<sup>27</sup> Besides thyrotropin-receptor antibodies, antibodies directed at thyroglobulin and thyroperoxidase are frequently detected in patients with Graves' disease. These antibodies most likely arise from antigen spreading and have no known pathological role. Activating antibodies targeting the insulin-like growth factor 1 receptor have also been detected in patients with Graves' disease and may play a role in ophthalmopathy (discussed below).<sup>28</sup>

#### T CELLS AND B CELLS

Both T cells and B cells, critical components of adaptive immunity, are necessary for the development of Graves' disease. Thymic education of immune cells leads to the deletion of autoreactive T cells from the lymphocyte pool. These T cells show proliferative responses through antigen-specific interactions occurring between T-cell

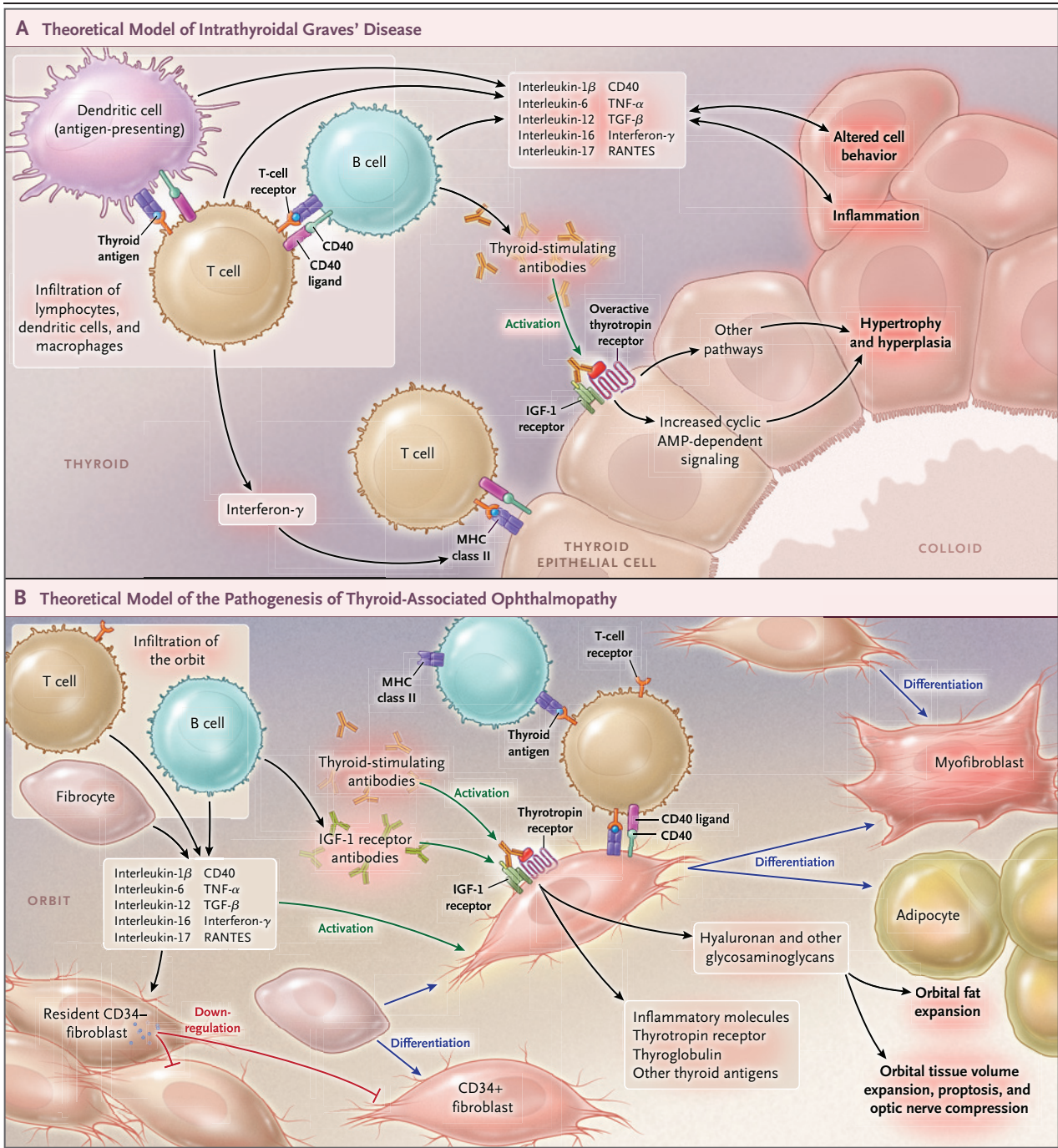
receptors and major-histocompatibility-complex (MHC) molecules on antigen-presenting cells such as dendritic cells, monocytes, and B cells. T cells rely on second signals, without which they become anergic. Some T cells differentiate into effector-cell phenotypes that have the functions of type 1, type 2, or type 17 helper T cells (Th1, Th2, or Th17). Others develop into regulatory T cells (e.g., regulatory T cells with the CD25+Foxp3+ phenotype), which can attenuate immune reactivity.<sup>29</sup> Each phenotype produces a characteristic pattern of cytokines. The balance between proinflammatory factors and factors that dampen immune reactivity determines the amplitude and duration of immune responses. In Graves' disease, autoreactive T cells against the thyrotropin receptor have escaped both central (thymic) and peripheral editing. Receptors on these CD4+ helper T cells interact with MHC class II molecules through which thyrotropin-receptor peptides are presented. Intrathyroidal T cells are particularly reactive to thyroid antigens and predominantly have the Th2 phenotype.<sup>29</sup> However, the issue of whether Graves' disease is biased to the Th1 or Th2 functional subset remains controversial.<sup>30</sup> Variable-region gene use by clonally expanded intrathyroidal T cells is biased as compared with peripheral-blood T cells.<sup>31</sup>

B cells develop into antibody-producing plasma cells in a process requiring second signals. The first of these signals is provided by antigen binding to the B-cell receptor and the second by CD40 on the B-cell surface interacting with CD40 ligand on T cells. These interactions result in the production of critical cytokines, such as interleukin-4, which promote antibody secretion and T-cell support of class switching. B cells initially produce IgM, which can be class-switched to IgG or IgE. Intrathyroidal B cells have reduced mitogenic responses but spontaneously secrete anti-thyrotropin-receptor antibodies. They are presumed to be the principal source for these antibodies, although peripheral-blood B cells are also a likely source.<sup>32</sup>

#### THYROID EPITHELIAL-CELL INVOLVEMENT

The precise role (or roles) of thyroid epithelial cells in the pathogenesis of Graves' disease remains incompletely understood. These cells express important organ-specific antigens, such as the thyrotropin receptor, thyroglobulin, and





thyroperoxidase. Thyroid epithelial cells release several chemokines and thus may participate in the recruitment of these and other immune cells.<sup>33</sup> In Graves' disease, thyroid epithelial cells also express MHC class II molecules, probably as a consequence of infiltrating, lymphocyte-produced interferon- $\gamma$  action in situ.<sup>34</sup> Thus, although thy-

roid epithelial cells are not considered professional antigen-presenting cells, they have the potential to present thyroid antigens to T cells. In addition, their CD40 expression<sup>35,36</sup> suggests the potential for direct, productive interactions between thyroid epithelium and antigen-specific T cells in Graves' disease. The aggregate of cur-

**Figure 2 (facing page). Pathogenesis of Graves' Disease Affecting the Thyroid Gland and Orbit.**

Panel A shows a theoretical model of the pathogenesis of intrathyroidal Graves' disease. Thyroid-stimulating immunoglobulins provoke the overproduction of thyroid hormones by activating the thyrotropin receptor, thus abrogating the normal regulatory role of thyrotropin. In addition, infiltrating immune cells such as B and T cells and antigen-presenting cells produce interleukins 1 $\beta$ , 6, and 12; interferon- $\gamma$ ; tumor necrosis factor  $\alpha$ ; CD40 ligand; and other cytokines. These cytokines, in turn, activate and sustain inflammation and alter the behavior of thyroid epithelial cells. Antithyroid drugs can attenuate the production of thyroid hormones and the expression of intrathyroidal cytokines and thus modulate the autoimmune process. Panel B shows a theoretical model of the pathogenesis of thyroid-associated ophthalmopathy. The orbit becomes infiltrated by B and T cells and CD34+ fibrocytes. The bone marrow-derived fibrocytes differentiate into CD34+ fibroblasts, which can further differentiate into myofibroblasts or adipocytes. CD34+ fibroblasts coinhabit the orbit with residential CD34- fibroblasts. These cells can all produce cytokines, depending on the molecular signals they encounter in the microenvironment. These include interleukins 1 $\beta$ , 6, 8, and 16; tumor necrosis factor  $\alpha$  (TNF- $\alpha$ ); RANTES (regulated on activation, normal T-cell expressed and secreted); and CD40 ligand. These cytokines, in turn, activate orbital fibroblasts. The CD34+ fibroblasts express low levels of thyrotropin receptor, thyroglobulin, and other thyroid antigens. Thyroid-stimulating immunoglobulins activate the thyrotropin-insulin-like growth factor 1 (IGF-1) receptor complex, leading to the expression of inflammatory molecules and glycosaminoglycan synthesis. In addition, immunoglobulins directed against the IGF-1 receptor can activate signaling in orbital fibroblasts, leading to cytokine and hyaluronan production. Cytokine-activated fibroblasts synthesize hyaluronan and other glycosaminoglycans, which expand orbital tissue and cause proptosis and optic-nerve compression. In addition, the orbital fat expands, probably as a consequence of adipogenesis. MHC denotes major histocompatibility complex, and TGF- $\beta$  transforming growth factor  $\beta$ .

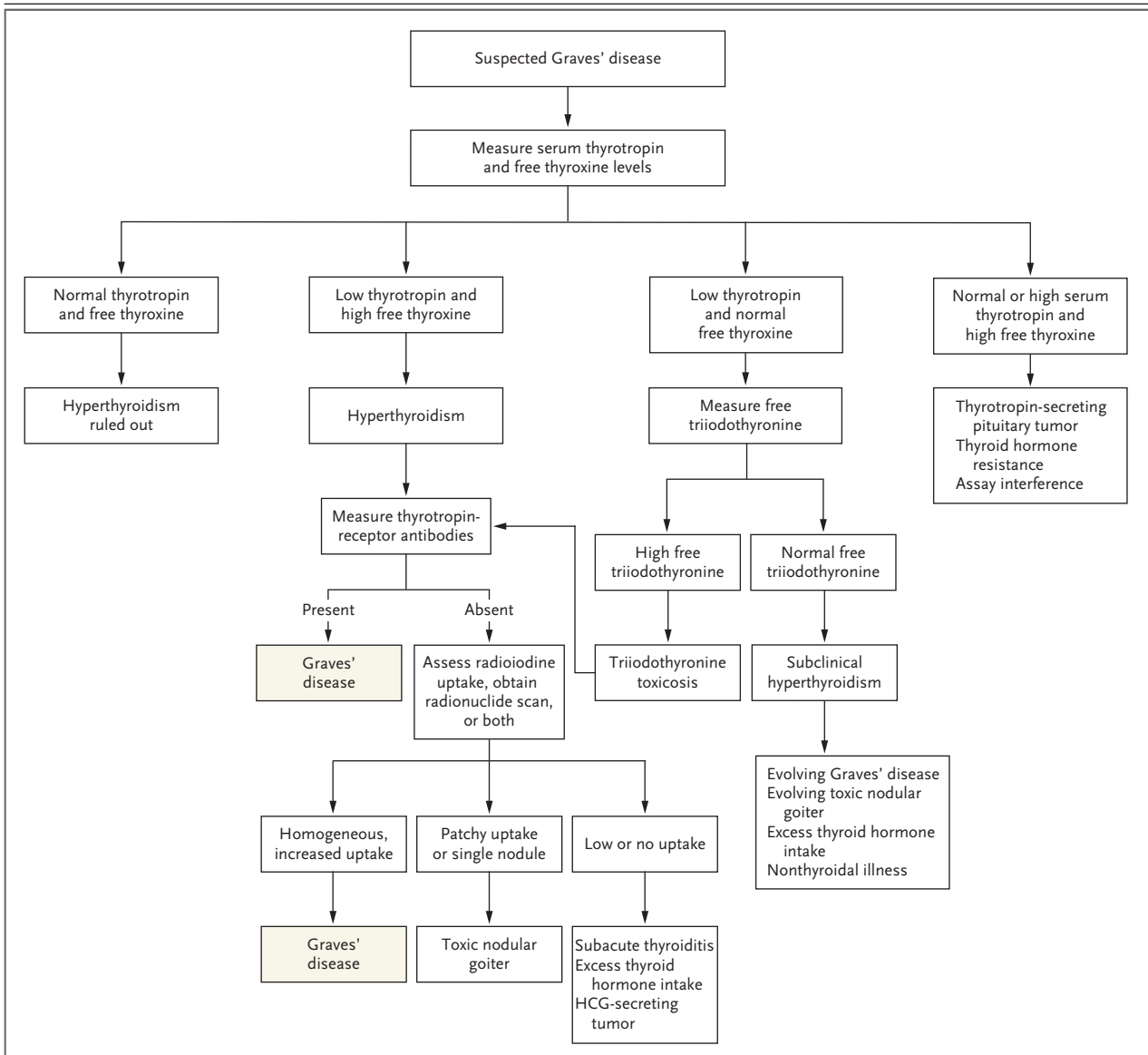
rent information suggests that the epithelium plays a secondary, passive role in the pathogenesis of Graves' disease after immune cells have infiltrated the thyroid gland.

#### EXTRATHYROIDAL MANIFESTATIONS

In Graves' disease, the immune pathogenesis of ophthalmopathy and that of hyperthyroidism are presumed to be similar. The orbital process primarily targets fibroblasts (Fig. 2B). During active disease, orbital tissues are variably infiltrated with lymphocytes; their phenotypes and

variable-region gene use have been partially characterized.<sup>37</sup> Interactions between T cells and fibroblasts result in tissue activation and induction of genes involved in inflammation and tissue remodeling.<sup>38</sup> These events are mediated by several cytokines, including interleukin-1 $\beta$ , interleukin-6, and CD40 ligand. Orbital fat and extraocular muscles expand from accumulating hyaluronidase-digestible material and adipogenesis.<sup>12</sup> Extraocular muscles remain intact, but fibers become widely separated. In later stages of the disease, extraocular muscles can become fibrotic, resulting in restricted motility. It remains uncertain what provokes lymphocyte infiltration, but a shared antigen in the orbit and thyroid gland, such as the thyrotropin receptor, seems likely.<sup>12</sup> This view is supported by the relatively low level of expression in orbital fat and orbital fibroblasts.<sup>12,39,40</sup> Fibroblasts inhabiting the orbit in Graves' disease are heterogeneous, and when activated by cytokines, they produce hyaluronan and several inflammatory mediators. Fibroblasts that display CD34, CXCR4, and collagen 1 are apparently derived from circulating fibrocytes,<sup>40,41</sup> which are monocyte-lineage progenitor cells with inflammatory characteristics. The unique presence of fibrocytes in the orbit in ophthalmopathy suggests that they play a part in disease development. Fibrocytes promiscuously express proteins previously thought to be restricted to the thyroid. These include thyrotropin receptor, thyroglobulin, thyroperoxidase, and sodium-iodide symporter, the expression of which is driven by the autoimmune regulator protein.<sup>41,42</sup> Moreover, fibrocytes efficiently present antigens to T cells. When activated by thyrotropin or thyroid-stimulating immunoglobulins, fibrocytes release cytokines that have been implicated in Graves' disease. Fibrocytes can differentiate into adipocytes or myofibroblasts and thus might contribute to the tissue remodeling in ophthalmopathy.

Involvement of the insulin-like growth factor 1 receptor in ophthalmopathy is suggested by its overexpression by orbital fibroblasts, T cells, and B cells in Graves' disease.<sup>28,43,44</sup> Furthermore, serum antibodies against this receptor can be detected in some persons with the disease, although the interpretation of this finding remains controversial. A functional and physical relationship between the insulin-like growth factor 1 receptor and the thyrotropin receptor has been



**Figure 3. Algorithm for Investigating the Clinical Suspicion of Graves' Disease.**

Not all experts rely on measurement of free thyroid hormone levels to determine the presence or absence of Graves' disease. Some favor measurement of total thyroid hormone levels corrected for serum protein binding. At diagnosis, many favor measurement of both free thyroxine and free (or total) triiodothyronine levels. HCG denotes human chorionic gonadotropin.

identified.<sup>45</sup> Interrupting the insulin-like growth factor 1 receptor attenuates signaling downstream from the thyrotropin receptor,<sup>45</sup> an observation that has subsequently been confirmed.<sup>46</sup>

Mechanisms involved in pretibial myxedema are even less well understood. The lesions are infiltrated with hyaluronan and are typically not inflammatory.

## DIAGNOSIS

### GRAVES' HYPERTHYROIDISM

The diagnosis of hyperthyroidism is based on characteristic clinical features and biochemical abnormalities. Figure 3 shows a commonly used diagnostic algorithm, which is a sufficient tool for most cases. If pathognomonic features such



as ophthalmopathy or dermopathy are absent and a diffuse goiter is not detected, radionuclide scanning can confirm the diagnosis. These scanning studies and radioiodine uptake measurement can be used to distinguish Graves' disease from other causes of thyrotoxicosis. Routine measurement of thyrotropin-receptor antibodies is not mandatory, but when such assays are performed, they have 99% sensitivity and specificity for Graves' disease.<sup>47</sup> They are also helpful in diagnosing Graves' disease in patients with concomitant nodular goiter.<sup>17</sup> Assays that can routinely distinguish anti-thyrotropin-receptor antibodies that stimulate thyroid hormone production from those that block thyroid hormone production are under development.<sup>48</sup>

#### THYROID-ASSOCIATED OPHTHALMOPATHY

Computed tomography or magnetic resonance imaging of the orbit is warranted when the cause of ocular manifestations remains uncertain. These imaging studies are useful in distinguishing extraocular muscle enlargement from fat expansion. Especially in cases of asymmetric proptosis, ruling out orbital tumor and arteriovenous malformation is important. Assessment of the activity and severity of ophthalmopathy, which can usually be accomplished by clinical examination, helps guide therapy.<sup>49</sup> Several other imaging techniques, including orbital ultrasonography, scintigraphy with radiolabeled octreotide, gallium scanning, and thermal imaging, may be useful in more precisely defining the orbital disease.<sup>50</sup>

### THE R A P Y

#### HYPERTHYROIDISM

The discussion of treatment is limited to adult patients, since the management of Graves' disease in the young warrants separate consideration. Spontaneous remission occurs in a small proportion of patients with Graves' disease, although data on patients with durable remission are unavailable. For patients who currently smoke or formerly smoked tobacco, the efficacy of medical therapy is reduced,<sup>51</sup> and the importance of smoking cessation cannot be overstated. Autoimmune hypothyroidism develops in 10 to 20% of patients during long-term follow-up. In uncomplicated cases, antithyroid drugs remain the

first-line treatment in Europe<sup>9,52</sup> and are increasingly favored over radioiodine in North America.<sup>9</sup> Ablative therapy resulting in hypothyroidism, either from radioactive iodine or surgical thyroidectomy, necessitates lifelong thyroid hormone replacement. Thus, each treatment approach has advantages and drawbacks. The patient's preference, after receiving adequate counseling, remains a critical factor in therapy decisions. According to a randomized study with 14 to 21 years of follow-up, quality of life was similar among the various treatment options, as was cost.<sup>53</sup> Treatments for Graves' hyperthyroidism and ophthalmopathy have been reviewed in detail previously.<sup>14,54,55</sup> The most salient information is summarized in Tables 2 and 3.

#### Antithyroid Drugs

Methimazole, carbimazole (which is converted to methimazole and is not available in the United States), and propylthiouracil inhibit thyroid peroxidase and thus block thyroid hormone synthesis (Table 2). Propylthiouracil also blocks extrathyroidal deiodination of thyroxine to triiodothyronine. Methimazole is preferred for initial therapy in both Europe and North America because of its favorable side-effect profile.<sup>9,52</sup> Both methimazole and propylthiouracil are associated with a high risk of recurrence after treatment has been withdrawn. Several variables appear to be associated with durable disease remission, defined as biochemical euthyroidism for at least 12 months, after 1 to 2 years of therapy (Table 2). Durable remission occurs in 40 to 50% of patients. Repeated therapy carries an even lower likelihood of success. It remains uncertain whether remission results from immunomodulation by these drugs. The recurrence rate is not further decreased by providing treatment for more than 18 months or by combining antithyroid drugs with levothyroxine. Patients may be switched from one drug to another when necessitated by minor side effects, but 30 to 50% of patients have a similar reaction to each drug.<sup>55</sup> In our opinion, patients with severe side effects should not be further exposed to either drug. Monitoring by means of liver-function tests and white-cell counts before and during antithyroid drug therapy is advocated by some experts but is not currently supported by consensus opinion.<sup>8,9,55</sup> One randomized study showed no benefit from granulo-



**Table 2. Main Treatment Options for Graves' Hyperthyroidism.\***

Treatment	Mode of Action	Route of Administration	Advantages	Disadvantages	Special Considerations
Beta-blockers	Beta-blockers competitively block $\beta$ -adrenergic receptors; propranolol may block conversion of thyroxine to triiodothyronine	Oral; may be administered intravenously in acute cases	Ameliorates sweating, anxiety, tremulousness, palpitations, and tachycardia	Does not influence course of disease; use cautiously in patients with asthma, congestive heart failure, bradyarrhythmias, or Raynaud's phenomenon	Use cardioselective beta-blockers, especially in patients with COPD; use calcium-channel blockers as alternative
Antithyroid drugs (methimazole, carbimazole, and propylthiouracil)	Methimazole, carbimazole, and propylthiouracil block thyroid peroxidase and thyroid hormone synthesis; propylthiouracil also blocks conversion of thyroxine to triiodothyronine	Given as either a single, high fixed dose (e.g., 10–30 mg of methimazole or 200–600 mg of propylthiouracil daily) and adjusted as euthyroidism is achieved or combined with thyroxine to prevent hypothyroidism ("block–replace" regimen)	Outpatient therapy; low risk of hypothyroidism; no radiation hazard or surgical risk; remission rate, 40–50% <sup>36,†</sup>	High recurrence rate; frequent testing required unless block–replace therapy is used; minor side effects in $\leq 5\%$ of patients (rash, urticaria, arthralgia, fever, nausea, abnormalities of taste and smell) <sup>34</sup>	Major side effects in 0.2–0.3% of patients, <sup>36,37</sup> usually within first 3 mo of therapy; agranulocytosis in $< 0.2\%$ of patients; hepatotoxicity in $\leq 0.1\%$ ; cholestatic for the thionamides and hepatocellular necrosis for propylthiouracil; antineutrophil cytoplasmic antibody–associated vasculitis in $\leq 0.1\%$ of patients <sup>37,38</sup>
Radioactive iodine (iodine-131)	Irradiation causes thyroid cell damage and cell death	Oral; activity either fixed (e.g., 15 mCi [555 MBq]) or calculated on the basis of goiter size and uptake and turnover investigations	Normally outpatient procedure, definitive therapy, low cost, few side effects, effectively reduces goiter size	Potential radiation hazards, adherence to a country's particular radiation regulations, radiation thyroiditis, decreasing efficacy with increasing goiter size, eventual hypothyroidism in most patients	Should not be used in patients with active thyroid ophthalmopathy; contraindicated in women who are pregnant or breast-feeding and for 6 wk after breast-feeding has stopped
Thyroidectomy	Most or all thyroid tissue is removed surgically		Rapid euthyroidism, recurrence extremely rare, <sup>‡</sup> no radiation hazard, definitive histologic results, rapid relief of pressure symptoms	Most expensive therapy, hypothyroidism is the aim, risks associated with surgery and anesthesia, minor complications in 1–2% of patients (bleeding, infection, scarring), major complications in 1–4% (hypoparathyroidism, recurrent laryngeal-nerve damage)	Does not influence course of Graves' ophthalmopathy; during pregnancy, is best performed during the second trimester <sup>8</sup>

\* COPD denotes chronic obstructive pulmonary disease.

† The following factors are associated with an increased risk of recurrence after antithyroid drug therapy: previous recurrence of Graves' disease, cigarette smoking, ophthalmopathy, large goiter, elevated ratio of serum free triiodothyronine to free thyroxine, high titers of serum anti-thyrotropin-receptor antibodies, and persistent need for high-dose antithyroid drugs after 12 to 18 months of treatment. In the absence of these risk factors, euthyroidism is generally sustained for at least 12 months after therapy has been withdrawn.

‡ The risks of hypothyroidism and persistent or recurrent hyperthyroidism are related to the volume of residual thyroid tissue.

cyte colony-stimulating factor in patients with agranulocytosis.<sup>64</sup>

#### *Radioactive Iodine*

Radioactive iodine therapy has been used widely in patients with Graves' disease for seven decades.<sup>65</sup> It offers relief from symptoms of hyperthyroidism within weeks. Treatment with antithyroid drugs may be suspended 3 to 7 days before and after radiotherapy in order to enhance its efficacy, although this interval remains controversial.<sup>66</sup> Many clinicians use fixed doses of radioiodine, since calculation of activity is costly and fails to reduce rates of hypothyroidism or recurrent hyperthyroidism.<sup>65</sup> Radioiodine is not associated with an increased risk of cancer<sup>67</sup> but is known to provoke or worsen ophthalmopathy.<sup>14</sup> Instead, increased morbidity and mortality associated with Graves' disease appear to be related to hyperthyroidism itself.<sup>4-7</sup> Postablation thyroid function should be monitored throughout life, and if hypothyroidism develops, it should be treated immediately.

#### *Surgery*

Before patients undergo surgical thyroidectomy, their thyroid hormone levels should be normal to minimize the risk of complications or a poor outcome, which is higher for total thyroidectomy than for subtotal thyroidectomy. The risks of hypothyroidism and recurrent hyperthyroidism are inversely related and depend on the volume of residual tissue.<sup>68,69</sup> Treatment with inorganic iodide commencing 1 week before surgery may decrease thyroid blood flow, vascularity, and blood loss but does not otherwise influence surgical risk.<sup>70</sup> Surgery may be an attractive option for patients with large goiters, women wishing to become pregnant shortly after treatment, and patients who want to avoid exposure to antithyroid drugs or radioiodine. It is recommended that women who have undergone surgery wait until the serum thyrotropin level stabilizes with levothyroxine therapy before attempting conception. The course of ophthalmopathy appears to be unaffected by surgical thyroidectomy.<sup>8,20,71</sup>

#### *Treatment during Pregnancy*

Graves' disease affects approximately 0.1% of pregnancies and carries a substantial risk of adverse effects in mother and child, especially if it is inadequately treated.<sup>72</sup> The lowest effective

dose of an antithyroid drug should be used to maintain thyroid function at the upper limit of the normal range in order to avoid fetal hypothyroidism. Both propylthiouracil and methimazole are associated with birth defects.<sup>57</sup> The use of propylthiouracil in the first trimester and methimazole during the remainder of pregnancy is currently recommended on the basis of a consideration of potentially severe birth defects.<sup>73</sup> Thyroid function should be monitored monthly. In up to 50% of cases, antithyroid drugs may be discontinued after the first trimester, but postpartum relapse is common.<sup>72</sup> If elevated by a factor of more than 3, the level of anti-thyrotropin-receptor antibodies, beginning at a gestational age of 18 to 24 weeks, identifies pregnancies at risk for neonatal hyperthyroidism.<sup>72</sup> Breast-feeding is safe with either methimazole or propylthiouracil, but methimazole is recommended for postpartum therapy and does not affect infant thyroid function in the doses commonly used.<sup>74,75</sup>

#### **OPHTHALMOPATHY**

Treatment for ophthalmopathy depends on the phase and severity of the disease. The majority of patients require only conservative measures (Table 3). These include enhancement of tear-film quality and maintenance of ocular surface moisture. Patients with disease that is severely symptomatic and sight-threatening may benefit from intravenously administered pulse glucocorticoid therapy, which appears to have a more favorable side-effect profile than glucocorticoids administered orally, although pulse therapy is not without risks.<sup>60,61,76</sup> Glucocorticoids are frequently effective in reducing inflammatory symptoms, but most experts do not believe that they modify the course of the disease. External-beam irradiation of severely affected orbits is used in some specialized centers but not others.<sup>77</sup> The combination of glucocorticoids and radiotherapy may provide a greater benefit than either treatment used alone.<sup>62</sup> Orbital decompression surgery during active disease is usually reserved for patients in whom compressive optic neuropathy has developed or is imminent.<sup>78</sup> Decompression surgery is also indicated when the ocular surface is severely compromised. These situations constitute surgical emergencies. Rituximab, a biologic agent that depletes CD20+ B cells, has been evaluated recently in two prospective, randomized pilot studies involving patients with active, severe

**Table 3. Treatments for Thyroid-Associated Ophthalmopathy.**

Therapy	Mode of Action	Pros and Cons	Common Doses
<b>Mild active disease</b>			
Topical solutions			
Artificial tears	Maintain tear film	Rapid action, minimal side effects	
Glucocorticoids	Reduce inflammation	Rapid action, minimal side effects	
Avoidance of wind, light, dust, smoke	Reduces ocular surface desiccation, reduces irritation		
Elevation of head during sleep	Reduces orbital congestion		
Avoidance of eye cosmetics	Reduces irritation	Benefits not yet confirmed	
Selenium <sup>59</sup>	Uncertain	Benefits not yet confirmed	
<b>Moderate or severe active disease</b>			
Systemic glucocorticoids			
Oral	Reduce inflammation and orbital congestion	Hyperglycemia, hypertension, osteoporosis	Up to 100 mg of oral prednisone daily, followed by tapering of the dose <sup>60</sup>
Intravenous	Reduce inflammation and orbital congestion	Rapid onset of anti-inflammatory effect, fewer side effects than oral delivery, liver damage on rare occasions	Methylprednisolone, 500 mg/wk for 6 wk followed by 250 mg/wk for 6 wk <sup>61,62</sup>
Orbital irradiation	Reduces inflammation	Can induce retinopathy	2 Gy daily for 2 wk (20 Gy total) <sup>63</sup>
B-cell depletion*	Reduces autoreactive B cells	Very expensive; risks of infection, cancer, allergic reaction	Two 1000-mg doses of intravenous rituximab 2 wk apart
Emergency orbital decompression†	Reduces orbital volume		
<b>Stable disease (inactive)</b>			
Orbital decompression (fat removal)	Reduces orbital volume	Postoperative diplopia, pain	
Bony decompression of the lateral and medial walls	Reduces proptosis by enlarging orbital space	Postoperative diplopia, pain, sinus bleeding, cerebrospinal fluid leak	
Strabismus repair	Improves eye alignment, reduces diplopia		
Eyelid repair	Improves appearance, reduces lagophthalmos, and improves function		

\* B-cell depletion with the use of rituximab is currently considered an experimental treatment for ophthalmopathy; rituximab is not approved by the Food and Drug Administration for this indication.

† Emergency orbital decompression is indicated for optic neuropathy or severe corneal exposure.

ophthalmopathy. One trial suggested efficacy,<sup>79</sup> whereas the other did not.<sup>80</sup>

Therapy during the stable phase of moderate-to-severe ophthalmopathy usually involves rehabilitative surgery aimed at reducing proptosis, restoring function, and enhancing appearance. The procedures are usually performed in a set sequence, beginning with orbital decompression. Multiple approaches to surgical decompression have been perfected, but controlled studies of their

relative efficacies have not been performed.<sup>81</sup> The decision about which approach should be used depends on the primary objective of the surgery and the skill of the surgeon.<sup>78</sup> In patients with diplopia, surgical decompression is followed by strabismus surgery to correct abnormalities of eye motility.<sup>82</sup> Cosmetic and functional concerns are addressed last, with facelifts, tissue fillers, and eyelid repair.

Most assessments of therapy for Graves' hyper-

thyroidism suggest that radioactive iodine ablation increases the risk of new or worsening ophthalmopathy.<sup>8</sup> Glucocorticoids appear to mitigate this risk.<sup>83</sup> In contrast, most studies have failed to detect differences in the effect on ophthalmopathy between surgical thyroidectomy and medical therapy.

#### DERMOPATHY AND ACROPACHY

Topical glucocorticoids can be used for symptomatic and extensive dermatopathy but are usually ineffective.<sup>21</sup> The observation of a striking improvement in dermatopathy after rituximab infusion<sup>84</sup> suggests that B-cell depletion may benefit affected patients. However, this treatment is experimental and has not been approved by the Food and Drug Administration. No specific therapy is available for acropachy.

#### FUTURE THERAPIES

As we gain a clearer understanding of Graves' disease, the potential for "smart drug" development increases. Repurposing agents that effectively disrupt cytokine networks in rheumatoid

arthritis appears to be an attractive approach, but controlled, prospective trials are necessary. Agents blocking the thyrotropin and insulin-like growth factor receptors are under consideration.<sup>45,46</sup> For example, a randomized, placebo-controlled clinical trial of the efficacy and safety of teprotumumab, an insulin-like growth factor 1 receptor–blocking monoclonal antibody, in patients with active, severe ophthalmopathy has recently been completed (ClinicalTrials.gov number, NCT01868997). Graves' disease appears to be an ideal candidate for antigen-specific therapy, since the identity of a dominant self-antigen is known. Restoring immune tolerance to the thyrotropin receptor and other relevant autoantigens remains the ultimate goal, sparing patients nonspecific immunosuppression and toxic drugs.

Dr. Smith reports holding patents related to the detection of antibody-mediated inflammatory auto-immune disorders (US 6936426), the diagnosis and therapy of antibody-mediated inflammatory autoimmune disorders (US 7998681 and US 8153121), and diagnostic methods related to Graves' disease and other autoimmune disorders (US 8178304). No other potential conflict of interest relevant to this article was reported.

Disclosure forms provided by the authors are available with the full text of this article at NEJM.org.

#### REFERENCES

- Tomer Y. Mechanisms of autoimmune thyroid diseases: from genetics to epigenetics. *Annu Rev Pathol* 2014;9:147-56.
- Brix TH, Kyvik KO, Christensen K, Hegedüs L. Evidence for a major role of heredity in Graves' disease: a population-based study of two Danish twin cohorts. *J Clin Endocrinol Metab* 2001;86:930-4.
- Kahaly GJ, Petrak F, Hardt J, Pitz S, Egle UT. Psychosocial morbidity of Graves' orbitopathy. *Clin Endocrinol (Oxf)* 2005; 63:395-402.
- Brandt F, Thvilum M, Almind D, et al. Morbidity before and after the diagnosis of hyperthyroidism: a nationwide register-based study. *PLoS One* 2013;8(6):e66711.
- Brandt F, Thvilum M, Almind D, et al. Hyperthyroidism and psychiatric morbidity: evidence from a Danish nationwide register study. *Eur J Endocrinol* 2014;170: 341-8.
- Brandt F, Thvilum M, Hegedüs L, Brix TH. Hyperthyroidism is associated with work disability and loss of labour market income: a Danish register-based study in singletons and disease-discordant twin pairs. *Eur J Endocrinol* 2015;173:595-602.
- Brandt F, Almind D, Christensen K, Green A, Brix TH, Hegedüs L. Excess mortality in hyperthyroidism: the influence of preexisting comorbidity and genetic confounding: a Danish nationwide register-based cohort study of twins and singletons. *J Clin Endocrinol Metab* 2012; 97:4123-9.
- Bahn RS, Burch HB, Cooper DS, et al. Hyperthyroidism and other causes of thyrotoxicosis: management guidelines of the American Thyroid Association and American Association of Clinical Endocrinologists. *Endocr Pract* 2011;17:456-520.
- Burch HB, Burman KD, Cooper DS. A 2011 survey of clinical practice patterns in the management of Graves' disease. *J Clin Endocrinol Metab* 2012;97:4549-58.
- Zimmermann MB, Boelaert K. Iodine deficiency and thyroid disorders. *Lancet Diabetes Endocrinol* 2015;3:286-95.
- Tellez M, Cooper J, Edmonds C. Graves' ophthalmopathy in relation to cigarette smoking and ethnic origin. *Clin Endocrinol (Oxf)* 1992;36:291-4.
- Bahn RS. Graves' ophthalmopathy. *N Engl J Med* 2010;362:726-38.
- Villadolid MC, Yokoyama N, Izumi M, et al. Untreated Graves' disease patients without clinical ophthalmopathy demonstrate a high frequency of extraocular muscle (EOM) enlargement by magnetic resonance. *J Clin Endocrinol Metab* 1995; 80:2830-3.
- Bartalena L, Tanda ML. Graves' ophthalmopathy. *N Engl J Med* 2009;360:994-1001.
- Nordyke RA, Gilbert FI Jr, Harada ASM. Graves' disease: influence of age on clinical findings. *Arch Intern Med* 1988; 148:626-31.
- Boelaert K, Torlinska B, Holder RL, Franklyn JA. Older subjects with hyperthyroidism present with a paucity of symptoms and signs: a large cross-sectional study. *J Clin Endocrinol Metab* 2010;95: 2715-26.
- Pedersen IB, Knudsen N, Perrild H, Ovesen L, Laurberg P. TSH-receptor antibody measurement for differentiation of hyperthyroidism into Graves' disease and multinodular toxic goitre: a comparison of two competitive binding assays. *Clin Endocrinol (Oxf)* 2001;55:381-90.
- Rundle FF, Wilson CW. Development and course of exophthalmos and ophthalmoplegia in Graves' disease with special reference to the effect of thyroidectomy. *Clin Sci* 1945;5:177-94.
- Bartley GB, Fatourechi V, Kadrmas EE, et al. Clinical features of Graves' ophthalmopathy in an incidence cohort. *Am J Ophthalmol* 1996;121:284-90.
- Bartalena L, Baldeschi L, Dickinson AJ, et al. Consensus statement of the European Group on Graves' Orbitopathy (EUGOGO) on management of Graves' orbitopathy. *Thyroid* 2008;18:333-46.
- Fatourechi V. Thyroid dermatopathy and acropachy. *Best Pract Res Clin Endocrinol Metab* 2012;26:553-65.
- Limbach M, Saare M, Tserel L, et al.



- Epigenetic profiling in CD4+ and CD8+ T cells from Graves' disease patients reveals changes in genes associated with T cell receptor signaling. *J Autoimmun* 2016;67:46-56.
23. Coles AJ, Wing M, Smith S, et al. Pulsed monoclonal antibody treatment and autoimmune thyroid disease in multiple sclerosis. *Lancet* 1999;354:1691-5.
24. Effraimidis G, Wiersinga WM. Mechanisms in endocrinology: autoimmune thyroid disease: old and new players. *Eur J Endocrinol* 2014;170:R241-52.
25. Weetman AP, Yateman ME, Ealey PA, et al. Thyroid-stimulating antibody activity between different immunoglobulin G subclasses. *J Clin Invest* 1990;86:723-7.
26. Morshed SA, Latif R, Davies TF. Characterization of thyrotropin receptor antibody-induced signaling cascades. *Endocrinology* 2009;150:519-29.
27. Rapoport B, Aliesky HA, Chen C-R, McLachlan SM. Evidence that TSH receptor A-subunit multimers, not monomers, drive antibody affinity maturation in Graves' disease. *J Clin Endocrinol Metab* 2015;100:E871-5.
28. Pritchard J, Han R, Horst N, Cruikshank WW, Smith TJ. Immunoglobulin activation of T cell chemoattractant expression in fibroblasts from patients with Graves' disease is mediated through the insulin-like growth factor I receptor pathway. *J Immunol* 2003;170:6348-54.
29. Martin A, Schwartz AE, Friedman EW, Davies TF. Successful production of intrathyroidal human T cell hybridomas: evidence for intact helper T cell function in Graves' disease. *J Clin Endocrinol Metab* 1989;69:1104-8.
30. Rapoport B, McLachlan SM. Graves' hyperthyroidism is antibody-mediated but is predominantly a Th1-type cytokine disease. *J Clin Endocrinol Metab* 2014;99:4060-1.
31. Nakashima M, Martin A, Davies TF. Intrathyroidal T cell accumulation in Graves' disease: delineation of mechanisms based on in situ T cell receptor analysis. *J Clin Endocrinol Metab* 1996;81:3346-51.
32. Nagata K, Nakayama Y, Higaki K, et al. Reactivation of persistent Epstein-Barr virus (EBV) causes secretion of thyrotropin receptor antibodies (TRAbs) in EBV-infected B lymphocytes with TRAbs on their surface. *Autoimmunity* 2015;48:328-35.
33. Armengol M-P, Cardoso-Schmidt CB, Fernández M, Ferrer X, Pujol-Borrell R, Juan M. Chemokines determine local lymphogenesis and a reduction of circulating CXCR4+ T and CCR7 B and T lymphocytes in thyroid autoimmune diseases. *J Immunol* 2003;170:6320-8.
34. Hanafusa T, Pujol-Borrell R, Chiovato L, Russell RC, Doniach D, Bottazzo GF. Aberrant expression of HLA-DR antigen on thyrocytes in Graves' disease: relevance for autoimmunity. *Lancet* 1983;2:1111-5.
35. Faure GC, Bensoussan-Lejzerowicz D, Bene MC, Aubert V, Leclere J. Coexpression of CD40 and class II antigen HLA-DR in Graves' disease thyroid epithelial cells. *Clin Immunol Immunopathol* 1997;84:212-5.
36. Smith TJ, Sciaky D, Phipps RP, Jennings TA. CD40 expression in human thyroid tissue: evidence for involvement of multiple cell types in autoimmune and neoplastic diseases. *Thyroid* 1999;9:749-55.
37. Heufelder AE, Herterich S, Ernst G, Bahn RS, Scriba PC. Analysis of retro-orbital T cell antigen receptor variable region gene usage in patients with Graves' ophthalmopathy. *Eur J Endocrinol* 1995;132:266-77.
38. Cao HJ, Wang HS, Zhang Y, Lin HY, Phipps RP, Smith TJ. Activation of human orbital fibroblasts through CD40 engagement results in a dramatic induction of hyaluronan synthesis and prostaglandin endoperoxide H synthase-2 expression: insights into potential pathogenic mechanisms of thyroid-associated ophthalmopathy. *J Biol Chem* 1998;273:29615-25.
39. Feliciello A, Porcellini A, Ciullo I, Bonavolontà G, Avvedimento EV, Fenzi G. Expression of thyrotropin-receptor mRNA in healthy and Graves' disease retro-orbital tissue. *Lancet* 1993;342:337-8.
40. Douglas RS, Afifiyan NF, Hwang CJ, et al. Increased generation of fibrocytes in thyroid-associated ophthalmopathy. *J Clin Endocrinol Metab* 2010;95:430-8.
41. Fernando R, Atkins S, Raychaudhuri N, et al. Human fibrocytes coexpress thyroglobulin and thyrotropin receptor. *Proc Natl Acad Sci U S A* 2012;109:7427-32.
42. Fernando R, Lu Y, Atkins SJ, Mester T, Branham K, Smith TJ. Expression of thyrotropin receptor, thyroglobulin, sodium-iodide symporter, and thyroperoxidase by fibrocytes depends on AIRE. *J Clin Endocrinol Metab* 2014;99:E1236-44.
43. Douglas RS, Gianoukakis AG, Kamat S, Smith TJ. Aberrant expression of the insulin-like growth factor-1 receptor by T cells from patients with Graves' disease may carry functional consequences for disease pathogenesis. *J Immunol* 2007;178:3281-7.
44. Douglas RS, Naik V, Hwang CJ, et al. B cells from patients with Graves' disease aberrantly express the IGF-1 receptor: implications for disease pathogenesis. *J Immunol* 2008;181:5768-74.
45. Tsui S, Naik V, Hoa N, et al. Evidence for an association between thyroid-stimulating hormone and insulin-like growth factor 1 receptors: a tale of two antigens implicated in Graves' disease. *J Immunol* 2008;181:4397-405.
46. Krieger CC, Neumann S, Place RF, Marcus-Samuels B, Gershengorn MC. Bidirectional TSH and IGF-1 receptor cross talk mediates stimulation of hyaluronan secretion by Graves' disease immunoglobulins. *J Clin Endocrinol Metab* 2015;100:1071-7.
47. Tozzoli R, Bagnasco M, Giavarina D, Bizzaro N. TSH receptor autoantibody immunoassay in patients with Graves' disease: improvement of diagnostic accuracy over different generations of methods: systematic review and meta-analysis. *Autoimmun Rev* 2012;12:107-13.
48. Diana T, Kanitz M, Lehmann M, Li Y, Olivio PD, Kahaly GJ. Standardization of a bioassay for thyrotropin receptor stimulating autoantibodies. *Thyroid* 2015;25:169-75.
49. Douglas RS, Tsirbas A, Gordon M, et al. Development of criteria for evaluating clinical response in thyroid eye disease using a modified Delphi technique. *Arch Ophthalmol* 2009;127:1155-60.
50. Di Maria C, Allen J, Dickinson J, Neoh C, Perros P. Novel thermal imaging analysis technique for detecting inflammation in thyroid eye disease. *J Clin Endocrinol Metab* 2014;99:4600-6.
51. Wiersinga WM. Smoking and thyroid. *Clin Endocrinol (Oxf)* 2013;79:145-51.
52. Bartalena L, Burch HB, Burman KD, Kahaly GJ. A 2013 European survey of clinical practice patterns in the management of Graves' disease. *Clin Endocrinol (Oxf)* 2016;84:115-20.
53. Ljunggren J-G, Törring O, Wallin G, et al. Quality of life aspects and costs in treatment of Graves' hyperthyroidism with antithyroid drugs, surgery, or radioiodine: results from a prospective, randomized study. *Thyroid* 1998;8:653-9.
54. Bartalena L. Diagnosis and management of Graves disease: a global overview. *Nat Rev Endocrinol* 2013;9:724-34.
55. Burch HB, Cooper DS. Management of Graves' disease: a review. *JAMA* 2015;314:2544-54.
56. Abraham P, Avenell A, McGeoch SC, Clark LF, Bevan JS. Antithyroid drug regimen for treating Graves' hyperthyroidism. *Cochrane Database Syst Rev* 2010;1:CD003420.
57. Andersen SL, Olsen J, Laurberg P. Antithyroid drug side effects in the population and in pregnancy. *J Clin Endocrinol Metab* 2016;101:1606-14.
58. Nakamura H, Miyauchi A, Miyawaki N, Imagawa J. Analysis of 754 cases of antithyroid drug-induced agranulocytosis over 30 years in Japan. *J Clin Endocrinol Metab* 2013;98:4776-83.
59. Marcocci C, Kahaly GJ, Krassas GE, et al. Selenium and the course of mild Graves' orbitopathy. *N Engl J Med* 2011;364:1920-31.
60. Zang S, Ponto KA, Kahaly GJ. Intravenous glucocorticoids for Graves' orbitopathy: efficacy and morbidity. *J Clin Endocrinol Metab* 2011;96:320-32.
61. Bartalena L, Krassas GE, Wiersinga

- W, et al. Efficacy and safety of three different cumulative doses of intravenous methylprednisolone for moderate to severe and active Graves' orbitopathy. *J Clin Endocrinol Metab* 2012;97:4454-63.
62. Marcocci C, Bartalena L, Tanda ML, et al. Comparison of the effectiveness and tolerability of intravenous or oral glucocorticoids associated with orbital radiotherapy in the management of severe Graves' ophthalmopathy: results of a prospective, single-blind, randomized study. *J Clin Endocrinol Metab* 2001;86:3562-7.
63. Kahaly GJ, Rösler HP, Pitz S, Hommel G. Low- versus high-dose radiotherapy for Graves' ophthalmopathy: a randomized, single blind trial. *J Clin Endocrinol Metab* 2000;85:102-8.
64. Fukata S, Kuma K, Sugawara M. Granulocyte colony-stimulating factor (G-CSF) does not improve recovery from antithyroid drug-induced agranulocytosis: a prospective study. *Thyroid* 1999;9:29-31.
65. Bonnema SJ, Hegedüs L. Radioiodine therapy in benign thyroid diseases: effects, side effects, and factors affecting therapeutic outcome. *Endocr Rev* 2012;33:920-80.
66. Walter MA, Briel M, Christ-Crain M, et al. Effects of antithyroid drugs on radioiodine treatment: systematic review and meta-analysis of randomised controlled trials. *BMJ* 2007;334:514.
67. Ron E, Doody MM, Becker DV, et al. Cancer mortality following treatment for adult hyperthyroidism. *JAMA* 1998;280:347-55.
68. Liu ZW, Masterson L, Fish B, Jani P, Chatterjee K. Thyroid surgery for Graves' disease and Graves' ophthalmopathy. *Cochrane Database Syst Rev* 2015;11:CD010576.
69. Feroci F, Rettori M, Borrelli A, et al. A systematic review and meta-analysis of total thyroidectomy versus bilateral subtotal thyroidectomy for Graves' disease. *Surgery* 2014;155:529-40.
70. Erbil Y, Ozluk Y, Giriş M, et al. Effect of lugol solution on thyroid gland blood flow and microvessel density in the patients with Graves' disease. *J Clin Endocrinol Metab* 2007;92:2182-9.
71. Hegedüs L, Bonnema SJ, Smith TJ, Brix TH. Treating the thyroid in the presence of Graves' ophthalmopathy. *Best Pract Res Clin Endocrinol Metab* 2012;26:313-24.
72. Cooper DS, Laurberg P. Hyperthyroidism in pregnancy. *Lancet Diabetes Endocrinol* 2013;1:238-49.
73. De Groot L, Abalovich M, Alexander EK, et al. Management of thyroid dysfunction during pregnancy and postpartum: an Endocrine Society clinical practice guideline. *J Clin Endocrinol Metab* 2012;97:2543-65.
74. Momotani N, Yamashita R, Makino F, Noh JY, Ishikawa N, Ito K. Thyroid function in wholly breast-feeding infants whose mothers take high doses of propylthiouracil. *Clin Endocrinol (Oxf)* 2000;53:177-81.
75. Azizi F, Khoshniat M, Bahrainian M, Hedayati M. Thyroid function and intellectual development of infants nursed by mothers taking methimazole. *J Clin Endocrinol Metab* 2000;85:3233-8.
76. Sisti E, Coco B, Menconi F, et al. Intravenous glucocorticoid therapy for Graves' ophthalmopathy and acute liver damage: an epidemiological study. *Eur J Endocrinol* 2015;172:269-76.
77. Tanda ML, Bartalena L. Efficacy and safety of orbital radiotherapy for Graves' orbitopathy. *J Clin Endocrinol Metab* 2012;97:3857-65.
78. Choe CH, Cho RI, Elner VM. Comparison of lateral and medial orbital decompression for the treatment of compressive optic neuropathy in thyroid eye disease. *Ophthal Plast Reconstr Surg* 2011;27:4-11.
79. Salvi M, Vannucchi G, Currò N, et al. Efficacy of B-cell targeted therapy with rituximab in patients with active moderate to severe Graves' orbitopathy: a randomized controlled study. *J Clin Endocrinol Metab* 2015;100:422-31.
80. Stan MN, Garrity JA, Carranza Leon BG, Prabin T, Bradley EA, Bahn RS. Randomized controlled trial of rituximab in patients with Graves' orbitopathy. *J Clin Endocrinol Metab* 2015;100:432-41.
81. Boboridis KG, Uddin J, Mikropoulos DG, et al. Critical appraisal on orbital decompression for thyroid eye disease: a systematic review and literature search. *Adv Ther* 2015;32:595-611.
82. Jellema HM, Braaksma-Besselink Y, Limpens J, von Arx G, Wiersinga WM, Mourits MP. Proposal of success criteria for strabismus surgery in patients with Graves' orbitopathy based on a systematic literature review. *Acta Ophthalmol* 2015;93:601-9.
83. Bartalena L, Marcocci C, Bogazzi F, et al. Relation between therapy for hyperthyroidism and the course of Graves' ophthalmopathy. *N Engl J Med* 1998;338:73-8.
84. Mitchell AL, Gan EH, Morris M, et al. The effect of B cell depletion therapy on anti-TSH receptor antibodies and clinical outcome in glucocorticoid-refractory Graves' orbitopathy. *Clin Endocrinol (Oxf)* 2013;79:437-42.

Copyright © 2016 Massachusetts Medical Society.

#### IMAGES IN CLINICAL MEDICINE

The *Journal* welcomes consideration of new submissions for Images in Clinical Medicine. Instructions for authors and procedures for submissions can be found on the *Journal's* website at NEJM.org. At the discretion of the editor, images that are accepted for publication may appear in the print version of the *Journal*, the electronic version, or both.